This is a digital copy of a book that was preserved for generations on library shelves before it was carefully scanned by Google as part of a project to make the world's books discoverable online.

It has survived long enough for the copyright to expire and the book to enter the public domain. A public domain book is one that was never subject to copyright or whose legal copyright term has expired. Whether a book is in the public domain may vary country to country. Public domain books are our gateways to the past, representing a wealth of history, culture and knowledge that's often difficult to discover.

Marks, notations and other marginalia present in the original volume will appear in this file - a reminder of this book's long journey from the publisher to a library and finally to you.

Usage guidelines

Google is proud to partner with libraries to digitize public domain materials and make them widely accessible. Public domain books belong to the public and we are merely their custodians. Nevertheless, this work is expensive, so in order to keep providing this resource, we have taken steps to prevent abuse by commercial parties, including placing technical restrictions on automated querying.

We also ask that you:

+ *Make non-commercial use of the files* We designed Google Book Search for use by individuals, and we request that you use these files for personal, non-commercial purposes.
+ *Refrain from automated querying* Do not send automated queries of any sort to Google's system: If you are conducting research on machine translation, optical character recognition or other areas where access to a large amount of text is helpful, please contact us. We encourage the use of public domain materials for these purposes and may be able to help.
+ *Maintain attribution* The Google "watermark" you see on each file is essential for informing people about this project and helping them find additional materials through Google Book Search. Please do not remove it.
+ *Keep it legal* Whatever your use, remember that you are responsible for ensuring that what you are doing is legal. Do not assume that just because we believe a book is in the public domain for users in the United States, that the work is also in the public domain for users in other countries. Whether a book is still in copyright varies from country to country, and we can't offer guidance on whether any specific use of any specific book is allowed. Please do not assume that a book's appearance in Google Book Search means it can be used in any manner anywhere in the world. Copyright infringement liability can be quite severe.

About Google Book Search

Google's mission is to organize the world's information and to make it universally accessible and useful. Google Book Search helps readers discover the world's books while helping authors and publishers reach new audiences. You can search through the full text of this book on the web at `http://books.google.com/`

PROPERTY OF THE
TRUSTEES OF THE PUBLIC LIBRARY OF THE
CITY OF BOSTON,
DEPOSITED IN THE
MEDICAL LIBRARY.

THE FRANCIS A. COUNTWAY LIBRARY OF MEDICINE
HARVARD MEDICAL LIBRARY-BOSTON MEDICAL LIBRARY

4/9

TRANSACTIONS

OF THE

PATHOLOGICAL SOCIETY OF LONDON.

VOLUME THE FORTY-NINTH.

BOSTON, MA

NOV 04 2003

COMPRISING THE REPORT OF THE PROCEEDINGS FOR THE SESSION 1897-98.

LONDON:
SMITH, ELDER & CO., 15, WATERLOO PLACE.
1898.

Mar. 14, 1899.

1.v. cont.
*1786.3
Vol. 49

THE present publication, being the Forty-ninth Volume of Transactions, constitutes the Fifty-second published Annual Report of the Pathological Society's Proceedings.

The COUNCIL think it right to repeat that the exhibitors are alone responsible for the descriptions given of the Specimens exhibited by them, the only change made in the Reports furnished by the authors being such verbal alterations as were absolutely necessary.

20, HANOVER SQUARE, W.;
September, 1898.

PUBLIC LIBRARY
OF THE
CITY OF BOSTON

TABLE OF CONTENTS

OF VOLUME XLIX.

	PAGE
List of Presidents of the Society	IV
List of Officers and Members for 1898–99	V
Annual Report of the Council for 1897–98	XXIX
List of Specimens Exhibited during the Session 1897–98	XXXIII
List of Specimens Reported on by the Committee on Morbid Growths	XLIV
List of Plates	XLV
List of Figures in the Text	XLVII
Address by the President	XLIX
Copy of a Summons to the Preliminary Meeting of the Pathological Society	LXIII
Diseases of the Nervous System	1
Diseases, etc., of the Organs of Respiration	13
Diseases, etc., of the Organs of Circulation	31
Diseases, etc., of the Organs of Digestion	60
Diseases, etc., of the Genito-urinary Organs	152
Diseases, etc., of the Organs of Locomotion	192
Diseases, etc., of the Ductless Glands	204
Diseases, etc., of the Skin	290
Morbid Growths	297
Bacteriology	313
Miscellaneous Communications	352
Diseases, etc., of the Lower Animals	386
Index	405

Presidents of the Society.

ELECTED

1846 CHARLES J. B. WILLIAMS, M.D., F.R.S.
1848 CHARLES ASTON KEY.
1850 PETER MERE LATHAM, M.D.
1852 CÆSAR H. HAWKINS, F.R.S.
1853 BENJAMIN GUY BABINGTON, M.D., F.R.S.
1855 JAMES MONCRIEFF ARNOTT, F.R.S.
1857 SIR THOMAS WATSON, BART., M.D., F.R.S.
1859 SIR WILLIAM FERGUSSON, BART., F.R.S.
1861 JAMES COPLAND, M.D., F.R.S.
1863 SIR PRESCOTT G. HEWETT, BART., F.R.S.
1865 THOMAS BEVILL PEACOCK, M.D.
1867 SIR JOHN SIMON, K.C.B., D.C.L., F.R.S.
1869 SIR RICHARD QUAIN, BART., M.D., LL.D., F.R.S.
1871 JOHN HILTON, F.R.S.
1873 SIR WILLIAM JENNER, BART., M.D., G.C.B., D.C.L., F.R.S.
1875 GEORGE D. POLLOCK.
1877 CHARLES MURCHISON, M.D.. LL.D., F.R.S.
1879 JONATHAN HUTCHINSON, F.R.S.
1881 SAMUEL WILKS, M.D., F.R.S.
1883 JOHN WHITAKER HULKE, F.R.S.
1885 JOHN SYER BRISTOWE, M.D., F.R.S.
1887 SIR JAMES PAGET, BART.. D.C.L., LL.D., F.R.S.
1889 WILLIAM HOWSHIP DICKINSON, M.D.
1891 SIR GEORGE MURRAY HUMPHRY, M.D., LL.D., F.R.S.
1893 FREDERICK WILLIAM PAVY, M.D., LL.D., F.R.S.
1895 HENRY TRENTHAM BUTLIN, D.C.L.
1897 JOSEPH FRANK PAYNE, M.D.

OFFICERS AND COUNCIL

OF THE

Pathological Society of London,

ELECTED AT

THE GENERAL MEETING, MAY 17th, 1898,

FOR THE SESSION 1898-99.

President.

JOSEPH FRANK PAYNE, M.D.

Vice-Presidents.

RADCLIFFE CROCKER, M.D.
FREDERICK TAYLOR, M.D.
F. CHARLEWOOD TURNER, M.D.
GERMAN SIMS WOODHEAD, M.D.
ANTHONY A. BOWLBY.
STANLEY BOYD, B.S.
A. PEARCE GOULD, M.S.
ROBERT WILLIAM PARKER.

Treasurer.

SIDNEY COUPLAND, M.D.

Council.

JOHN ABERCROMBIE, M.D.
J. ROSE BRADFORD, M.D., F.R.S.
JULIUS DRESCHFELD, M.D.
ARCHIBALD E. GARROD, M.D.
HERBERT P. HAWKINS, M.D.
R. G. HEBB, M.D.
WILLIAM HUNTER, M.D.
H. MONTAGUE MURRAY, M.D.
G. NEWTON PITT, M.D.
J. W. WASHBOURN, M.D.
WILLIAM H. BATTLE.
CECIL F. BEADLES.
RAYMOND JOHNSON, M.B.
H. A. LEDIARD, M.D.
JOHN R. LUNN.
H. BETHAM ROBINSON, M.S.
W. G. SPENCER, M.S.
J. H. TARGETT, M.S.
FREDERICK C. WALLIS.
EDGAR W. WILLETT, M.B.

Honorary Secretaries.

D'ARCY POWER, M.A., M.B. | HUMPHRY D. ROLLESTON, M.A., M.D.

Trustees.

SIR SAMUEL WILKS, BART., M.D., F.R.S.
JOSEPH FRANK PAYNE, M.D.
HENRY MORRIS, M.A.

Members of the Morbid Growths Committee.

RICHARD G. HEBB, M.D.
A. A. KANTHACK, M.D.
NORMAN MOORE, M.D.
HUMPHRY D. ROLLESTON, M.D.
HOWARD HENRY TOOTH, M.D.
ANTHONY A. BOWLBY.
D'ARCY POWER, M.B.
SAMUEL G. SHATTOCK.
W. G. SPENCER, M.S.
JAMES HENRY TARGETT, M.S.

*** *Members are requested to inform the Senior Secretary of any corrections which may be necessary.*

LIST OF MEMBERS OF THE SOCIETY.

Honorary Members.

BOUCHARD, C., M.D., Professor of General Pathology, Paris.
CHAUVEAU, A., M.D., Professor of Physiology at the Medical School of Lyons.
JENNER, SIR WILLIAM, Bart., M.D., G.C.B., D.C.L., LL.D., F.R.S., Greenwood, Bishop's Waltham, Hants.
KOCH, R., M.D., Director of Institute for Infective Diseases, Berlin.
METCHNIKOFF, E., M.D., Directeur de l'Institut Pasteur, Paris.
RINDFLEISCH, EDOUARD, M.D., Professor of Pathological Anatomy in the University of Bonn.
SIMON, SIR JOHN, K.C.B., D.C.L., LL.D., F.R.S., 40, Kensington-square, W.
VIRCHOW, RUDOLF, M.D., Professor of Pathological Anatomy in the University of Berlin.
WELCH, W. H., M.D., Professor of Pathology, Johns Hopkins University.
ZIEGLER, E., M.D. Professor of Pathological Anatomy, Freiburg.

EXPLANATION OF ABBREVIATIONS.

O.M.—Original Member.
Pres.—President.
T.—Treasurer.
V.-P.—Vice-President.
S.—Secretary.
C.—Member of Council.

The surnames of Members who have compounded for their subscriptions are printed in this type (TYPE). The surnames of Members who have paid the Composition Fee for the 'Transactions' are printed in this type (**Type**).

GENERAL LIST OF MEMBERS.

Elected

1891 ABBOTT, FRANCIS CHARLES, M.S., 44, Welbeck-street, W.
1879 **ABERCROMBIE**, JOHN, M.D., 23, Upper Wimpole-street, W. (C. 1897—.)
1885 ABRAHAM, PHINEAS S., M.A., M.D., 2, Henrietta Street, W.
1896 ABRAHAMS, BERTRAM LOUIS, B.Sc., M.B., 14, Welbeck-street, W.
1858 ACLAND, Sir HENRY WENTWORTH, Bart., K.C.B., M.D., F.R.S., Broad-street, Oxford.
1883 ACLAND, THEODORE DYKE, M.D., 74, Brook-street, W. (C. 1892-4.)
1891 ADAMI, J. GEORGE, M.A., M.D., Montreal, Canada.
1890 ADAMS, JAMES, 4, Chiswick-place, Eastbourne.
O.M. **ADAMS**, WILLIAM, 7, Loudoun-road, St. John's Wood, N.W. (C. 1851-4. V.-P. 1867-9.)
1848 **AIKIN**, CHARLES A., 12, Ladbroke-terrace, W. (C. 1864-6.)
1872 AIKIN, CHARLES EDMUND, 12, Ladbroke-terrace, W.
1897 ALCOCKS, S. K., Portland House, Burslem.
1882 **ALLCHIN**, WILLIAM HENRY, M.D., 5, Chandos-street, W.
1884 ANDERSON, ALEXANDER RICHARD, 5, East Circus-street, Nottingham.
1871 ANDERSON, WILLIAM, 2, Harley-street, W. (C. 1888-90.)
1897 ANDREWES, F. N., M.D., Highwood, Hampstead-lane, Highgate, N.
1887 ARKLE, CHARLES, M.D., 66, Wimpole-street, W.
1883 ASHBY, HENRY, M.D., 13, St. John-street, Manchester.

1863 BAGSHAWE, FREDERICK, M.A., M.D., 35, Warrior-square, St. Leonard's-on-Sea.
1856 **Balding**, DANIEL BARLEY, Royston, Herts.
1881 BALLANCE, CHARLES A., M.S., 106, Harley-street, W. (C. 1890-2.)
1875 BARKER, ARTHUR E. J., 87, Harley-street, W. (C. 1884-6. V.P. 1896-7.)
1885 BARLING, GILBERT, M.B., 85, Edmund-street, Birmingham. (C. 1894-7.)
1874 **BARLOW**, THOMAS, M.D., B.S., 10, Wimpole-street, W. (C. 1879-81. V.-P. 1894-6.)
1877 BARROW, A. BOYCE, 37, Wimpole-street, W.
1881 BARRS, ALFRED GEORGE, M.D., 22, Park-place, Leeds.
1853 **BARWELL**, RICHARD, 55, Wimpole-street, W. (C. 1862-4. V.-P. 1889-90.)
1861 **BASTIAN**, H. CHARLTON, M.A., M.D., F.R.S., 8A, Manchester-square, W. (C. 1869-71. V.-P. 1885-7.)
1877 BATEMAN, ARTHUR W., B.A., Tenterfield, New South Wales.
1895 BATTEN, FREDERICK E., M.D., 124, Harley-street, W.
1876 **BATTESON**, JOHN, Carnforth, Chiswick-lane, W.

Elected

1882 BATTLE, WILLIAM HENRY, 2, Mansfield-street, W. (C. 1898—.)

1870 BÄUMLER, CHRISTIAN G. H., M.D., University of Erlangen.

1874 BEACH, FLETCHER, M.B., 64, Welbeck-street, W., and Winchester House, Kingston Hill, Surrey.

1892 BEADLES, CECIL F., Colney Hatch Lunatic Asylum, N. (C. 1898—.)

1879 BEALE, EDWIN CLIFFORD, M.B., 23, Upper Berkeley-street, W.

1852 BEALE, LIONEL S., M.B., F.R.S., 61, Grosvenor-street, W. (C. 1858-9. V.-P. 1874-5.)

1856 BEALEY, ADAM, M.D., M.A., Felsham Lodge, Hollington-park, St. Leonard's-on-Sea.

1897 BEDDARD, A. P., 44, Seymour-street, W.

1865 BEEBY, WALTER, M.D., Bromley, Kent.

1880 BEEVOR, CHARLES EDWARD, M.D., 33, Harley-street, W. (C. 1888-90.)

1886 BENNETT, FREDERICK JOSEPH, 24, George-street, Hanover-square, W.

1877 BENNETT, WILLIAM HENRY, 1, Chesterfield-street, W. (C. 1891-3.)

1889 BENTLEY, ARTHUR, J. M., M.D., Mena House, Pyramids, Cairo, Egypt.

1878 BERNARD, FRANCIS R., M.D., Prawls, Stone, near Tenterden, Kent.

1882 BERRIDGE, WILLIAM ALFRED, Redhill, Surrey.

1886 BERRY, JAMES, 60, Welbeck-street, W. (C. 1895-7.)

1891 BEVILLE, FREDERICK WELLS, The Firs, Palace-road, East Molesey.

1856 Bickersteth, EDWARD R., 2, Rodney-street, Liverpool.

1882 BINDLEY, PHILIP HENRY, M.B., Branksome-road, St. Leonard's-on-Sea.

1850 BIRKETT, EDMUND LLOYD, M.D., Westbourne Rectory, Emsworth, Hampshire. (C. 1856-7.)

1881 BISS, CECIL YATES, M.D., 135, Harley-street, W.

1865 BISSHOPP, JAMES, Mount Pleasant, Tunbridge Wells.

1889 BLACK, ROBERT, M.D., 6, Pavilion Parade, Brighton.

1850 BLAGDEN, ROBERT, 15, Oxberry-avenue, Fulham.

1863 BLANCHET, JEAN B., M.D., M.S., Montreal, Quebec, Canada.

1879 BOILEAU, J. P. H., M.D., Brigade-Surgeon, Army.

1876 BOND, THOMAS, M.B., 7, Broad Sanctuary, Westminster, S.W.

1869 BOURNE, WALTER, M.D. (Travelling).

1861 BOWER, RICHARD NORRIS (Travelling).

1881 BOWLBY, ANTHONY A., 24, Manchester-square, W. (C. 1886-8, 1895-7. S. 1893-4. V.-P. 1898—.)

1895 BOX, CHARLES R., M.D., St. Thomas's Hospital, S.E.

1892 BOYCE, RUBERT WILLIAM, M.B., University College, Liverpool.

1882 BOYD, STANLEY, M.B., 134, Harley-street, W. (C. 1893-6. V.-P. 1897—.)

1889 BRADFORD, JOHN ROSE, M.D., F.R.S., 60, Wimpole-street, W. (C. 1897—.)

1880 BRAMWELL, BYROM, M.D., 23, Drumsheugh-gardens West, Edinburgh.

1889 BREDIN, J. NOBLE, Linden Lodge, Potton, Beds.

1877 BRIDGES, ROBERT, M.B., M.A., Manor House, Yattendon, Berks.

1867 Bridgewater, THOMAS, LL.D. Glas., M.B. Lond., Harrow-on-the-Hill, Middlesex.

Elected

1873 BRIGGS, JACOB MYERS, M.D., Coeymans, New York, U.S.A.

1868 BRIGHT, GEORGE CHARLES, M.D., Cannes, Alpes Maritimes, France.

1857 BRISCOE, JOHN, 5, Broad-street, Oxford.

1885 BRISCOE, JOHN F., Westbrooke House, Alton, Hants.

1860 **BROADBENT**, Sir WILLIAM HENRY, Bart., M.D., 84, Brook-street, W. (C. 1871-3. V.P. 1882-4.)

1886 BROCKATT, ANDREW ALEXANDER, Hazeldean, Malvern.

1852 **BRODHURST**, BERNARD E., 21, Portland-place, W. (C. 1862-4.)

1884 BRODIE, CHARLES GORDON, Fernhill, Wootton Bridge, Isle of Wight.

1865 **BROWN**, AUGUSTUS, M.D., Felsberg, Wilton Road, Shanklin, I.W.

1871 BROWN, FREDERICK GORDON, 17, Finsbury-circus, E.C.

1866 **BROWNE**, LENNOX, 15, Mansfield-street, W.

1877 BRUCE, J. MITCHELL, M.D., 23, Harley-street, W.

1890 BRUNTON, T. LAUDER, M.D., D.Sc., LL.D., F.R.S., 10, Stratford-place, W.

1855 **BRYANT**, THOMAS, M.Ch., 65, Grosvenor-street, W. (C. 1863-6. V.-P. 1877-9.)

1894 BUCHANAN, GEORGE SEATON, M.D., 9, Hammersmith-terrace, W.

1890 BUCKLAND, FRANCIS O., M.A., M.B., C.M., 6, Lower Sloane-street, S.W.

1891 BURGHARD, FREDERIC FRANÇOIS, M.D., M.S., 86, Harley-street, W.

1880 BURTON, SAMUEL HERBERT, M.B., Norfolk and Norwich Hospital, Norwich.

1887 BUTLER-SMYTHE, ALBERT CHARLES, 76, Brook-street, W.

1872 **BUTLIN**, HENRY TRENTHAM, D.C.L., 82, Harley-street, W. (C. 1876-8, 1887-9. S. 1884-6. V.-P. 1891-2. P. 1895-7.)

1883 **BUXTON**, DUDLEY W., M.D., 82, Mortimer-street, W.

1856 **BUZZARD**, THOMAS, M.D., 74, Grosvenor-street, W. (C. 1869-70. V.-P. 1881-3.)

1893 CADDY, DUNCAN JAMES, M.D., 4, Earl's Court-gardens, S.W. (Travelling.)

1885 CAHILL, JOHN, 12, Seville-street, Lowndes-square, S.W.

1893 CALEY, HENRY ALBERT, M.D., 24, Upper Berkeley-street, W.

1897 CALVERT, JAMES, M.D., The Warden's House, St. Bartholomew's Hospital, E.C.

1892 CAMPBELL, HENRY JOHNSTONE, M.D., 36, Manningham-lane, Bradford.

1891 CARLESS, ALBERT, M.S., 10, Welbeck-street, W.

1891 CARR, JOHN WALTER, M.D., 19, Cavendish-place, W.

1876 CARTER, ROBERT BRUDENELL, 31, Harley-street, W., and Kenilworth, Clapham-common, S.W.

1897 CARWARDINE, T., 7, Buckingham-place, Clifton, Bristol.

1877 CASSON, JOHN HORNSEY, H.B.M. Legation, Teheran, Persia.

1868 **CAVAFY**, JOHN, M.D., 2, Upper Berkeley-street, W. (C. 1881-3.)

1864 CAY, CHARLES VIDLER, Deputy Surgeon-General, 25, Newton-place, Glasgow.

1863 CAYLEY, WILLIAM, M.D., 27, Wimpole-street, W. (C. 1870-1, 1875-8. S. 1872-4. V.-P. 1884-6. T. 1888-93.)

Elected

1869 CHAFFERS, EDWARD, Keighley, Yorkshire.

1884 CHAFFEY, WAYLAND CHARLES, M.D., 13, Montpellier-road, Brighton.

1891 CHAPLIN, ARNOLD, M.D., 24, Finsbury-circus, E.C.

1884 CHAVASSE, THOMAS FREDERICK, M.D., C.M., 22, Temple-row, Birmingham.

1879 CHEYNE, WILLIAM WATSON, M.B., C.M., F.R.S., 75, Harley-street, W. (C. 1885-7. V.-P. 1892-3.)

1858 CHILD, GILBERT W., Cowley House, Oxford.

1873 CHISHOLM, EDWIN, M.D., Abergeldie, Ashfield, near Sydney, New South Wales [care of Messrs. Dawson, 121, Cannon-street, E.C.].

1865 CHURCH, WILLIAM SELBY, M.D., 130, Harley-street, W. (C. 1871-3. V.-P. 1894-6.)

1868 CHURCHILL, FREDERICK, M.D., 4, Cranley-gardens, Queen's-gate, S.W.

1861 CLAPTON, EDWARD, M.D., 22, St. Thomas's-street, Southwark, S.E.

1872 CLARK, ANDREW, 71, Harley-street, W.

1886 CLARK, FRANCIS WILLIAM, Hong Kong.

1891 CLARKE, J. JACKSON, M.B., 9, Old Cavendish-street, W.

1885 CLARKE, JOHN MICHELL, M.D., 28, Pembroke-road, Clifton, Bristol.

1881 CLARKE, W. BRUCE, M.B., 51, Harley-street, W. (C. 1892-4.)

1875 CLUTTON, HENRY HUGH, M.A., 2, Portland-place, W. (C. 1884-6. V.-P. 1892-3.)

1865 Coates, CHARLES, M.D., 10, Circus, Bath.

1885 COATS, JOSEPH, M.D., 31, Lynedoch-street, Glasgow.

1856 COCKLE, JOHN, M.D., M.A., The Lodge, West Molesey.

1892 COLE, ROBERT HENRY, M.D., Moorcroft, Hillingdon, Uxbridge.

1886 COLLIER, WILLIAM, M.D., 62, High-street, Oxford.

1891 COLLINS, EDWARD TREACHER, 84, Wimpole-street, W.

1888 COLLINS, WILLIAM JOB, M.D., M.S., 1, Albert-terrace, Regent's-park, N.W.

1878 COLLYNS, R. T. POOLE, 20, Lingfield-road, Wimbledon.

1888 COLMAN, WALTER STACY, M.D., 22, Wimpole-street, W.

1882 COLQUHOUN, DANIEL, M.D., Dunedin, New Zealand.

1896 CONNELL, W. T., M.D., Kingston, Canada.

1891 COOK, HERBERT G. GRAHAM, M.D., University College, Cardiff.

1858 COOKE, R. T. E. BARRINGTON, 15, St. Nicholas-cliff, Scarborough, Yorkshire.

1871 COOKE, THOMAS, 40, Brunswick-square, W.C.

1866 COOMBS, ROWLAND HILL, Mill-street, Bedford.

1892 COOPER, C. DUDLEY, London County Lunatic Asylum, Claybury, Woodford, Essex.

1876 COTTLE, WYNDHAM, M.D., 39, Hertford-street, W.

1861 COUPER, JOHN, 80, Grosvenor-street, W. (C. 1870-2.)

1873 COUPLAND, SIDNEY, M.D. (TREASURER), 16, Queen Anne-street, W. (C. 1878-81, 1889-91. S. 1886-8. V.-P. 1892-3. T. 1894—.)

Elected

1897 CRAWFURD, R. H. P., M.D., 71, Harley-street, W.

1884 CRICHTON, GEORGE, M.D., 3, Cambridge-villas, Twickenham.

1873 CRIPPS, WILLIAM HARRISON, 2, Stratford-place, W. (C. 1883-5. V.-P. 1893-4.)

1877 **CROCKER**, HENRY RADCLIFFE, M.D., 121, Harley-street, W. (C. 1887-9. V.-P. 1897—.)

1856 CROFT, JOHN, 6, Mansfield-street, W. (C. 1870-2. V.-P. 1882-4.)

1879 CROOKE, GEORGE FREDERICK, M.D., 2, Edmund-street, Birmingham.

1886 CROOKSHANK, EDGAR, M.B., Saint Hill, near East Grinstead, Sussex. (C. 1890-3.)

1875 CROSS, FRANCIS RICHARDSON, 5, The Mall, Clifton, Bristol.

1890 CROWLE, THOMAS H. RICKARD, 56, Harley-street, Cavendish-square, W.

1889 CUFF, ROBERT, M.B., 1, The Crescent, Scarborough.

1885 CULLINGWORTH, CHARLES JAMES, M.D., 14, Manchester-square, W.

1871 CUMBERBATCH, A. ELKIN, 80, Portland-place, W.

1873 CURNOW, JOHN, M.D., 9, Wimpole-street, Cavendish-square, W. (C. 1882-4.)

1893 CURTIS, HENRY JONES, M.D., 60, Gower-street, W.C.

1884 DAKIN, W. RADFORD, M.D., B.S., 18, Grosvenor-street, Grosvenor-square, W.

1883 DALTON, NORMAN, M.D., 4, Mansfield-street, W.

1873 DAVIDSON, ALEXANDER, M.D., 2, Gambier-terrace, Liverpool.

1869 **DAVIES-COLLEY**, J. NEVILLE C., M.C., 36, Harley-street, W. (C. 1880-2. V.-P. 1890-1.)

1883 DAVIS, EDWIN HARRY, West Hartlepool.

1859 **Davis**, FRANCIS WILLIAM, R.N.

1879 DAVY, HENRY, M.D., 29, Southernhay, Exeter.

1894 DAWSON, BERTRAND, M.D., 46, Finsbury-pavement, E.C.

1889 DEAN, HENRY PERCY, M.B., M.S., 69, Harley-street, W.

1887 DELÉPINE, SHERIDAN, M.B., C.M., 258, Oxford-road, Manchester.

1880 DENT, CLINTON T., 61, Brook-street, W.

1871 DICKINSON, EDWARD HARRIMAN, M.A., M.D., 162, Bedford-street, Liverpool.

1858 **DICKINSON**, WILLIAM HOWSHIP, M.D., 9, Chesterfield-street, W. (C. 1866-8. S. 1869-71. V.-P. 1872-4. P. 1889-90.)

1890 **DICKINSON**, WILLIAM LEE, M.D., 9, Chesterfield-street, W.

1872 DIVER, EBENEZER, M.D., 30, Devonshire-street, W.

1872 DORAN, ALBAN HENRY GRIFFITHS, 9, Granville-place, W. (C. 1882-4. V.-P. 1894-6.)

1866 DOUGLAS-POWELL, Sir RICHARD, Bart., M.D., 62, Wimpole-street, W. (C. 1873-5, 1881-3. S. 1877-9. V.-P. 1887-8.)

1893 DOWSON, WALTER, M.D., 46, Alleyn-road, West Dulwich.

1877 DRAKE-BROCKMAN, E. F., Madras Medical Service [care of Mr. Lewis, Gower-street, W.C.].

1880 DRESCHFELD, JULIUS, M.D., 325, Oxford-road, Manchester. (C. 1896—.)

Elected

1896 DREW, DOUGLAS, 58, Brook-street, W.

1879 DREWITT, F. G. DAWTREY, M.D., 2, Manchester-square, W. (C. 1890-2.)

1893 DRYSDALE, JOHN HANNAH, M.B., 25, Welbeck-street, W.

1865 DUCKWORTH, Sir DYCE, M.D., LL.D., 11, Grafton-street, Bond-street, W. (C. 1877.)

1847 DUDGEON, ROBERT E., M.D., 53, Montagu-square, W.

1871 DUKES, CLEMENT, M.D., B.S., Sunnyside, Rugby.

1877 DUNBAR, J. J. MACWHIRTER, M.D., Hedingham House, Clapham-common, S.W.

1877 DUNCAN, ANDREW, M.D., 8, Henrietta-street, Covent-garden, W.C.

1889 DUNCAN, JOHN, M.D., St. Petersburg.

1884 DUNN, LOUIS ALBERT, M.B., M.S., The College, Guy's Hospital, S.E.

1879 DURHAM, FREDERIC, M.B., 82, Brook-street, W.

1893 ECCLES, WILLIAM MCADAM, 124, Harley-street, W.

1892 EDDOWES, ALFRED, M.D., 25, Old Burlington-street, W.

1880 EDMUNDS, WALTER, M.C., 75, Lambeth Palace-road, S.E. (C. 1892-4.)

1882 EDWARDS, F. SWINFORD, 55, Harley-street, W.

1889 ELAM, WILLIAM HENRY, New Barnet, Herts.

1883 ELDER, GEORGE, M.D., 17, Regent-street, Nottingham.

1867 ELLIS, JAMES, M.D., Coburg-street, Fratton, Portsmouth, and California.

1873 ENGELMANN, GEORGE JULIUS, M.D., A.M., 336, Beacon-street, Boston, Mass., U.S.A.

1875 EVANS, JULIAN AUGUSTUS, A.M., M.D., 123, Finborough-road, Redcliffe-square, S.W.

1894 EVANS, WILLMOTT H., 13, Taviton-street, Gordon-square, W.C.

1879 EVE, FREDERIC S., 125, Harley-street, W. (C. 1885-7. V.-P. 1895-7.)

1876 EWART, JAMES COSSAR, M.B., C.M., F.R.S., School of Medicine, Edinburgh.

1881 EWART, Sir JOSEPH, M.D., Montpellier Terrace, Brighton.

1877 EWART, WILLIAM, M.D., 33, Curzon-street, W. (C. 1889-91.)

1859 Ewens, JOHN, 17, Redland Grove, Bristol.

1887 EYLES, CHARLES HENRY, Gold Coast Colony.

1897 EYRE, J. W. H., M.D., 16, Trinity-square, S.E.

1889 FAIRBANK, FREDERICK ROYSTON, M.D., Hillside, Westcott, Dorking.

1894 FAWCETT, JOHN, M.D., 24, St. Thomas's-street, S.E.

1872 FAYRER, Sir JOSEPH, K.C.S.I., M.D., LL.D., F.R.S., 16, Devonshire-street, W. (C. 1880-2. V.-P. 1890-1.)

1872 FENN, EDWARD L., M.D., Grey Friars, Colchester.

1883 FENWICK, E. HURRY, 14, Savile-row, W. (C. 1894-7.)

1872 FENWICK, JOHN C. J., M.D., 25, North-road, Durham.

1863 FENWICK, SAMUEL, M.D., 29, Harley-street, W.

1892 FENWICK, W. SOLTAU, M.D., 10, Devonshire-street, W.

Elected

1885 **Féré**, Charles, M.D., Médecin de Bicêtre; Boulevard St. Michel 37, Paris.

1897 Fisher, Theodore, M.D., 25, Pembroke-road, Clifton, Bristol.

1882 Fleming, George, C.B., LL.D., Higher Leigh, Combe Martin, North Devon.

1893 Fletcher, H. Morley, M.A., M.D., B.C., 98, Harley-street, W.

1872 Forbes, Daniel Mackay, Shoreditch Infirmary, 204, Hoxton-street, N.

1866 **Foster**, Sir Balthazar Walter, M.D., M.P., 30, Grosvenor-road, Westminster.

1872 Fotherby, Henry I., M.D., Woodthorpe Cote, Reigate.

1891 Foulerton, Alexander Grant Russell, Dunsdale, Mulgrave Road, Sutton.

1880 Fowler, James Kingston, M.A., M.D., 35, Clarges-street, W. (C. 1887-8.)

1878 Fox, Thomas Colcott, M.B., B.A., 14, Harley-street, W. (C. 1892-4.)

1858 Francis, Charles Richard, M.B., Bengal Medical Establishment, Indian Army.

1896 Freyberger, Ludwig, M.D., 41, Regent's-park-road, N.W.

1891 Fripp, Alfred Downing, M.S., 19, Portland-place, W.

1864 Frodsham, John Mill, M.D., Streatham, S.W.

1894 Furnivall, Percy, 39, Welbeck-street, W.

1893 Fyffe, William Kington, M.B., 1, Boullcott-street, Wellington, New Zealand.

1880 Gabbett, Henry Singer, M.D., 20, Burlington-place, Eastbourne.

1858 **Gairdner**, William Tennant, M.D., LL.D.Edin., F.R.S., 225, St. Vincent-street, Glasgow. (V.-P. 1891-2.)

1890 Galloway, James, M.A., M.D., 54, Harley-street, W.

1870 Galton, John H., M.D., Sylvan-road, Upper Norwood, S.E.

1846 **Garrod**, Sir Alfred Baring, M.D., F.R.S., 10, Harley-street, W. (C. 1851. V.-P. 1863-5.)

1892 Garrod, Archibald Edward, M.D., 9, Chandos-street, Cavendish-square, W. (C. 1898—.)

1879 Garstang, Thomas Walter Harropp, Headingley House, Knutsford, Cheshire.

1872 Garton, William, M.D., Inglewood, Aughton, near Ormskirk, Lancashire.

1891 Gaster, Aughel, M.D., 224, Belsize-road, N.W.

1880 Gibbes, Heneage, M.B., University of Michigan, Ann Arbor, Michigan, U.S.A.

1853 **Gibbon**, Septimus, M.D., 39, Oxford-terrace, Hyde-park, W.

1878 Gibbons, R. A., M.D., 29, Cadogan-place, S.W.

1893 Gibbs, Charles, Charing-cross Hospital, W.C.

1872 Gilbart-Smith, Thomas, M.D., 68, Harley-street, W.

1876 Gill, John, M.D., 31, Apsley-road, Clifton, Bristol.

1881 Glynn, Thomas Robinson, M.D., 62, Rodney-street, Liverpool.

Elected

1873 GODLEE, RICKMAN JOHN, M.B., M.S., 19, Wimpole-street, W. (C. 1877-80. 1891-2. S. 1887-9. V.-P. 1893-4.)

1878 GOLDING-BIRD, CUTHBERT H., M.B., B.S., 12, Queen Anne-street, W. (C. 1885-7. V.-P. 1894-6.)

1890 GOODALL, E. WILBERFORCE, M.D., The Eastern Hospital, Homerton, N.E.

1871 GOODHART, JAMES FREDERIC, M.D., 25, Portland-place, W. (C. 1876-8. 1886-8. S. 1883-5. V.-P. 1892-3.)

1894 GOSSAGE, ALFRED MILNE, M.B., B.Ch., 54, Upper Berkeley-street, W.

1875 GOULD, ALFRED PEARCE, M.S., 10, Queen Anne-street, W. (C. 1883-5. V.-P. 1898—.)

1870 GOWERS, Sir WILLIAM, M.D., F.R.S., 50, Queen Anne-street, W. (C. 1878-9. V.P. 1896-7.)

1888 GRANT, J. DUNDAS, M.A., M.D., C.M., 8, Upper Wimpole-street, W.

1867 GREEN, T. HENRY, M.D., 74, Wimpole-street, W. (C. 1871-3, 1878-9. S. 1875-6. V.-P. 1886-8.)

1895 GREEN, CHARLES DAVID, M.D., Addison House, Upper Edmonton.

1873 GREENFIELD, WILLIAM SMITH, M.D., B.S., 7, Heriot-row, Edinburgh. (C. 1877-80. V.-P. 1893-4.)

1886 GREVES, EDWIN HYLA, M.D., Rodney House, Suffolk-road, Bournemouth.

1897 GRIFFITH, J., 23, Cavendish-square, W.

1892 GRIFFITH, WILLIAM STOKES, M.B., B.C., 4, Bramham-gardens, S.W.

1887 GRIFFITHS, JOSEPH, M.D., C.M., 16, Panton-street, Cambridge.

1876 GRIFFITHS, THOMAS D., M.D., Hearne Lodge, Swansea.

1887 HABERSHON, SAMUEL HERBERT, M.D., 70, Brook-street, W.

1851 HACON, E. DENNIS, 269, Mare-street, Hackney, N.E. (C. 1872.)

1892 HADLEY, WILFRED JAMES, M.D., 58, Harley-street, W.

1882 HAIG, A., M.D., 7, Brook-street, W.

1894 HALLIDIE, ANDREW HALLIDIE SMITH, M.B., Johannesburg.

1877 HALLOWES, FREDERICK BLACKWOOD, Redhill, Surrey.

1886 HAMILTON, DAVID JAMES, M.B., 41, Queen's-road, Aberdeen.

1890 HANDFIELD-JONES, MONTAGU, M.D., 35, Cavendish-square, W.

1886 HANDFORD, HENRY, M.D., 14, Regent-street, Nottingham.

1891 HANKIN, E. H., St. John's College, Cambridge. [India.]

1882 HARBINSON, ALEXANDER, M.D., County Lunatic Asylum, Lancaster.

1847 HARE, CHARLES JOHN, M.D., Berkeley House, 15, Manchester-square, W. (C. 1852-4. V.-P.1874-7.)

1893 HARLEY, VAUGHAN, M.D., 25, Harley-street, W.

1872 HARRIS, HENRY, M.D., Trengweath-place, Redruth, Cornwall.

1879 HARRIS, VINCENT DORMER, M.D., 22, Queen Anne-street, W.

1891 HASLAM, WILLIAM F., 54, Newhall-street, Birmingham.

1870 HAWARD, JOHN WARRINGTON, 16, Savile-row, W. (C. 1879-81. V.-P. 1890-1.)

1886 HAWKINS, FRANCIS HENRY, M.B., 73, London-street, Reading.

Elected

1890 HAWKINS, HERBERT PENNELL, M.D., 56, Portland-place, W. (C. 1898—.)

1856 **HEATH**, CHRISTOPHER, 36, Cavendish-square, W. (C. 1866-7. V.-P. 1879-81.)

1892 HEATON, GEORGE, M.B., B.Ch., 33, Temple-row. Birmingham.

1881 HEBB, RICHARD G., M.A., M.D., 9, Suffolk-street, S.W. (C. 1891-3. S. 1896-7. C. 1898—.)

1884 HEBBERT, CHARLES ALFRED, care of C. Baylor, 7, Water-street, Boston, U.S.A.

1878 HELLIER, JOHN B., M.D., Headingley, Leeds.

1879 HENDERSON, GEORGE COURTENAY, M.D., Kingston, Jamaica, West Indies.

1869 HENSLEY, PHILIP J., M.D., 4, Henrietta-street, W.

1884 HERRINGHAM, WILMOT PARKER, M.D., 13, Upper Wimpole-street, W. (C. 1894-7.)

1892 HEWLETT, RICHARD TANNER, M.D., British Institute of Preventive Medicine, Chelsea-gardens, Grosvenor-road, S.W.

1897 HICHENS, P. S., Hospital for Consumption, Brompton, W.

1880 HOBSON, JOHN MORRISON, M.D., Glendalough, Morland-road, Croydon.

1854 **HOLMES**, TIMOTHY, 6, Sussex-place, Hyde-park, W. (C. 1862-3. S. 1864-7. C. 1868. V.-P. 1869-71.)

O.M. HOLTHOUSE, CARSTEN, Bath-terrace, Richmond. (C. 1852-4, V.-P. 1874-5.)

1878 HOOD, DONALD WILLIAM CHARLES, M.D., 43, Green-street, Park-lane, W.

1864 HOOD, WHARTON P., M.D., 11, Seymour-street, W.

1895 HOPKINS, F. G., M.B., Guy's Hospital, S.E.

1897 HORNE, W. J., 17, Bartlett's-buildings, Holborn, E.C.

1879 HORROCKS, PETER, M.D., 45, Brook-street, W.

1883 HORSLEY, VICTOR, M.B., B.S., F.R.S., 25, Cavendish-square, W. (C. 1888-9.)

1896 HORTON-SMITH, PERCIVAL, M.D., B.C., 15, Upper Brook-street, W.

1880 **HOVELL**, T. MARK, 105, Harley-street, W.

1893 HOWARD, ROBERT JAMES BLISS, M.D., 31, Queen Anne-street, W.

1875 HOWSE, HENRY GREENWAY, M.S., 59, Brook-street, W. (C. 1878-81.)

1856 **HUDSON**, JOHN, M.D., 11, Cork-street, W.

1874 HUMPHREYS, HENRY, M.D., St. Mary Church-road, Torquay.

1897 HUNT, E. L., 18, Dorset-square, W.

1897 HUNT, G. B., M.D., University College Hospital, W.C.

1888 HUNTER, WILLIAM, M.D., 103, Harley-street, W. (C. 1897—.)

1852 **HUTCHINSON**, JONATHAN, F.R.S., 15, Cavendish-square, W. (C. 1856-9. V.-P. 1872-3, 1881-3. P. 1879-80.)

1882 HUTCHINSON, JONATHAN, jun., 15, Cavendish-square, W. (C. 1889-91.)

1884 HUTTON, HENRY RICHMOND, M.B., 8A, St. John-street, Manchester.

1889 HYSLOP, THEOPHILUS BULKELEY, M.D., C.M., Bethlem Royal Hospital, S.E.

1880 INGRAM, ERNEST FORTESCUE, Newcastle, Natal, S. Africa.

Elected

1886 JACKSON, ARTHUR MOLYNEUX, M.D., Kent County Asylum, Barming Heath, Maidstone.

1865 JACKSON, J. HUGHLINGS, M.D., F.R.S., 3, Manchester-square, W. (C. 1872-3. V.-P. 1888-9.)

1886 JACKSON, PHILIP J., 216, Great Dover-street, S.E.

1875 JALLAND, WILLIAM HAMERTON, St. Leonard's House, Museum-street, York.

1897 JAMES, G. T. B., Carlisle-mansions, Victoria-street, S.W.

1888 JAMES, JAMES THOMAS, M.D., 30, Harley-street, W.

1853 **Jardine**, JOHN LEE, Capel, near Dorking, Surrey.

1897 JENNER, LOUIS, 4A, Bloomsbury-square, W.C.

1881 JENNINGS, WILLIAM OSCAR, M.D., Rue Marbœuf, Avenue des Champs-Elysées, Paris.

1879 JESSOP, CHARLES MOORE, Clare Lodge, Redhill.

1866 JESSOP, THOMAS RICHARD, 31, Park-square, Leeds.

1878 JOHNSON, ARTHUR JUKES, Yorkville, Ontario, Canada.

1876 JOHNSON, CHARLES HENRY, Winton House, Basingstoke, Hants.

1888 JOHNSON, RAYMOND, M.B., B.S., 20, Weymouth-street, Portland-place, W. (C. 1896—.)

1881 JOHNSTON, JOSEPH, M.D., 24, St. John's Wood-park, N.W.

1854 JOHNSTONE, ATHOL A. W., St. Moritz House, 61, Dyke-road, Brighton.

1853 JONES, SYDNEY, M.B., 18, Portland-place, W. (C. 1864-6. V.-P. 1886-7.)

1888 JONES, TALFOURD, M.B., Eastbourne.

1862 JONES, THOMAS RIDGE, M.D., 4, Chesham-place, S.W. (C. 1882-4.)

1886 JULER, HENRY EDWARD, 23, Cavendish-square, W.

1890 KANTHACK, A. A., M.A., M.D., Pathological Laboratory, Cambridge. (C. 1894-7.)

1867 KELLY, CHARLES, M.D., Ellesmere, Gratwicke-road, Worthing, Sussex. (C. 1874.)

1897 KELLY, C. E. M., M.D., 9, Highbury-grove, N.

1879 KESTEVEN, WILLIAM HENRY, Hillwood, Waverley-grove, Hendon, N.W.

1859 KIALLMARK, HENRY WALTER, 5, Pembridge-gardens, W. (C. 1875-6.)

1882 KIDD, PERCY, M.D., 60, Brook-street, W. (C. 1889-91.)

1867 KING, EDWIN HOLBOROW, Netley Court, Southampton.

1871 KING, ROBERT, M.B., Boyfield House, Moulton, Spalding, Lincolnshire.

1852 KINGDON, J. ABERNETHY, Threadneedle-street, E.C.

1888 KYNSEY, Sir WILLIAM RAYMOND, K.C.M.G., Oriental Club, Hanover-square, W.

1878 LANCEREAUX, ETIENNE, M.D., 44, Rue de la Bienfaisance, Paris.

1882 LANE, WILLIAM ARBUTHNOT, M.B., M.S., 21, Cavendish-square, W. (C. 1891-3.)

Elected

1865 LANGTON, JOHN, 62, Harley-street, W. (C. 1882-4.)

1869 LARCHER, O., M.D.Par., 97, Rue de Passy, Paris. [M. Kliensieck, Libraire, Rue de Lille 11, Paris, per Messrs. Longmans.]

1884 LARDER, HERBERT, Whitechapel Infirmary, Baker's-row, N.E.

1897 LATHAM, A. C., 13, Bruton-street, W.

1873 LATHAM, PETER WALLWORK, M.D., 17, Trumpington-street, Cambridge.

1876 LAW, WILLIAM THOMAS, M.D., 5, Duchess-street, Portland-place, W.

1853 LAWRENCE, HENRY JOHN HUGHES, Picton House, Llandowror, St. Clears. (C. 1873-5.)

1892 LAWRENCE, THOMAS WILLIAM PELHAM, M.B., 46, Maida-vale, W.

1893 LAWSON, ARNOLD, M.D., 12, Harley-street, W.

1859 LAWSON, GEORGE, 12, Harley-street, W. (C. 1870-1. V.-P. 1884-5.)

1879 LAYCOCK, GEORGE LOCKWOOD, M.B., Melbourne, Victoria, Australia.

1891 LAZARUS-BARLOW, WALTER SYDNEY, M.D.

1875 LEDIARD, HENRY AMBROSE, M.D., 35, Lowther-street, Carlisle. (C. 1897—.)

1879 LEECH, DANIEL JOHN, M.D., 96, Mosley-street, Manchester.

1877 LEES, DAVID B., M.D., 22, Weymouth-street, W. (C. 1890-2.)

1867 LEES, JOSEPH, M.D., 21, Brixton-road, S.W.

1877 LEESON, JOHN RUDD, M.D., C.M., 6, Clifden-road, Twickenham.

1868 LEGG, JOHN WICKHAM, M.D. (Travelling.) (C. 1874-5.)

1892 LEITH, ROBERT FRASER CALDIE, M.B., C.M., B.Sc., 20, Merchiston terrace, Edinburgh.

1892 Leudet, ROBERT, 16, Rue du Contrat-Social, Rouen, France.

1861 LICHTENBERG, GEORGE, M.D., 47, Finsbury-square, E.C.

1877 LISTER, Lord, D.C.L., LL.D., F.R.S., 12, Park-crescent, W. (C. 1880-2. V.-P. 1887-8, 1891-2.)

1897 LISTER, THOMAS DAVID, 95, Wimpole-street, W.

1895 LITTLE, ERNEST GRAHAM GORDON, M.D., 61, Wimpole-street, W.

1889 LITTLE, JOHN FLETCHER, M.B., 32, Harley-street, W.

1862 LITTLE, LOUIS S., Shanghai, China.

1896 LITTLEWOOD, HARRY, 40, Park-square, Leeds.

1874 LIVEING, EDWARD, M.D., 52, Queen Anne-street, W.

1863 LIVEING, ROBERT, M.D., 11, Manchester-square, W. (C. 1876.)

1882 LOCKWOOD, C. B., 19, Upper Berkeley-street, W. (C. 1893-6.)

1881 LUBBOCK, MONTAGU, M.D., 19, Grosvenor-street, W.

1897 LUCAS, ALBERT, 9, Easy-row, Birmingham.

1873 LUCAS, R. CLEMENT, M.B., B.S., 50, Wimpole-street, W. (C. 1883-5.)

1879 LUNN, JOHN REUBEN, St. Marylebone Infirmary; Rackham-street, Ladbroke-grove-road, W. (C. 1897—.)

1887 LYON, THOMAS GLOVER, M.D., 8, Finsbury-circus, E.C.

1871 MAC CORMAC, Sir WILLIAM, Bart., 13, Harley-street, W. (C. 1878-80.)

1893 MCFADYEAN, JOHN, Royal Veterinary College, Great College-street, N.W.

Elected

1896 MACFADYEN, ALLAN, M.D., B.Sc., British Institute of Preventive Medicine, Chelsea-bridge, S.W.

1882 MACKENZIE, FREDERIC MORELL, 29, Hans-place, S.W.

1885 MACKENZIE, HECTOR WILLIAM GAVIN, M.A., M.D., 59, Welbeck-street, W. (C. 1895-7.)

1870 MACKENZIE, JOHN T., Bombay, India.

1878 MACKENZIE, STEPHEN, M.D., 18, Cavendish-square, W. (C. 1888-90.)

1879 MACLAGAN, THOMAS JOHN, M.D., 9, Cadogan-place, S.W.

1865 MACLAURIN, HENRY NORMAND, M.D., 187, Macquarie-street, Sydney, New South Wales.

1896 MCWEENEY, EDMOND JOSEPH, M.D., M.Ch., 84, St. Stephen's-green, Dublin.

1885 MAGUIRE, ROBERT, M.D., 4, Seymour-street, W.

1877 MAKINS, GEORGE HENRY, 47, Charles-street, Berkeley-square, W. (C. 1889-91.)

1887 MALCOLM, JOHN DAVID, M.B., C.M., 13, Portman-street, W.

1892 MANN, HAROLD EDWARD, Alderney.

1890 MANSON, PATRICK, M.D., C.M., 21, Queen Anne-street, W.

1876 MAPLES, REGINALD, Kingsclere, near Newbury.

1868 MARSH, F. HOWARD, 30, Bruton-street W. (C. 1876-7.) (V.-P. 1889-90.)

1887 MARTIN, SIDNEY, M.D., B.S., F.R.S., 10, Mansfield-street, W. (C. 1893-6.)

1889 MASON, DAVID JAMES, M.D., Rosemont, Maidenhead.

1867 MASON, PHILIP BROOKES, Burton-on-Trent.

1892 MASTERS, JOHN ALFRED, M.D., 57, Lexham-gardens, Kensington, W.

1884 MAUDSLEY, HENRY CARE, M.D., 11, Spring-street, Melbourne, Victoria.

1897 MAXWELL, J. P., 49, Highbury-park, N.

1852 MAY, GEORGE, M.B., Reading.

1888 MAY, WILLIAM PAGE, M.D., B.Sc., 49, Welbeck-street, W., and Helouan, near Cairo, Egypt (November to April).

1881 MAYLARD, ALFRED ERNEST, M.B., 4, Berkeley-terrace, Glasgow.

1874 MEREDITH, WILLIAM APPLETON, C.M., 21, Manchester-square, W.

1894 MICHELS, ERNST, M.D., 6, West-street, Finsbury-circus, E.C.

1866 MICKLEY, GEORGE, M.A., M.B., St. Luke's Hospital, Old-street, E.C.

1882 MONEY, ANGEL, M.D., Hunter-street, Sydney, New South Wales.

1879 MOORE, NORMAN, M.D., 94, Gloucester-place, Portman-square, W. (C. 1885-7. V.-P. 1895-7.)

1875 MORGAN, JOHN H., 68, Grosvenor-street, W. (C. 1886-8.)

1874 MORISON, ALEXANDER, M.D., C.M., 14, Upper Berkeley-street, W.

1869 MORRIS, HENRY, M.A. (TRUSTEE), 8, Cavendish-square, W. (C. 1877-9, 1884-6. S. 1881-3. V.-P. 1888-9.)

1879 MORRIS, MALCOLM ALEXANDER, 8, Harley-street, W.

1894 MORRICE, GEORGE GAVIN, M.D., Crown-chambers, Salisbury.

1891 MORTON, CHARLES A., 24, St. Paul's-road, Clifton, Bristol.

Elected

1875 MORTON, JOHN, M.B., Guildford.

1884 MOTT, FREDERICK WALKER, M.D., 25, Nottingham-place, W. (C. 1891-3.)

1879 MOULLIN, CHARLES W. MANSELL, 69, Wimpole-street, W.

1893 MUMMERY, JOHN HOWARD, 10, Cavendish-place, W.

1876 MUNRO, WILLIAM, M.D., C.M., 33, King William-street, E.C.

1885 MURRAY, HUBERT MONTAGUE, M.D., 25, Manchester-square, W. (C. 1896—.)

1894 MURRAY, JOHN, M.B., B.Ch., 133, Harley-street, W.

1887 NASON, EDWARD NOEL, M.B., 80, Abbey-street, Nuneaton.

1873 NETTLESHIP, EDWARD, 5, Wimpole-street, W. (C. 1882-4.)

1875 NEWBY, CHARLES HENRY, 15, Landport-terrace, Southsea, Hants.

1884 NEWLAND-PEDLEY, F., 32, Devonshire-place, Portland-place, W.

1865 NEWMAN, WILLIAM, M.D., Stamford, Lincolnshire.

1895 NIAS, J. BALDWIN, M.D., 5, Rosary-gardens, S. Kensington, S.W.

1868 NICHOLLS, JAMES, M.D., Trekenning House, St. Columb, Cornwall.

1876 NICHOLSON, JOHN FRANCIS, M.D., 29, Albion-street, Hull.

1864 NORTON, ARTHUR T., Ashampstead, Berks. (C. 1877-9.)

1883 NORVILL, FREDERIC HARVEY, M.B., Summerland, Yeovil, Somersetshire.

1856 NUNN, THOMAS WILLIAM, 8, Stratford-place, W. (C. 1864-6. V.-P. 1878-80.)

1880 O'CONNOR, BERNARD, M.D., 25, Hamilton-road, Ealing.

1873 O'FARRELL, GEORGE PLUNKETT, M.D., 19, Fitzwilliam-square, Dublin.

1880 OGILVIE, LESLIE, M.B., C.M., 46, Welbeck-street, W.

1894 OGLE, CYRIL, M.B., 96, Gloucester-place, W.

1850 OGLE, JOHN W., M.D., 96, Gloucester-place, Portman-square, W. (C. 1855-6. S. 1857-60. C. 1861-3. V.-P. 1865-8.)

1876 OLIVER, JOHN FERENS, M.D., 12, Old Elvet, Durham.

1888 OPENSHAW, THOMAS HORROCKS, M.S., 16, Wimpole-street, W.

1875 ORD, WILLIAM MILLER, M.D., 37, Upper Brook-street, W. (C. 1880-2. V.-P. 1893-4.)

1892 ORD, WILLIAM WALLIS, M.D., The Hall, Salisbury.

1879 ORMEROD, J. A., M.D., 25, Upper Wimpole-street, W. (C. 1887-9.)

1875 OSBORN, SAMUEL, 1A, Devonshire-street, W., and Maisonnette, Datchet, Bucks.

1881 OWEN, ISAMBARD, M.D., 40, Curzon-street, W.

1865 OWLES, JAMES ALLDEN, M.D., Hill View, Woking, Surrey.

1870 PAGET, Sir JAMES, Bart., D.C.L., LL.D., F.R.S., 5, Park-square west, Regent's-park, N.W. (P. 1887-8.)

1884 PAGET, STEPHEN, 70, Harley-street, W. (C. 1894-7.)

1895 PAKES, WALTER CHARLES, Guy's Hospital, S.E.

Elected

1897 PARFITT, CHARLES D., M.D., London, Canada.

1872 PARKER, ROBERT WILLIAM, 13, Welbeck-street, W. (C. 1881-3. V.P. 1897—.)

1874 PARKER, RUSHTON, M.B., B.S., 59, Rodney-street, Liverpool.

1853 PARKINSON, GEORGE, 50, Brook-street, W.

1882 PASTEUR, WILLIAM, M.D., 4, Chandos-street, W. (C. 1893-6.)

1885 PAUL, FRANK THOMAS, 38, Rodney-street, Liverpool.

1865 PAVY, FREDERICK WILLIAM, M.D., LL.D., F.R.S., 35, Grosvenor-street, W. (C. 1872-4. V.-P. 1891-2. P. 1893-4.)

1868 PAYNE, JOSEPH FRANK, M.D. (PRESIDENT), (TRUSTEE), 78, Wimpole-street, W. (C. 1873-5, 1883-5. S. 1880-2. V.-P. 1888-9. P. 1897—.)

1872 PEARCE, JOSEPH CHANING, M.D., C.M., Montague House, St. Lawrence-on-Sea, Kent.

1863 PEARSON, DAVID R., M.D., 23, Upper Phillimore-place, W.

1879 PEEL, ROBERT, 130, Collins-street East, Melbourne, Victoria.

1889 PENBERTHY, JOHN, Royal Veterinary College, Camden Town, N.W.

1887 PENROSE, FRANCIS GEORGE, M.D., 84, Wimpole-street, W.

1884 PEPPER, AUGUSTUS JOSEPH, M.B., C.M., 13, Wimpole-street, W.

1888 PERRY, EDWIN COOPER, M.D., Superintendent's House, Guy's Hospital, S.E.

1878 PHILIPPS, SUTHERLAND REES, M.D., St. Ann's-heath, Virginia Water, Chertsey.

1878 PHILLIPS, JOHN WALTER, 30, Stanley-street, West Melbourne, Victoria.

1863 PICK, THOMAS PICKERING, 18, Portman-street, W. (C. 1870-1. V.-P. 1885-7.)

1896 PIGG, T. STRANGEWAYS, The New Museums, Cambridge.

1893 PINKERTON, ROBERT A., M.A., M.D., 15, South Norwood Hill, S.E.

1884 PITT, GEORGE NEWTON, M.D., 25, Portland-place, W. (S. 1894-6. C. 1890-2, 1896—.)

1876 PITTS, BERNARD, M.A., M.C., 109, Harley-street, W. (C. 1888-90.)

1883 POLAND, JOHN, 4, St. Thomas's-street, Southwark, S.E.

1882 POLLARD, BILTON, M.B., B.S., 24, Harley-street, W. (C. 1895-7.)

1850 POLLOCK, JAMES EDWARD, M.D., 52, Upper Brook-street, W. (C. 1862-4. V.-P. 1879-81.)

1870 POORE, GEORGE VIVIAN, M.D., 32, Wimpole-street, W. (C. 1883-5.)

1876 PORT, HEINRICH, M.D., 48, Finsbury-square, E.C.

1879 POTTER, HENRY PERCY, St. Mary Abbotts' Infirmary, Marloes-road, Kensington, W.

1884 POWER, D'ARCY, M.A., M.B. (HON. SECRETARY), 10A, Chandos-street, W. (C. 1891-3. S. 1897-8.)

1865 POWER, HENRY, 37A, Great Cumberland-place, W. (C. 1876-7.)

1887 PRATT, WILLIAM SUTTON, Penrhos House, Rugby.

1884 PRICE, J. A. P., M.D., 41, Castle-street, Reading.

1856 PRIESTLEY, Sir WILLIAM OVEREND, M.D., M.P., 17, Hertford-street, W.

Elected

1888 PRIMROSE, ALEXANDER, M.B., C.M., 196, Simcoe-street, Toronto, Canada.
1882 PRINGLE, J. J., M.B., C.M., 23, Lower Seymour-street, W.
1848 PURNELL, JOHN JAMES, Woodlands, Streatham-hill, S.W. (C. 1858-61.)
1895 PURVIS, WILLIAM PRIOR, M.D., 2, Avenue-place, Southampton.
1865 PYE-SMITH, PHILIP HENRY, M.D., F.R.S., 48, Brook-street, W. (C. 1874-7. V.-P. 1890-1.)

1897 RANKIN, GUTHRIE, 4, Chesham-street, S.W.
1890 Ransom, WILLIAM BRAMWELL, M.D., The Pavement, Nottingham.
1891 RATCLIFFE, JOSEPH RILEY, M.B., C.M., The General Hospital, Birmingham.
1887 RAVEN, THOMAS FRANCIS, Broadstairs, Kent.
1870 RAY, EDWARD REYNOLDS, Dulwich Village, S.E.
1875 REID, ROBERT WILLIAM, M.D., C.M., 8, Queen's-gardens, Aberdeen.
1881 RENNER, WILLIAM, Wilberforce-street, Free Town, Sierra Leone.
1893 RENNIE, GEORGE EDWARD, 16, College-street, Hyde-park, Sydney, N.S.W.
1895 RITCHIE, JAMES, M.D., 85, High-street, Oxford.
1865 Roberts, DAVID LLOYD, M.D., 11, St. John's-street, Manchester.
1871 ROBERTS, FREDERICK THOMAS, M.D., 102, Harley-street, W. (C. 1883-5.)
1878 ROBERTS, WILLIAM HOWLAND, M.D., Surgeon, Madras Army.
1888 ROBERTSON, ROBERT, M.D., The Bungalow, Ventnor, Isle of Wight.
1885 ROBINSON, ARTHUR HENRY, M.D., Mile End Infirmary, Bancroft-road, N.E.
1887 ROBINSON, HENRY BETHAM, M.S., 1, Upper Wimpole-street, W. (C. 1896—.)
1882 ROBINSON, TOM, M.D., 9, Princes-street, Cavendish-square, W.
1888 ROLLESTON, HUMPHRY DAVY, M.A., M.D. (HON. SECRETARY), 112, Harley-street. (C. 1894-7. S. 1898—.)
1858 ROSE, HENRY COOPER, M.D., 16, Warwick-road, Maida-hill, N.W. (C. 1873-4.)
1876 ROSE, WILLIAM, M.B., B.S., 17, Harley-st., W.
1875 ROSSITER, GEORGE FREDERICK, Cairo Lodge, Weston-super-Mare.
1877 ROTH, BERNARD, 38, Harley-street, W., and "Wayside," 1, Preston-park-avenue, Brighton.
1888 ROUGHTON, EDMUND WILKINSON, 38, Queen Anne-street, W.
1891 ROUILLARD, LAURENT ANTOINE JOHN, M.B., Durban, Natal.
1891 RÜFFER, MARC ARMAND, M.D., The Quarantine Board, Alexandria.
1897 RUNDLE, H., 13, Clarance-parade, Southsea.
1895 RUSSELL, JAMES SAMUEL RISIEN, M.D., 4, Queen Anne-street, W.
1891 RUSSELL, WILLIAM, M.D., 46, Albany-street, Edinburgh.
1869 RUTHERFORD, WILLIAM, M.D., F.R.S., 14, Douglas-crescent, Edinburgh.

1854 SANDERSON, JOHN BURDON, M.D., D.C.L.Durham, F.R.S., 64, Banbury-road, Oxford. (C. 1864-7. V.-P. 1873-4.)

Elected

1897 SANTI, P. R. W. DE, 91, Harley-street, W.

1886 SAUNDBY, ROBERT, M.D., 83A, Edmund-street, Birmingham.

1871 SAUNDERS, CHARLES EDWARD, M.D., Sussex County Lunatic Asylum, Hayward's Heath.

1890 SAUNDERS, FREDERICK WILLIAM, M.B., B.C., Chieveley House, Newbury.

1873 SAVAGE, GEORGE HENRY, M.D., 3, Henrietta-street, Cavendish-square, W. (C. 1881-3.)

1882 SAVILL, THOMAS DIXON, M.D., 60, Upper Berkeley-street, W.

1891 SCHORSTEIN, GUSTAVE ISIDORE, M.B., B.Ch., 11, Portland-place, W.

1877 SEMON, Sir FELIX, M.D., 39, Wimpole-street, W. (C. 1885-7.)

1894 SEQUEIRA, JAMES HARRY, M.D., 6, West-street, Finsbury-circus, E.C.

1872 SERGEANT, EDWARD, D.P.H., Town Hall, Preston, Lancashire.

1876 SHARKEY, SEYMOUR J., M.D., 22, Harley-street, W. (C. 1884-6. V.-P. 1895-7.)

1880 SHATTOCK, SAMUEL G., 4, Crescent-road, The Downs, Wimbledon, S.W. (C. 1885-7, 1893-6. S. 1890-2. V.P. 1896-7.)

1885 SHAW, LAURISTON ELGIE, M.D., 10, St. Thomas's-street, S.E.

1886 SHERRINGTON, CHARLES SCOTT, M.D., F.R.S., Holt Prof. of Physiol., University College, Liverpool. (C. 1894-7.)

1856 SHILLITOE, BUXTON, 2, Frederick's-place, E.C.

1875 SIDDALL, JOSEPH BOWER, M.D., C.M., Conybeare, Northam, Bideford.

1880 SILCOCK, A. QUARRY, M.D., B.S., 52, Harley-street, W. (C. 1888-90.)

1866 SIMS, FRANCIS MANLEY BOLDERO, 12, Hertford-street, W.

1892 SLATER, CHARLES, M.B., 81, St. Ermin's Mansions, Westminster, S.W.

1887 SMALLPEICE, WILLIAM DONALD, 42, Queen Anne's-gate, S.W.

1875 Smee, ALFRED HUTCHINSON, The Grange, Hackbridge, Carshalton, Surrey.

1879 SMITH, E. NOBLE, 24, Queen Anne-street, W.

1887 SMITH, FREDERICK JOHN, M.D., 4, Christopher-street, Finsbury-square, E.C.

1875 SMITH, GEORGE JOHN MALCOLM, M.D., Hurstpierpoint, Sussex.

1894 SMITH, GUY BELLINGHAM, M.B., B.S., 24, St. Thomas's-street, S.E.

1897 SMITH, HUGH R., M.D., 11, Gower-street, W.C.

1873 SMITH, RICHARD T., M.D., 117, Haverstock-hill, N.W.

1883 SMITH, ROBERT PERCY, M.D., Bethlem Royal Hospital, St. George's-road, S.E.

1869 SMITH, ROBERT SHINGLETON, M.D., Deepholm, Clifton Park, Bristol.

1892 SMITH, SOLOMON CHARLES, M.D., Four Oaks, Walton-on-Thames, Surrey.

1856 SMITH, Sir THOMAS, Bart., 5, Stratford-place, W. (C. 1867-9. V.-P. 1877-8.)

1866 SMITH, WILLIAM, Melbourne, Australia.

1870 SMITH, WILLIAM JOHNSON, Seamen's Hospital, Greenwich, S.E. (C. 1879-81.)

1870 SNOW, WILLIAM VICARY, M.D., Richmond Gardens, Bournemouth.

1888 SOLLY, ERNEST, M.B., Strathlea, Harrogate, Yorks.

Elected

1868 **SOUTHEY**, Reginald, M.D., 32, Grosvenor-road, S.W. (C. 1882-4.)

1887 Spencer, Walter George, M.S., 35, Brook-street, W. (C. 1896—.)

1888 Spicer, Robert Henry Scanes, M.D., 28, Welbeck-street, W.

1861 Squire, Alexander Balmanno, 24, Weymouth-street, W.

1885 Squire, John Edward, M.D., 122, Harley-street, W.

1890 Stabb, Ewen Carthew, St. Thomas's Hospital, Albert-embankment, S.E.

1895 Starling, Ernest Henry, M.D., 8, Park-square West, Regent's-park, N.W.

1896 Stephens, J. W. W., Pathological Laboratory, Cambridge.

1891 Stiles, Harold Jalland, M.B., C.M., 5, Castle-terrace, Edinburgh.

1897 Still, G. F., 46, Gower-street, W.C.

1879 Stirling, Edward Charles, Adelaide, South Australia [care of Messrs. Elder & Co., 7, St. Helen's Place, E.C.].

1883 Stoker, George, 14, Hertford-street, W.

1884 Stonham, Charles, 4, Harley-street, W. (C. 1893-6.)

1875 Sturge, W. A., M.D., 29, Boulevard Dubouchage, Nice.

1871 **SUTHERLAND**, Henry, M.D., 21, New Cavendish-street, W.

1867 Swain, William Paul, 17, The Crescent, Plymouth.

1881 Symonds, Charters James, M.S., 26, Weymouth-street, Portland-place, W. (C. 1886-8.)

1870 Tait, Robert Lawson, 7, The Crescent, Birmingham.

1886 Targett, James Henry, M.B., M.S., 6, St. Thomas's-street, S.E. (C. 1894-5, 1897—. S. 1895-7.)

1870 Tay, Warren, 4, Finsbury-square, E.C. (C. 1881-2.)

1871 **TAYLOR**, Frederick, M.D., 20, Wimpole-street, W. (C. 1879-81. V.-P. 1897—.)

1885 Taylor, Henry H., 10, Brunswick-place, Brighton.

1892 Taylor, James, M.D.Edin., 49, Welbeck-street, W.

1879 Thin, George, M.D., 63, Harley-street, W. (C. 1889-90.)

1852 **THOMPSON**, Sir Henry, 35, Wimpole-street, W. (S. 1859-63. C. 1865-7. V.-P. 1868-70.)

1897 Thomson, H. Campbell, M.D., 34, Queen Anne-street, W.

1891 Thomson, Henry Alexis, M.D., 32, Rutland-square, Edinburgh.

1884 Thomson, John, M.B., C.M., 18, Walker-street, Edinburgh.

1894 Thomson, StClair, M.D., 28, Queen Anne-street, W.

1892 **Thorburn**, William, B.S., 2, St. Peter's-square, and Rusholme Lodge, Rusholme, Manchester.

1874 Thornton, John Knowsley, M.B., 49, Montagu-square, W.

1872 Thornton, William Pugin, 35, St. George's-road, Canterbury.

1880 Tirard, Nestor Isidore, M.D., 74, Harley-street, W.

1884 Tivy, William James, 8, Lansdowne-place, Clifton, Bristol.

1897 Toogood, F. Sherman, M.D., The Infirmary, 282, High-street, Lewisham, S.E.

Elected

1882 TOOTH, HOWARD HENRY, M.D., 34, Harley-street, W. (C. 1892-4.)
1886 TOTSUKA, KANKAI, Tokio.
1872 TOWNSEND, THOMAS SUTTON, 68, Queen's Gate, S.W.
1881 TREVES, FREDERICK, 6, Wimpole-street, W. (C. 1887-90. V.-P. 1895-7.)
1851 TROTTER, JOHN W., Bossall Vicarage, York. (C. 1865-9.)
1895 TROUTBECK, HENRY, M.B., B.C., 148, Ashley-gardens, S.W.
1859 TRUMAN, EDWIN THOMAS, 23, Old Burlington-street, W.
1888 TUBBY, ALFRED HERBERT, M.S., 25, Weymouth-street, Portland-place, W.
1867 TUCKWELL, HENRY MATTHEWS, M.D., 64, High-street, Oxford.
1858 TUDOR, JOHN, Dorchester, Dorset.
1875 TURNER, FRANCIS CHARLEWOOD, M.D., 15, Finsbury-square, E.C. (C. 1884-6, 1895-7. S. 1891-3. V.-P. 1898—.)
1882 TURNER, GEORGE ROBERTSON, 49, Green-street, W.
1863 TURNER, JAMES SMITH, 12, George-street, Hanover-square, W.
1890 TURNER, WILLIAM ALDREN, 13, Queen Anne-street, W.
1893 TURNEY, HORACE GEORGE, M.D., M.Ch., 68, Portland-place, W.
1858 TURTLE, FREDERICK, Clifton Lodge, Woodford, Essex.
1880 TYSON, WILLIAM JOSEPH, M.D., 10, Langhorne-gardens, Folkestone.

1867 VENNING, EDGCOMBE, 30, Cadogan-place, S.W.
1889 VOELCKER, ARTHUR FRANCIS, M.D., B.S., 31, Harley-street, W. (C. 1895-7.)

1867 WAGSTAFFE, WILLIAM WARWICK, B.A., Purleigh, St. John's-hill, Sevenoaks. (C. 1874, 1878-80. S. 1875-7.)
1885 WAKLEY, THOMAS, jun., 5, Queen's-gate, S.W.
1893 WALKER, NORMAN PURVIS, M.D., 7, Manor-place, Edinburgh.
1881 WALLER, BRYAN CHARLES, M.D., Masongill House, Cowan-bridge, Kirkby-Lonsdale.
1890 WALLIS, FREDERICK CHARLES, M.B., B.C., 26, Welbeck-street, W. (C. 1898—.)
1888 WALSHAM, HUGH, M.A., M.D., B.C., 114, Harley-street, W.
1873 WALSHAM, WILLIAM JOHNSON, M.B., C.M., 77, Harley-street, W. (C. 1881-3.)
1859 WALTERS, JOHN, M.B., Reigate, Surrey.
1892 WARD, ALLAN OGIER, M.D.Edin., Lansdowne House, Tottenham.
1892 WARING, HOLBURT JACOB, M.B., M.S., 9, Upper Wimpole-street, W.
1889 WASHBOURN, JOHN WICHENFORD, M.D., 6, Cavendish-place, W. (C. 1897—.)
1891 WATERHOUSE, HERBERT FURNIVALL, M.D., C.M., 81, Wimpole-street, W.
1892 WEAVER, FREDERICK POYNTON, M.D., Cedar Lawn, Hampstead Heath, N.W.
1890 WEBB, CHARLES FERRE, M.D., New-street House, Basingstoke.
1894 WEBER, FREDERICK PARKES, M.D., 19, Harley-street, W.

Elected

1858 **WEBER**, HERMANN, M.D., 10, Grosvenor-street, W. (C. 1867-70. V.-P. 1878-80.)

1864 WELCH, THOMAS DAVIES, M.D., Fairmount, Frith-hill, Godalming, Surrey.

1894 WELLS, SYDNEY RUSSELL, M.B., 24, Somerset-street, Portman-square, W.

1892 WESBROOK, FRANK F., M.D.(Winnipeg).

1877 WEST, SAMUEL, M.D., 15, Wimpole-street, W. (C.1884-6, 1891-3. S. 1889-90. V.-P. 1896-7.)

1888 WETHERED, FRANK J., M.D., 83, Harley-street, W.

1891 WHEATON, SAMUEL WALTON, M.D., 76, The Chase, Clapham Common, S.W.

1867 WHIPHAM, THOMAS TILLYER, M.D., 11, Grosvenor-street, W. (C. 1880-2.)

1869 WHIPPLE, JOHN H. C., M.D., Army Medical Staff.

1877 WHITE, CHARLES HAYDON, 20, Shakespeare-street, Nottingham.

1894 WHITE, CHARLES POWELL, The General Hospital, Birmingham.

1891 WHITE, GILBERT B. MOWER, M.B., B.S., 112, Harley-street, W.

1881 WHITE, WILLIAM HALE, M.D., 65, Harley-street, W. (C. 1888-90.)

1886 WHITE, WILLIAM HENRY, M.D., 43, Weymouth-street, W.

1868 **Whitehead**, WALTER, 17, Market-street, Manchester.

1897 WHITFIELD, ARTHUR, M.D., 12, Upper Berkeley-street, Portman-square, W.

1877 WHITMORE, WILLIAM TICKLE, 7, Arlington-street, S.W.

1870 WICKSTEED, FRANCIS WILLIAM, Chester House, Weston-super-Mare.

1869 WILKIN, JOHN F., M.D., M.C., Rose Ash House, South Molton, N. Devon.

1871 WILKINSON, J. SEBASTIAN, New Zealand.

1855 **WILKS**, Sir SAMUEL, Bart., M.D., F.R.S. (TRUSTEE), 72, Grosvenor-street, W. (C. 1857-60. V.-P. 1869-72, 1883-5. P. 1881-2.)

1879 WILLCOCKS, FREDERICK, M.D., 14, Mandeville-place, W.

1886 WILLETT, EDGAR WILLIAM, M.B., 25, Welbeck-street, W. (C. 1897—.)

1869 WILLIAMS, ALBERT, M.D. (Travelling).

1858 **Williams**, CHARLES, 48, Prince of Wales-road, Norwich.

1866 WILLIAMS, CHARLES THEODORE, M.D., 2, Upper Brook-street, W. (C. 1875-8.)

1881 WILLIAMS, DAWSON, M.D., B.S., 101, Harley-street, W. (C.1893-6.)

1872 WILLIAMS, Sir JOHN, Bart., M.D., 63, Brook-street, W. (C. 1878-80.)

1881 WILLIAMS, W. ROGER, 28, Winckley-square, Preston.

1876 WILLIAMSON, JAMES MANN, M.D., Ventnor, Isle of Wight.

1863 WILLIS, FRANCIS, M.D., The Spa, Braceborough, Stamford.

1889 WILSON, ALBERT, Leytonstone, Essex.

1888 WILSON, CLAUDE, M.D., C.M., 6, York-road, Tunbridge Wells.

1859 WILSON, EDWARD THOMAS, M.B., Montpelier-terrace, Cheltenham.

1891 WILSON, THEODORE STACEY, M.B., C.M., 65, Temple-row, Birmingham.

Elected

1861 **Windsor**, THOMAS, Medical Library, Boston, Mass., U.S. [care of B. F. Stevens, 4, Trafalgar-square, W.].

1889 WINGRAVE, V. HAROLD WYATT, 11, Devonshire-street, Portland-place, W.

1874 WISEMAN, JOHN GREAVES, Dearden-street, Ossett, Yorkshire.

1865 WITHERBY, WILLIAM H., M.D., Pitt-place, Coombe, Croydon.

1883 WOODCOCK, JOHN ROSTRON, 155, Hagley-road, Birmingham.

1883 WOODHEAD, GERMAN SIMS, M.D., Beverley, 1, Nightingale-lane, Balham, S.W. (C. 1891-3. V.-P. 1898—.)

1879 WOODWARD, G. P. M., M.D., Deputy Surgeon-General; Sydney, New South Wales.

1884 WORTS, EDWIN, 6, Trinity Street, Colchester.

1869 WYMAN, WILLIAM S., M.D., Red Brae, 18, Putney-hill, S.W.

1890 WYNNE, EDWARD T., M.B., 7, Rochester-gardens, Hove, Brighton.

1884 WYNTER, WALTER ESSEX, M.D., 30, Upper Berkeley-street, W.

1872 YOUNG, HENRY, M.B., Monte Video, South America.

ANNUAL REPORT OF COUNCIL, 1897-98.

PRESENTED AT THE ANNUAL MEETING, MAY 17TH, 1898.

YOUR Council have to report the election of twenty-four new members, of whom four are Non-resident, during the past Session.

There have been six resignations, and during the year ten deaths have been reported, viz. W. J. Vereker Bindon, M.D., Edward Cotterell, Henry W. Freeman, Ernest Hart, D.C.L., Henry Lee, Edward Lund, Sir R. Quain, Bart., M.D., F.R.S., Charles Roy, F.R.S., H. Urmson Smith, M.B., and Charles West, M.D.

Dr. West joined the Society in 1851, Mr. Henry Lee in 1852, and Mr. Hart in 1858. Sir Richard Quain was an Original Member, was Treasurer from 1857–68, Secretary from 1852–56, President in 1869–70, and at the time of his death a Trustee of the Society.

There are now 678 members on the roll of the Society.

By the deaths of Mr. George Pollock and Sir Richard Quain the Society has been deprived of two of its three Trustees. The vacancies have been filled, on the nomination of the Council, by Mr. Henry Morris and Dr. J. F. Payne.

By a resolution of the Council it was decided that the extraordinary expenditure incurred in the celebration of the Society's Jubilee in the Session 1896–97 should be defrayed out of Capital. Accordingly Consols to the amount of £100 Stock were sold out, realising the sum of £110 5s., which appears on the credit side of this year's Balance-sheet, and accounts for the large balance in hand as compared with that of last year.

The *income* of the year is made up of—(*a*) Annual Subscriptions, £336; (*b*) Entrance and Composition Fees, £55 13s.; (*c*) Sale of 'Transactions,' £58 11s. 1d.; (*d*) Dividends on Stock (amounting to £1214 3s. 2d.), £32 5s. 8d. Deducting £2 2s. for subscriptions returned, which had been paid twice over, the total receipts amount to £480 7s. 9d., to which must be added £110 5s., the sum realised by the sale of stock, giving, with last year's balance, a total on the credit side of the balance sheet of £601 1s. 8d.

The *expenditure* includes—(*a*) Expenses of Meetings, £134 13s. 6d., which does not, however, comprise the sum due for hire of microscopes, &c., for the current session; (*b*) Cost of production of Vol. XLVIII of the 'Transactions,' £243 1s. 7d.; (*c*) Secretarial expenses, £104 3s. 6d, inclusive of an account for sundry printing and stationery left over from last year, and amounting to £33 17s.

The sum now invested in the name of the Society amounts to £1114 3s. 2d.

Subscriptions amounting to £40 are still due to the Society.

J. F. Payne, *President*.

THE PATHOLOGICAL SOCIETY OF LONDON.

Statement of Receipts and Payments from 16th May, 1897, to 14th May, 1898.

RECEIPTS.

	£	s.	d.	£	s.	d.
Balance at Bank, 15th May, 1897	9	3	2			
„ Petty Cash „	1	5	9			
				10	8	11
170 Annual Subscriptions received by Bank....	178	10	0			
150 „ „ „ Collector	157	10	0			
320 „ „ at £1 1*s.*	336	0	0			
16 Entrance Fees at £1 1*s.*	16	16	0			
4 „ Non-Residents' at £3 3*s.*	12	12	0			
1 Composition Fee (Life) at £21	21	0	0			
1 „ „ £5 5*s.*.....	5	5	0			
	391	13	0			
Less 2 Annual Subscriptions returned	2	2	0			
				389	11	0
Sale of Transactions:						
By Publisher	49	4	7			
By Adlard and Son	9	6	6			
				58	11	1
Dividend on Consols (4 quarters at £8 1*s.* 5*d.* each)				32	5	8
Amount realised by sale of £100 Consols				110	5	0
Amount invested in Consols, £1114 3*s.* 2*d.*						
				£601	1	8

PAYMENTS.

	£	s.	d.	£	s.	d.
Meetings:						
Expenses of Rooms to Christmas, 1897	105	0	0			
Refreshments, Attendance, &c.	26	15	0			
Microscopes, &c. (May, 1897)	2	18	6			
				134	13	6
Transactions:						
Printing, Binding, &c., of Vol. XLVIII	170	8	8			
Illustrations	72	12	11			
				243	1	7
Secretariat and Treasury:						
Assistant Secretary	21	0	0			
Collection of Subscriptions	15	15	0			
Addressing Circulars (1897–8)	2	0	0			
General Printing and Stationery	52	13	8			
Petty Cash Expenditure	12	14	10			
				104	3	6
Balance at Bank	108	18	2			
„ Petty Cash in hand.....	3	18	11			
„ of Cash in hand*	6	6	0			
				119	3	1
				£601	1	8

* (Subscriptions not yet paid into Bank.)

Audited and found correct, 14th May, 1898.

FREDERIC DURHAM, ARCHIBALD E. GARROD, } *Auditors.*

SIDNEY COUPLAND, *Treasurer.* J. F. PAYNE, *President.* R. G. HEBB, *Hon. Secretary.*

LIST OF SPECIMENS AND REPORTS

BROUGHT BEFORE THE SOCIETY DURING THE SESSION 1897–8.

I. DISEASES OF THE NERVOUS SYSTEM.

PAGE

1. Hæmatoma of dura mater (Card specimen)
By CECIL F. BEADLES 1
2. A brain with three consecutive hæmorrhages; a heart (from the same case) showing a well-developed musculus papillaris (or musculus chordæ tendineæ) on the mitral valve By L. FREYBERGER, M.D. 3
3. A tumour of the spinal cord
By H. MORLEY FLETCHER, M.D. 6
4. An unusual case of spina bifida
By R. HENSLOWE WELLINGTON 8
5. Specimens of nerves from a case of chronic traumatic neuritis By WALTER G. SPENCER 10

II. DISEASES, ETC., OF THE ORGANS OF RESPIRATION.

1. Laminated fibrous nodules on the pleura
By CECIL F. BEADLES 13
2. Primary myxo-sarcoma of the pleura
By PERCY KIDD, M.D., and S. H. HABERSHON, M.D. 15
3. Primary sarcoma of the left lung simulating empyema, and producing great contraction of the affected side
By S. H. HABERSHON, M.D. 17

PAGE

4. Nose and lung from a case of glanders By James Berry 20
5. Section of a glanders nodule in the human lung, stained with Löffler's methylene blue, and showing a few bacilli (Card specimen) By F. W. Andrewes, M.D. 22
6. Ulceration of a caseous bronchial gland into the bronchus; fatal asphyxia By Arthur Voelcker, M.D. 22
7. Ulceration of tubercular gland into trachea, with rapidly fatal result By Cyril Ogle 26
8. A case of anæmic infarct in the lung [With Plate X, fig. 1] By L. Freyberger, M.D. 27

III. DISEASES, ETC., OF THE ORGANS OF CIRCULATION.

1. Calcification of pericardium following suppurative pericarditis (Card specimen) By James Calvert, M.D., and T. Strangeways Pigg 31
2. Cancerous pericarditis secondary to malignant stricture of the œsophagus (Card specimen) By R. G. Hebb, M.D. 32
3. Extensive metastatic deposits of carcinoma in the heart (Card specimen) By Arthur Voelcker, M.D. 33
4. Fatty infiltration of the heart; death after ether anæsthesia (Card specimen) By R. G. Hebb, M.D. 33
5. A case of patent septum interventriculare, patent foramen ovale, and congenital stenosis of the pulmonary artery, coupled with an anomalous distribution of the thoracic veins By L. Freyberger, M.D. 35
6. Heart with tumour of the pulmonary valves By Raymond Crawfurd, M.D. 37
7. Heart with extreme calcification of the aortic and mitral orifices, from a case with exceptional physical signs By F. Parkes Weber, M.D. 41
8. Anomalous truncus brachiocephalicus associated with aortic incompetence and symptoms simulating aneurysm By L. Freyberger, M.D. 44

PAGE

9. Aortic incompetence due to dilatation of the orifice without disease of the valves [With Plate I]
By G. Newton Pitt, M.D. 46
10. An aortic aneurysm which ruptured externally
By Lee Dickinson, M.D. 48
11. Aneurysm of the ascending aorta perforating externally
By L. Freyberger, M.D. 51
12. Circumscribed traumatic aneurysm of innominate artery
By George Heaton 54
13. Congenital abnormality of sternum and diaphragm; protrusion of heart in epigastric region
By F. C. Abbott 57

IV. DISEASES, ETC., OF THE ORGANS OF DIGESTION.

1. A case of sarcoma of the tongue By H. Littlewood 60
2. An unusual fistula in the middle line of the anterior part of the tongue, probably congenital
By Percy Furnivall 64
3. Latent tuberculosis of the tonsil [With Plates II and III] By Hugh Walsham, M.D. 67
4. Calculous disease of the submaxillary salivary gland
By W. G. Spencer 85
5. Adeno-chondroma of the right submaxillary gland
By H. J. Curtis 85
6. Peri-œsophageal cyst (Card specimen)
By R. G. Hebb, M.D. 88
7. Two specimens of œsophagitis in infants (Card specimen) By T. D. Lister, M.D. 88
8. Sarcoma of the œsophagus with secondary deposit in the tongue (Card specimen) By G. Brooksbank James 91
9. Carcinoma of the œsophagus which proved fatal by perforation of the aorta By A. E. Garrod, M.D. 92
10. A case of columnar-celled carcinoma of the œsophagus
By C. P. White 93
11. Perigastric cyst (Card specimen)
By R. G. Hebb, M.D. 94

PAGE

12. Stomach showing double perforating ulcer and a perforation of the colon By C. D. Green, M.D. 95
13. A case of extreme contraction of the stomach, with some remarks on the pathology of the condition By G. Bertram Hunt, M.D. 95
14. Carcinoma of the pylorus (Card specimen) By Arthur Voelcker, M.D. 100
15. A case of ulcerative enteritis with perforation By C. P. White 100
16. Intestinal obstruction following the cicatricial contraction of tuberculous ulcers By C. P. White 102
17. Meckel's diverticulum; obstruction of bowels and peritonitis by pressure of pedicle; torsion and strangulation of pedicle; perforation of pyriform extremity and death By J. Tregelles Fox, of Strathpeffer 103
18. Pin perforating the vermiform appendix; peri-appendicular inflammation; hepatic abscess (Card specimen) By H. D. Rolleston, M.D. 106
19. A case of intussusception of the vermiform appendix By H. F. Waterhouse 108
20. Cystic dilatation of the vermiform appendix (Card specimen) By A. G. R. Foulerton 110
21. A cyst removed from the inside of the cæcum By C. A. Morton 111
22. Perforating ulcerative colitis in a lunatic (Card specimen) By Cecil F. Beadles 112
23. Ulcerative colitis (Card specimen) By Arthur Voelcker, M.D. 114
24. A "tumour" of the ascending colon By Raymond Crawfurd, M.D. 115
25. A case of intestinal obstruction due to induration of the great omentum By T. A. Bowes, M.D., and C. P. White 118
26. Carcinomatous stricture of the sigmoid flexure (Card specimen) By Cecil F. Beadles 119
27. Congenital ventral hernia at the umbilicus By W. G. Spencer 120
28. A case of *post-mortem* emphysema of the liver By C. H. Bond, M.D. 121

PAGE

29. Cirrhosis of the liver in a child (Card specimen)
By F. Parkes Weber, M.D. 126
30. Liver showing an early interlobular type of cirrhosis, from a case of suppurative pylephlebitis
By F. Parkes Weber, M.D. 128
31. Pendulous hydatid cyst of the liver
By T. Carwardine, M.S. 130
32. Large intra-hepatic calculi in diabetes
By H. D. Rolleston, M.D. 133
33. Spontaneous fracture of a gall-stone in a gall-bladder
By H. D. Rolleston, M.D. 135
34. Spontaneous fracture of gall-stones
By James Calvert, M.D. 139
35. Congenital round-celled sarcoma of the liver
By George Heaton 140
36. Sarcoma of the liver and supra-renal in a baby
By G. N. Pitt, M.D. 143
37. Primary carcinoma of the liver associated with gall-stone (Card specimen) By Cecil F. Beadles 144
38. Localised effusion in the lesser sac of the peritoneum due to pancreatitis, imitating a pancreatic cyst; fat necrosis (Card specimen) By H. D. Rolleston, M.D. 145
39. Chronic pancreatitis in diabetes (Card specimen)
By H. D. Rolleston, M.D. 150

V. DISEASES, ETC., OF THE GENITO-URINARY ORGANS.

1. Speckled kidneys; irregular fatty degeneration of the renal cortex, possibly caused by plugging of the small blood-vessels shortly before death
By F. Parkes Weber, M.D. 152
2. Congenital cystic liver with cystic kidney [With Plate IV, fig. 1] By G. F. Still, M.D. 155
3. Cystic disease of the kidneys and liver
By Raymond Johnson 165

PAGE

4. Chronic interstitial nephritis, with cysts in the renal pelvis, double ureter and malformation (?) of the bladder (Card specimen)
By Arthur Voelcker, M.D. 168
5. A preliminary note on atrophy of the kidney produced experimentally By John Rose Bradford, F.R.S. 169
6. Hæmatocele of a hydronephrotic kidney
By John Rose Bradford, F.R.S. 171
7. A case of double pyonephrosis caused by the impaction of renal calculi By L. Freyberger, M.D. 173
8. Adenoma (?) of kidney (Card specimen)
By Stanley Boyd 175
9. Tumour of the left kidney; cystic adenoma? (Card specimen) By H. Littlewood 175
10. Papillary adenoma of the kidney (Card specimen)
By F. Parkes Weber, M.D. 176
11. A case of lympho-sarcoma of the pelvis of the kidney
By C. P. White 178
12. Primary carcinoma of kidney (Card specimen)
By Cecil F. Beadles 179
13. Undescended left testicle with complete twisting of the cord (Card specimen) By H. Littlewood 181
14. Multiple fibromata of the right tunica vaginalis (Card specimen) By H. Littlewood 182
15. A retro-peritoneal cyst, supposed to have originated in the remains of the Wolffian body By C. B. Lockwood 182
16. Ovarian cyst successfully removed from a child aged four months By D'Arcy Power 186
17. Pyosalpinx and cystic condition of left ovary (Card specimen) By G. Brooksbank James 189
18. Uterus bicornis (Card specimen)
By Arthur Voelcker, M.D. 189
19. Uterus unicorporeus et vagina duplex
By H. Morley Fletcher, M.D. 190
20. Tumours of the uterus and its appendages
By H. Morley Fletcher, M.D. 190

VI. DISEASES, ETC., OF THE ORGANS OF LOCOMOTION.

PAGE

1. A case of multiple spontaneous fractures
By CHARLES SPURRELL 192
2. A case of multiple spontaneous fractures
By EDGAR WILLETT 195
3. Fragilitas ossium (Card specimen)
By L. G. GUTHRIE, M.D. 199
4. Ununited fracture of the scapula (Card specimen)
By C. P. WHITE 199
5. Empyema of the antrum in a child aged eight weeks
By D'ARCY POWER 200
6. Sarcoma of left clavicle (Card specimen)
By H. LITTLEWOOD 202
7. Tumour of scapula — squamous epithelioma (Card specimen) By H. LITTLEWOOD 202
8. Macrodactyly due to diffuse lipoma [With Plate V]
By ROBERT JONES 203

VII. DISEASES, ETC., OF THE DUCTLESS GLANDS.

1. Pathological report upon a case of acromegaly, with an analysis of the results of forty-nine *post-mortem* examinations on cases of acromegaly [With Plates IV, fig. 2; VII, figs. 1 and 2; IX, fig. 1]
By PERCY FURNIVALL 204
2. Specimen of a tumour of the pituitary body from a case of acromegaly [With Plate VI, fig. 1]
By J. BREWARD NEAL and E. J. SMYTH, M.D. 224
3. Pathological report upon Mr. Breward Neal and Dr. E. J. Smyth's case of acromegaly [With Plate VI, fig. 1]
By SAMUEL G. SHATTOCK 228

PAGE

4. A case of acute acromegaly due to sarcoma of the pituitary body By H. D. Rolleston, M.D. 237
5. Further notes on a case of acromegaly By Norman Dalton, M.D. 242
6. A case of acromegaly; hypertrophy of pituitary body and thyroid; changes in bone marrow [With Plate VI, fig. 2] By William Hunter, M.D. 246
7. Gumma of the pituitary body By William Hunter, M.D. 249
8. Hæmorrhage into the supra-renal capsules in infants By Geo. F. Still, M.D. 252
9. Hæmorrhage into both supra-renal capsules in an infant aged four months By A. E. Garrod, M.D., and J. H. Drysdale, M.D. 257
10. Hæmorrhage into the supra-renal capsule By F. E. Batten, M.D. 258
11. Hæmorrhage into the supra-renal capsule By F. W. Andrewes, M.D. 259
12. Tumour of the supra-renal body (Card specimen) By Cecil F. Beadles 260
13. Myxœdema: a report on three fatal cases, one of them associated with trichinosis [With Plate VIII] By Cecil F. Beadles 262

VIII. DISEASES, ETC., OF THE SKIN.

1. Lipoma nasi (Card specimen) By Edgar Willett 290
2. Papilliferous cyst of a sudoriparous gland from the axilla By H. Betham Robinson, M.S. 290
3. Round pellets of sebaceous material from a dermoid cyst (Card specimen) By H. D. Rolleston, M.D. 292
4. Mycetoma papillomatosum [With Plate X, figs. 3, 4] By S. G. Shattock 293

IX. MORBID GROWTHS.

PAGE

1. A case of melanotic sarcoma (Card specimen)
By JAMES CALVERT, M.D., and T. STRANGEWAYS PIGG 297
2. Symmetrical rodent ulcers of the face
By PERCY FURNIVALL 299
3. Symmetrical rodent ulcers in the groin (Card specimen)
By T. STRANGEWAYS PIGG 300
4. Rodent ulcer near the umbilicus (Card specimen)
By H. D. ROLLESTON, M.D. 301
5. A case of duct papilloma of the breast followed by colloid carcinoma; recurrence and dissemination
By C. E. M. KELLY and W. D'ESTE EMERY, M.D. 303
6. Lobulated fibroma of the nipple By C. D. GREEN, M.D. 308
7. Lipoma of the ischio-rectal fossa (Card specimen)
By H. J. CURTIS 309
8. Lipomata: α. From back of right shoulder; β. From the substance of the right deltoid (Card specimens)
By H. LITTLEWOOD 310
9. Fibro-sarcoma of the hand (Card specimen)
By H. LITTLEWOOD 310
10. Sarcoma of the hand (Card specimen)
By H. LITTLEWOOD 311
11. Squamous-celled carcinoma of the alveolar process of the upper jaw, removed by operation from a man aged twenty (Card specimen) By W. G. SPENCER 312

X. BACTERIOLOGY.

1. The bacteriology of simple posterior basic meningitis of infants [With Plate IX, figs. 2 and 3]
By G. F. STILL, M.D. 313
2. Experiments to determine whether sewer air will raise the toxicity of lowly virulent diphtheria bacilli
By S. G. SHATTOCK 328

PAGE

3. The presence of fat in *Bacillus mallei*, and the infectibility of white mice, commonly stated to be immune
By S. G. SHATTOCK 333
4. Observations upon the distribution in the tissues of the leprosy bacillus, and upon the histogenesis of giant-cells in leprous lesions of the larynx
By PAUL BERGENGRÜN (communicated by Prof. KANTHACK) 336
5. The pleomorphism of the common colon bacillus
By H. C. HASLAM 345
6. Colon bacillus grown on glucose with very small amount of nitrogenous material (Card specimen)
By H. C. HASLAM 351
7. Enlarged inguinal glands from a case of Indian plague; with a portion of spleen from the same case showing infarction (Card specimen)
By T. STRANGEWAYS PIGG 351

XI. MISCELLANEOUS COMMUNICATIONS.

1. The action of cobra poison on the blood: a contribution to the study of passive immunity
By J. W. W. STEPHENS and W. MYERS 352
2. A preliminary note on the antidotal properties of normal tissue emulsions with respect to cobra poison
By W. MYERS 368
3. Eosinophile leucocytes in the blood from a case of pemphigus By J. H. DRYSDALE 370
4. The serum-therapy of typhoid fever
By T. J. BOKENHAM 373
5. The serum-therapy of affections caused by infection with streptococci By T. J. BOKENHAM 378

XII. DISEASES, ETC., OF THE LOWER ANIMALS.

PAGE

1. Observations on the hatching of the ova of *Bilharzia hæmatobia* By C. G. Seligmann 386
2. Supernumerary dorsal fin in a trout By C. G. Seligmann 388
3. Two examples of malformation in fish By C. G. Seligmann 390
4. Molluscum contagiosum of the legs and feet and head of a white Wyandotte chicken (Card specimen) By T. Colcott Fox, M.D. 393
5. Molluscum contagiosum in two (mated) bunting sparrows [With Plate X, fig. 2] By Samuel G. Shattock 394

REPORTS OF THE COMMITTEE ON MORBID GROWTHS.

PAGE

1. On Mr. Wellington's specimen of spina bifida
[J. H. TARGETT and S. G. SHATTOCK] 10

2. On Dr. Crawfurd's tumour of the pulmonary valve
[A. A. KANTHACK and D'ARCY POWER] 41

3. On Mr. H. Littlewood's specimen of sarcoma of the tongue
[W. G. SPENCER, H. D. ROLLESTON, S. G. SHATTOCK] 63

4. On Dr. Raymond Crawfurd's specimen of tumour of the ascending colon
[S. G. SHATTOCK and J. H. TARGETT] 117

5. On Mr. Kelly and Dr. Emery's case of duct papilloma of the breast followed by colloid carcinoma
[S. G. SHATTOCK and NORMAN MOORE] 307

LIST OF PLATES.

		TO FACE PAGE
I.	Aortic incompetence due to dilatation of the orifice without disease of the valves. (Dr. Newton Pitt.) (Page 46)	47
II.	Latent tuberculosis of the tonsil. (Dr. Hugh Walsham.) (Page 67)	71
III.	Ditto ditto	79
IV.	Congenital cystic liver. (Dr. G. F. Still.) (Page 155) Microscopical section of the anterior lobe of the pituitary body from a case of acromegaly. (Mr. Furnivall.) (Page 210)	157
V.	Macrodactyly due to diffuse lipoma. (Mr. Robert Jones.) (Page 203)	203
VI.	Sections of the pituitary body: Fig. 1. Right half from a normal pituitary body, left half from the periphery of a pituitary goitre, illustrating Mr. Shattock's report upon Mr. Breward Neal and Dr. Smyth's case of acromegaly. (Pages 224—237) Fig. 2. Section from a case of hypertrophy of the pituitary body in a case of acromegaly. (Dr. Hunter.) (Page 246)	229
VII.	Fig. 1. Microscopical section through the anterior lobe of a pituitary body in a case of acromegaly Fig. 2. Microscopical section through the thyroid gland from a case of acromegaly. (Mr. Furnivall.) (Page 209)	210

TO FACE PAGE

VIII. Fig. 1. Thyroid gland from a case of myxœdema
Fig. 2. Pituitary body from a case of myxœdema
Fig. 3. Portion of the wall of the heart from a case of myxœdema
Fig. 4. Portion of the lung from a case of myxœdema
Fig. 5. Ditto ditto
Fig. 6. Ditto ditto
(Mr. Cecil F. Beadles.) (Page 262) — 266

IX. Fig. 1. The lower jaw from a case of acromegaly. (Mr. Furnivall.) (Page 208)
Fig. 2. Photograph of the diplococcus found in the simple posterior basic meningitis of infants. (Dr. Still.) (Page 313)
Fig. 3. Photograph of the growth of the diplococcus on Agar-agar. (Dr. Still.) (Page 313) — 318

X. Fig. 1. An anæmic infarct in the lung. (Dr. Freyberger.) (Page 27)
Fig. 2. Molluscum contagiosum in birds. (Mr. Shattock.) (Page 394)
Figs. 3, 4. Section of the skin in mycetoma papillomatosum. (Mr. Shattock.) (Page 293) — 294

LIST OF FIGURES IN THE TEXT.

		PAGE
1.	Tumour of the pulmonary valve	39
2.	Abnormality of sternum and diaphragm	57
3.	Sarcoma of the tongue	62
4.	Fistula of the tongue	64
5, 6.	Pendulous hydatid cyst of the liver	131
7.	Multiple spontaneous fractures	193
8, 9, 10.	Multiple spontaneous fractures	196, 197
11.	Lobulated fibroma of the nipple	308
12.	Glanders bacilli containing oil globules	334
13—18.	The distribution of leprosy bacilli in the tissues	337—343
19.	Supernumerary fin in a trout	389
20.	Stickleback with two spines	390
21.	Malformation in a pike	391
22, 23.	Molluscum contagiosum in a fowl	393, 394
24, 25.	" " in Bunting sparrows	398

AN ADDRESS

ON

THE STUDY OF MORBID ANATOMY.

By JOSEPH FRANK PAYNE, M.D.Oxon.,
PRESIDENT OF THE SOCIETY.

Gentlemen,—In taking the chair of this Society for the first time, I must thank you for the great honour you have done me in electing me your President. The remembrance of the eminent names which have previously conferred distinction on this office, while it adds to the honour, increases also the responsibility of filling it. I can only say that I will do my best for the prosperity of a Society in which I have taken the warmest interest, which it was formerly my privilege to serve as Secretary, and which I have always regarded as standing in the first rank of medical societies.

The past history of our Society was so fully dealt with by our retiring President, Mr. Butlin, in his able address of last year, that it would be superfluous for me to dwell upon that theme.

But the occasion seems an appropriate one for reviewing the position of our Society, which, like many other great institutions, does not lack its critics; and for considering what are rightly to be comprised among the main objects of our activity.

Now, to begin with our critics: The first point which often falls under the censure of our critics is our name. We are often told that the name pathology is much too wide for us, and that we use

this great name while we confine our attention to certain limited branches of this vast subject.

Now it must be admitted that if we were bound strictly by name, there is some truth in this stricture. Pathology and therapeutics include the whole of medicine and surgery; and if we omit therapeutics and prophylaxis, or the science of health, which, though closely related to the art of healing, is not strictly a part of it, there is no department of medical science which this name does not cover.

But the blame for this error, if it is an error, does not rest with this Society. It falls upon a great part of English medical literature. We use the word in a more limited sense than that in which it is used in the medical literature of other countries. We mean, generally, morbid anatomy or morbid histology. And it is, I think, to be regretted that some of our excellent text-books, dealing exclusively or chiefly with pathological histology, have been entitled treatises on "pathology," whereas the corresponding works in the literature of France and Germany limit themselves to the title of "pathological histology." This conception of pathology has become so widely spread that a candidate at an examination, if asked about pathology, thinks he has to answer about something which is seen through a microscope.

Let me say, however, that this mistaken idea of the all-importance of pathological histology is not confined to students in our own country. I remember, when I was studying at Vienna, the great clinical teacher, Oppolzer, having to speak of a case of pneumonia, and looking about for some peg on which to hang his discourse, asked a student the fundamental question, "Well, then, what is pneumonia?" The student, under the glamour of the mysteries then lately revealed in Virchow's cellular pathology, began to mutter something about "proliferation of connective tissue," till the professor burst into a hearty laugh. "Well, I dare say that is quite true, but at the same time there is something more." And then he went on to show how much besides this was included in the conception of a disease like pneumonia. Now, though the word pathology was not, I think, mentioned, the Vienna student exhibited in a concrete form the very error of which I am speaking.

No one really thinks that anatomical changes, whether gross or minute, make up the whole of pathology. But words are, as

Bacon said, not vain things, and the use of them in a wrong sense is sure in the end to bring about some confusion in ideas. Allowing all this, I do not see that the fault is to be attributed to our Society. It is difficult to see what other name could have been given to the Society by its founders, since they certainly did not intend to include—except therapeutics—the whole of medical and surgical science. It would not have been any better to call it the Society for the Study of Morbid Anatomy, which would have limited its scope far too narrowly. Nor could anyone reasonably propose that the name of the Society should now be changed, even if a more appropriate one could now be found. We must agree that this Society is now, and always will be called the Pathological Society of London. Our only question is, What branches of the science of medicine rightly belong to our province?

The limitation of topics characteristic of our Society, whether it be spoken of with praise or blame, has been brought about to a large extent by one of its fundamental rules, which I think has constituted its great strength, and to which the prosperity and utility of the Society have been very largely due. I mean the regulation that no communication should be received which is not accompanied by a material specimen of some kind. This law the Society has lately thought proper to modify—and no doubt rightly, since any such law may be pressed with pedantic rigour. But it will, I expect, in the main be still the custom of the Society to make demonstration of specimens of some kind its chief work. I think the occasional exclusion of valuable communications by this rule has been more than compensated for by the great authenticity and trustworthiness ensured by it in the communications which have been admitted. It is something like the rules for admission of evidence in courts of law, which, though sometimes excluding materials useful for arriving at a verdict, yet ensure that the evidence which is admitted shall be unchallengeable. There is a vast difference between the statements of any observer, however competent and veracious, about an object, and the view, handling, or examination of the object itself. The subject matter of science is not statements about things, but the things themselves. Till we see the object we may often be in doubt exactly what the observer meant by his description, and, though a careful description may be accepted when the object is inaccessible; if the object is accessible so much the better.

The importance of this practice of our Society may be judged of by the fact that many other societies have adopted similar rules. The Clinical Society, younger than our own, was the first systematically to encourage the exhibition of living patients in place of mere reports of cases. The Physiological Society makes its chief business the demonstration of experiments; and all the special medical societies are mainly, or in some cases exclusively, concerned with the exhibition of patients and specimens.

So much for our methods. I will now speak of our objects. The study of disease, or pathology in its widest sense, has always rested upon two main foundations—namely, the study of the material changes in organs or tissues which are associated with disease, whether as cause or effect, on the one hand; and the study of the functional or dynamical changes associated with disease on the other hand. These two lines of investigation have always been followed, though sometimes the one, sometimes the other, has had the preponderance, while the other side of medicine has fallen into the background. The two schools or lines of investigation concerned with these two sides of medical science may be more or less clearly distinguished through the whole of the history of scientific medicine. The one may be called the anatomical school, the other the functional or physiological. The subject matter of the anatomical school is of course pathological anatomy in its widest sense; the subject of the other might be called pathological physiology. It would be a great mistake to distinguish them as pathological and clinical, especially if by pathological we understand only the study of changes in the body observed after death.

The great object of our Society, though never explicitly defined as such, I take to be the study of material changes associated with disease in the tissues and organs of the body. Functional or physiological disturbances we do not absolutely exclude as such, but it is clear that the methods of our Society make it very difficult that they should be brought before us. In fact, we belong to the anatomical school. The great question as to the utility of our Society, is whether the study of material morbid changes in the body is really important and helps the study of disease in a wide sense.

Now, it may be thought that the importance of this study could not be doubted; nevertheless, some eminent men, both in ancient

and modern times, have seriously called it in question. Even lately I have read statements such as these—that morbid anatomy can never throw any true light on the real nature of the disease: that the state of the organs after death shows us only the relics of disease—the remains of injured cells and tissues, not the process by which these changes have been effected. Now, to have the objections to morbid anatomy put fairly and fully let us quote no obscure names, but choose one of the greatest clinical physicians that ever lived, Sydenham, for he stated these objections in a manner not differing much from those words which I have referred to, and with great force.

Sydenham, it should be stated, while rejecting authority or the dogmatic method in medicine, and also repudiating the chemical and mechanical theories of disease current in his day, was equally in opposition to, or at least out of sympathy with another school which flourished in his time—the anatomical. Men like Lower, Glisson, Wharton, and many others, rightly regarded as the successors of Harvey, were labouring to advance medicine by means of anatomy. Sydenham took little interest in their pursuits, and thought they were on the wrong track. He avows that he had never devoted himself to minute investigations in anatomy, which, though they were unknown to the past age, yet had no application to the art of healing. (MS. in College of Physicians.) He allowed that a physician ought to know anatomy, though he thought no very profound knowledge was necessary. But of morbid anatomy he speaks with something like contempt.

There is a curious MS. fragment of a projected treatise to be entitled 'Anatomica,' on the relations of anatomy to medicine, in the handwriting of Sydenham and his friend Locke (also an accomplished physician as well as a great philosopher), first published in Mr. Fox Bourne's 'Life of Locke,' which gives their views on this subject.

The first sentence is in Sydenham's handwriting, and is as follows: "Others have more pompously and speciously prosecuted the promoting of this art (medicine) by searching into the bowels of dead and living creatures, as well sound as diseased, to find out the seeds of (disease) destroying them; but with how little success such endeavours have been and are likely to be attended, I shall here in some measure make appear." Locke follows in the same strain: "All that anatomy can do is only to show us the gross and

sensible parts of the body, or the vapid and dead juices; all which after the most diligent research will be no more able to direct a physician how to cure a disease than how to make a man." The gist of the whole is, says Mr. Fox Bourne, to show that anatomy can never show the cause of any disease or the means of its cure.

Sydenham and Locke never published this projected treatise, and perhaps may have thought, after all, that their assertions were a little too sweeping. But the negative evidence derived from Sydenham's published works shows, I think, that he thought very little of morbid anatomy.

It may be said that in Sydenham's time morbid anatomy was in a very rudimentary stage, and had not effected much. This is, no doubt, partly true; but still, some important observations had been made, such as the discovery that apoplexy was caused by the bursting of a blood-vessel in the brain (to which Sydenham himself refers). This surely threw more light on that disease than would have been thrown in the course of centuries by the most skilful clinical physicians if they never made a *post-mortem* examination. Wepfer, of Schaffhausen, had written fully on this subject in 1658.

Harvey, as is well known, began the study of morbid anatomy, and thought it of great importance, though his observations on that subject are unfortunately lost. Riva, a physician, at Rome, contemporary with Sydenham (he died in 1677), is said by Haeser to have founded a society for the promotion of pathological anatomy, and to have formed a museum. Even in London many *post-mortem* examinations were made in Sydenham's time. There are fragmentary records of inspections made at St. Thomas's Hospital, which I have had the pleasure of bringing to light, but they cannot be said to have been very fruitful.

These sayings of Sydenham are not quoted with any intention of detracting from his fame, which would be as absurd as unworthy. A man of great original genius, as Sydenham was, engaged in prosecuting science by one method earns the right of neglecting, or even of slighting another method, which seems to him less valuable. It is the privilege of genius to be one-sided. But to be one-sided without the excuse of genius is less justifiable.

Sydenham, we can only say, did not belong to the anatomical school, though that was the school of Harvey. He belonged to the school of which he was himself the founder. Had he lived in

this century, he would probably have thought very differently of morbid anatomy.

Perhaps Sydenham's example had something to do with the neglect of anatomy by English physicians in the eighteenth century, when his influence became supreme. The anatomical school came to an end for the time. William Hunter was the only great physician of that period who was also a great anatomist; and there was no morbid anatomist till we come to Matthew Baillie.

Without further entering into history we may say that there has been, in spite of the triumphs of morbid anatomy, a certain undercurrent of disparagement or neglect, sometimes silent, sometimes avowed, which has not ceased even in our time. It would be needless to make other quotations; but the feeling was put in a concise and witty form by my late much-honoured friend Dr. Octavius Sturges, who, in trying to show that chorea could not be explained by morbid anatomy, asked this question: "Why seek ye the living among the dead?"

This, gentlemen, is the case against morbid anatomy. Let us see what can be said on the other side.

In speaking of morbid anatomy I do not use the word as restricted to *post-mortem* examinations. I understand it in the wide sense formerly defined as the investigation of the material changes of disease, by whatever method this investigation may be carried out.

Pathology is so far from being exclusively a *post-mortem* study that in one sense it ends with death, when its subject—disease—also comes to an end.

> "The first dark day of nothingness,
> The last of danger and distress,"

is also the last of disease. But the evidences of disease remain. We study them after death only so far as they are not accessible during life. The human body is, unfortunately for our purpose, not transparent, and this defect has only partially been remedied by the discovery of the X rays.

Again, we cannot dig and delve into the living body as we can when life is extinct. But if specimens can be obtained from the living body, they are still better adapted for our purpose. Modern surgery has helped us in this matter. For instance, the

morbid anatomy of the ovaries is now founded more on surgical than on *post-mortem* specimens. This is equally true of the pathology of the vermiform appendix, and I need not point out that the study of tumours is now not even predominantly a *post-mortem* investigation. Living patients, again, often teach us more morbid anatomy than we should learn from a *post-mortem*. All these methods of study belong to our subject, and it would be a great mistake to call all that is observed during life clinical, and only that which is observed after death pathological.

Further, to show the inadequacy of the distinction between so-called clinical and pathological medicine, I will venture to affirm that one important branch of what is called clinical medicine at the present day is really a study of morbid anatomy. I mean what is called physical diagnosis, not merely that effected by auscultation and percussion, but also the simpler investigation of abdominal organs, and partly that of the nervous system also.

Nothing important which happens is really the result of accident. It cannot, therefore, have been an accident that these methods of research were not invented till morbid anatomy had become to a large extent a systematic science. When the morbid changes of internal organs became known, the attempt to detect these changes during life naturally followed.

Thus physical diagnosis grew out of morbid anatomy. Good evidence of this is afforded by the practice of Dr. Matthew Baillie, our first systematic writer on morbid anatomy, and an eminently successful practical physician. His friend, Sir Henry Halford, says that the attention which Baillie paid to morbid anatomy enabled him to discriminate between symptoms and distinguish diseases nearly resembling one another. Baillie, he says, laid a great stress upon the information which he might derive from the external examination of his patient, and was much influenced in the formation of his opinion upon the case by this practice, which he adopted from the peculiar turn of his earlier studies, that is, in morbid anatomy. Sir H. Halford's acuteness detected the novelty in Baillie's method of external examination, and the knowledge on which it was based ; though he had doubts about its utility. He thought this method of examination might be a valuable adjunct to others, and, in the hands of one so skilful as Baillie might prove successful, but was an example of dangerous tendency to anyone who had not his knowledge and experience.

This is, however, at the present time the method universally practised. We consider physical diagnosis the foundation of all diagnosis in diseases of the internal organs. Nothing could show more clearly the change in clinical methods which morbid anatomy has brought about. But physical diagnosis as practised by Baillie was in its infancy. He knew nothing of auscultation, nor, I think, of percussion. Had he lived a little later he would doubtless have welcomed these discoveries with enthusiasm.

Auscultation was the invention chiefly of Laennec, though Avenbrügger's invention of percussion preceded it by many years. These methods, especially that of Laennec, are based upon morbid anatomy, but the intimate relation between the two subjects, has, I think, been inadequately appreciated. Laennec though generally known as a clinical physician, was also a profound pathological anatomist; one of the most accurate and enthusiastic that ever lived.[1] Had he never invented the stethoscope he would still be a name in the history of medicine. Laennec was the successor and indeed a pupil of Bichat, who is reported to have said: "Take away some fevers and nervous troubles, and all else falls to the domain of pathological anatomy." His striking original merit was, it seems to me, that he first showed how the facts of morbid anatomy known by *post-mortem* examination could be detected and studied in the chest of a living patient. The physical diagnosis which we owe to him is essentially a study of morbid anatomy from the outside and during life. It is a clinical method in the sense that it is practised at the bedside, but to call it clinical as opposed to pathological is a misnomer.

It is, of course, conceivable that a certain number of physical signs might have been detected and empirically connected with certain diseases, without their actual causes being known. But this could not have led to any general system, as is shown by the fact that no important consequences flowed from the scattered facts relating to auscultation, known before the time of Laennec. It was only when such signs were systematically connected with known changes in the internal organs that they became significant. Moreover, only by *post-mortem* examination could the physical signs observed during life be verified. Thus morbid anatomy and physical diagnosis are different aspects of the same

[1] 'Encyclopædia Britannica,' 9th edition, Article, "History of Medicine."

study, indissolubly connected, sometimes the one, sometimes the other coming first in development.

Historically this is, I believe, a true account of the relations of clinical and pathological medicine as applied to diseases of the chest. It might be shown, if I had time, that morbid anatomy has contributed equally to the diagnosis of the diseases of other parts, as, for instance, of diseases of the nervous system, and of the specific fevers which were formerly massed together as typhus till morbid anatomy disentangled them.

But the connection of morbid anatomy and diagnosis is closer than that of a merely historical sequence; it is a relation almost of identity. Our physical diagnosis is not immediately the diagnosis of a particular disease, but immediately that of certain physical conditions, which, if occurring in certain parts and in a certain order, are known by experience to be indicative of a certain disease. Consolidation or excavation of the lung, blocking of air tubes, presence of fluid in the pleura and so on, are the conditions recognised. Experience and associated symptoms teach us that they indicate pneumonia, phthisis, bronchitis, or pleurisy, as the case may be. This kind of diagnosis is really a study in morbid anatomy, anticipating the result of *post-mortem* examination.

Equally true is it that auscultation and percussion of the heart do not indicate disease directly, but only mechanical and physical conditions which follow or cause disease—that is, facts of morbid anatomy. Equally true is it in diseases of the abdomen that by physical diagnosis we endeavour to ascertain the morbid anatomical condition of organs which we cannot see. All that is pathological anatomy; and in many diseases, as Bichat said, the morbid anatomical condition is the determining one. By combining our knowledge of it with observation of functional changes we make a complete diagnosis. In acute fevers and some other diseases where the functional element predominates, our diagnosis is not an anatomical one. We may know by experience the state of the organs, but that is not our immediate object of research. Still in all cases where anatomical or so-called pathological diagnosis is possible, that constitutes the most exact and trustworthy part of clinical diagnosis.

It is not too much to say that in diseases of internal organs (of which alone I am speaking) that physician's diagnosis is likely, other things being equal, to be most exact, who can form to him-

self the most precise mental picture of the state of a diseased organ, and who knows also how to infer the existence of that state by observations during life. For this purpose a mere text-book knowledge of morbid anatomy is insufficient. It is necessary to have seen, handled, weighed, and examined diseased organs for oneself. Need I recall the names of those eminent men who in our time have been and are masters of this pathological diagnosis? It is or was the distinguishing feature in the practice of men like Sir William Jenner, Sir Samuel Wilks, and my departed colleagues, Dr. Murchison and Dr. Bristowe, all names well known in this Society. Nor would it be difficult to enumerate many more did time permit. No doubt there are other means of diagnosis, the functional, the symptomatic, and the personal—also the method of common sense. It is only claimed for morbid anatomy that it supplies the most solid and fundamental facts, and that without it modern clinical medicine could not exist.

I have now spoken of morbid anatomy in relation to clinical medicine, so far as both are concerned with the study of cases; and much more might be added to show the debt which the *art* of medicine owes to pathology. But I must pass on to speak of the services of pathology or morbid anatomy to the *science* of medicine, which services are perhaps more called in question.

Now though, as I have urged already, the anatomical side is only one of the two aspects of medical science, it is one of enormous importance, and is intimately concerned even in the most recent phases of medical progress.

To speak only of one branch of scientific investigation—bacteriology; let us consider what part morbid anatomy, including, of course, histology, has played in its advancement.

Bacteriology is, strictly speaking, a branch of biology, or specially of botany, but it has many sides. We deal with it only as concerned with disease. The bacteriologist, when he makes cultivations, is a botanist; when he detects bacilli in diseased tissues or in tubercles produced in animals by inoculation, he is a pathological anatomist; when he studies the production of immunity in living animals, he is rather a clinical investigator. But he can seldom dispense with pathological anatomy or histology. There are two main lines of activity in pathogenic bacteria. One is the injury or destruction of cells and tissues; the other diffuse poisonings, or functional disturbances produced by their products.

The first kind of pathogenic activity is shown by the bacillus of tubercle, which is chiefly injurious by its destructive action on the tissues, though no doubt its products are also injurious. The second kind is seen in such organisms as the tetanus bacillus, which is injurious chiefly by functional poisoning through its products, the tissue changes being subordinate.

Different means of research are required in each case, but, as regards the tissue-destroying bacilli, the investigation is almost entirely pathologico-anatomical. Even in the study of such organisms as the tetanus bacillus, morbid anatomy plays an important part. Indeed, without morbid anatomy there could have been little bacteriology of disease.

Bacteriology, therefore, is a subject strictly belonging to the field of this Society. Even on its botanical side it is a part of the science of parasites, which has always received attention here and which is certainly a part of the science of pathology.

Pathological chemistry is so closely connected with material changes in the body that it has always accompanied pathological anatomy, and is one of our recognised subjects.

With regard to pathological physiology or pathology studied by experiments in the physiological laboratory, the case is not so clear. It has been said that physiology and pathology are one, which seems something like saying that virtue is the same thing as vice. But still there is a certain partial truth in the statement, for as virtue and vice both come under the purview of one science—that of ethics; so both physiology and pathology may be studied by the same scientific methods, and are subject to the same laws. Yet pathology is too wide a subject to be made a mere province of physiology. To a certain extent they are coterminous territories, but to confine the term pathology to that part where it is in contact with physiology would be a most injurious limitation—one quite as erroneous as that too narrow definition of pathology which has been made a reproach to English medicine and to our Society. After all, Where would physiology itself be without anatomy? Where pathology without morbid anatomy? The study of function is not the whole of biology.

These pathologico-physiological studies are pursued by special investigators, and would perhaps more properly be brought before a society of specialists than before this Society, which has more general interests. Perhaps, indeed, this particular aspect

of the science is better understood by physiologists. Moreover, it is in these subjects, less easy to carry out the general principle of the Society that communications shall be accompanied by some material evidence or demonstration. It is better, I think, that we should chiefly confine ourselves to a subject wide enough to absorb all our interest, namely, the study of structural or anatomical medicine in its most general sense.

I have now touched upon the main objects which our Society has had in view, and which it ought still, I think, to pursue. Our communications and our methods more refined have in recent years become more elaborate than they formerly were, but, in the main, our objects are the same as they always have been.

At the present time it seems as if there were two courses open to the Society. It might develop into a Society composed only of those engaged in special pathological research. In this case we should have some communications which would not be interesting, or perhaps intelligible, to many of our present members. Hence the numbers of the Society would dwindle, even supposing that the average work were of higher quality.

It may, on the other hand, continue in its present course of bringing the results of pathological research into relation with practical medicine, and stating them so as to be intelligible to all who take an interest in pathology, even if they are unable themselves to take part in original research.

For my own part I hope that this will be the course adopted. Pathology ought not to lose touch of practical medicine. It can both aid and profit by the daily experience of those who are carrying on the great practical work of our profession. It would be a loss rather than a gain were pathology to live like a cloistered recluse, in laboratories and museums, not breathing the common air of the whole medical world. Specialism in science there must be, for it is only one form of the division of labour on which all progress depends; and experiment there must be, for an experiment may save a thousand lives where a prescription or an operation saves only one. But a concrete and practical science like pathology could not flourish if cut off from the everyday experience of disease.

We can, indeed, conceive that there might be, and to some extent there already is, a science of disease, as a branch of biology with-

out any direct relation to the art of healing. But such a science, if not recognising the great ethical principle of our profession to relieve human suffering and minister to the welfare of mankind, would lose its mainspring of action. It is, at all events, not such a science of pathology that we cultivate here. Our science is one which is always ready to come at need to the aid of those engaged in the keen and perpetual conflict with our one enemy, disease.

October 19*th*, 1897.

Postscript.—The circular which follows is appended as indicating the original aims and principles of the Society.

[*Copy of circular relating to the meeting at which the Pathological Society was founded, presented by* SIR S. WILKS, Bart., F.R.S.]

35, TRINITY SQUARE,
SOUTHWARK.

SIR,

I have the honour to inform you, that at a preliminary Meeting of several Professional Gentlemen,

DR. BARLOW IN THE CHAIR,

it was resolved that a PATHOLOGICAL SOCIETY be formed.

It was proposed that it be founded upon the following principles :—

1st.—That all Communications and Discussions be confined to strictly Pathological subjects.

2ndly.—That such Subjects, whenever practicable, be illustrated by Drawings, Microscopic Preparations, and recent Morbid Specimens.

I am requested to ascertain whether the formation of a Society having these objects will meet with your approbation and support, and to ask the favor of an early reply, in order that measures may be immediately taken to carry the same into effect.

I am, Sir,

Your obedient servant,

EDWARD BENTLEY, M.D.
HON. SECRETARY (*pro tem.*)

February, 1846.

REPORT.

SESSION 1897–1898.

I. DISEASES OF THE NERVOUS SYSTEM.

1. *Hæmatoma of dura mater.* (*Card specimen.*)

By Cecil F. Beadles.

On the inner surface of this dura mater, covering both cerebral hemispheres, is an exceedingly thin bright red blood-clot with a gelatinous deposit spread over it. The latter for the most part is clear and colourless like white of egg, though in a few places it has a semi-opaque ground-glass appearance. This adventitious structure can be readily peeled off the true dura, and even separated by holding beneath a strong stream of water.

After immersion of the membrane for a few hours in 2 per cent. formalin solution, the gelatinous material contracted and solidified and became more generally opaque.

Such gelatinous material deposited in the meshes of the pia arachnoid is by no means rare in persons dying insane, being found in some cases of general paralysis, but most frequently in old cases of dementia or chronic mania, but such a deposit spread over the dura mater is anything but common. In some 500 autopsies in Colney Hatch Asylum I have seen no identical condition; on the other hand, a form of false membrane associated with the dura is well known to be fairly common in lunatics.

In these there is a distinct layer or layers of fibrous-like tissue, more or less intimately blended with the outer covering of the brain. Sometimes these appear unmistakably to have originated

from organised blood-clot; others do not show this in any decided way. All such membranes are usually classed as hæmatoma of the dura mater, on the origin of which different opinions are still held. It seems to me highly probable that the specimen exhibited reveals to us the manner in which some of these originate. There has been a slow exudation from the smaller vessels of the membrane coagulated on the surface; at present it is in an earlier stage than is usually found, but this would, if the patient had lived some months longer, have passed into a more organised form of tissue.

The case is interesting, too, on account of the nature of the mental state from which the patient suffered. Advanced changes in the brain and membranes are quite exceptional in melancholia, even when chronic. There was also a remarkably small heart, presumably a congenital condition.

From a female aged 45, who was melancholic for ten years. The last two years of her life she presented evidence of phthisis. She was a poor, weak, miserable-looking little woman with angular curvature of the spine, always fretting and crying, and constantly asking that she might not be killed. She kept to her bed only a few weeks, but for months lay the greater part of the day on a couch, from which she rarely moved. She had no form of fit or paralysis.

Besides the condition of the dura mater that has been described, it may be mentioned that the brain was small and shrunken, much hardened, the finer membranes patchy, with opacity over both hemispheres, but with no gelatinous deposit and no evidence of tubercular meningitis. The heart weighed only 4½ oz. There was slight puckering of the mitral flaps and a little atheroma of the aorta. Kidneys large and fatty. Upper lobes of both lungs consolidated by old tubercle, the left being more extensive, with small cavities filled with purulent matter; both adherent.

December 7th, 1897.

2. *A brain with three subsequent hæmorrhages; a heart (from the same case) showing a well-developed musculus papillaris (or musculus chordæ tendineæ) on the mitral valve.*

By L. Freyberger, M.D.

Mrs. P—, 43 years old, housewife, was admitted to the Great Northern Central Hospital on February 14th, 1898, under the care of Dr. Clifford Beale.

(*a*) She had always been very well until the 20th of December, 1897, when she suddenly complained of violent headache, and soon afterwards fainted away; there was violent twitching of the right side of her face, and of both arms. She was unconscious for two hours, but the headache and a feeling of general weakness lasted for three days. There was no paralysis. The medical man under whose treatment she was at the time found a considerable quantity of albumen in her urine. Six days after this attack the albumen had disappeared from the urine, and the doctor allowed her to get up, as she said she felt very much better.

(*b*) On February 7th, that is fifty-three days after the first attack, she again complained of severe headache, was sick several times, and for a few hours afterwards had violent convulsions of the muscles of the right side of her face and body, in the course of which her tongue was bitten through, but there was no loss of consciousness. Again there was no paralysis, but since this last attack patient remained delirious, and kept screaming and shouting all day long.

Both her parents and a brother had died of renal disease.

In the hospital she lay comfortably in bed and complained of no pain. She kept continually talking and rambling, but when questioned gave sensible answers. Her vision was evidently defective; she could not distinguish how many fingers were held up in front of her eyes. Her pulse was regular and had a high tension. The heart apex beat in the fifth space through the nipple line, and was heaving in character; the area of cardiac dulness extended from the third to the sixth ribs, and from the left sternal margin to the nipple line. There was a loud systolic

murmur at the apex, and a ringing second aortic sound. The lungs were healthy. The urine, specific gravity 1015, showed a cloud of albumen on boiling, but it did not contain sugar or blood; no amorphous deposit.

There was no paralysis of the muscles of the face, trunk, or limbs.

The outlines of the optic discs were much blurred and slightly œdematous; there were no hæmorrhages in them.

The patient remained in very much the same condition, and neither her eyesight nor her mental confusion showed the slightest change.

Her temperature, which had always been subnormal, rose on one occasion to 101°, but nothing was found to account for it.

(*c*) On March 17th (thirty-eight days after the second attack), at 1.20 p.m., the patient, while having dinner sitting up in bed, fell suddenly out of the bed and struck her head on the floor. She was not unconscious, but did not seem able to move. She said she felt giddy and fell out of bed. It was noticed that the left side of her face did not move when she spoke. At 1.50 p.m. her face suddenly became extremely pale and cyanotic about the lips. She soon became unconscious. Her left pupil was contracted, the left angle of the mouth and the left lower eyelid dropped. There was complete paralysis of her left arm and leg; the right arm and leg kept moving; the knee-jerks were exaggerated on both sides; there was ankle-clonus on the right side.

Death occurred at 10 o'clock p.m. on the same day.

At the post-mortem examination, seventeen hours after death, the bones of the cranium were found much thickened and of the consistence of ivory; the dura mater thickened and very hyperæmic; the basal arteries highly atheromatous, the convolutions of both convexities flattened, and there was fluctuation beneath both parietal lobes. On section, the puncta cruenta well marked, the white and the grey matter somewhat pink, the lateral ventricles dilated and filled with sanguinolent fluid.

In the left occipito-temporal lobe near the calcar avis there is a blood-clot of the size and shape of a small Tangerine orange; the clot is gelatinous and greyish brown in colour. In the right temporal lobe, in a place almost identical with that on the left side, there is a clot the size of a cobnut, dry and firm in consistence, and amber-coloured. Immediately in front, and separated from this

clot by a bridge of brain substance not more than ⅛ inch in thickness, is a third hæmorrhage, which destroyed the right internal capsule, part of the optic thalamus and caudate nucleus, and the greater portion of the lenticular nucleus. The clot has the appearance of black currant jelly, is soft, and contains a considerable quantity of dark fluid blood. It weighs 3½ ounces.

The lungs are œdematous, but are otherwise natural.

The heart is large, the right ventricle flabby, the left contracted. On section the wall of the left ventricle is found very firm and much hypertrophied, and the cavity of the ventricle larger than usual; from the apex of the lateral papillary muscle a cone-shaped muscle is seen to arise, measuring nearly ⅗ inch in length and ¼ inch in thickness at the base, the apex of which muscle is inserted into the ventricular aspect of the aortic cusp of the mitral valve, near its posterior edge.

[This continuation, as it were, of the papillary muscle right on to the mitral valve is somewhat rare, and represents a condition present during early fœtal life, when a spongework of muscular trabeculæ fills the space between the ventricular wall and the primary atrio-ventricular valve.]

The liver is large and firm; the gall-bladder empty; the spleen small. Both kidneys are small and granular; the genital organs natural.

The points of interest in this case are—

1. A distinct history of three separate cerebral hæmorrhages, of which the first, into the right temporal lobe, produced unconsciousness and convulsions, but no paralysis; the second, into the occipital lobe, fifty-three days after the first, hemianopia and dementia, but again no paralysis; the third, into the internal capsule thirty-eight days after the second hæmorrhage, proved rapidly fatal, but death was preceded by left-sided hemiplegia.

2. The relative size of the clots produced by hæmorrhages 1 and 2.

3. The large size of the clot produced by hæmorrhage 3.

4. The subsequent changes which have taken place in these blood-clots.

Clot I, the oldest, is reduced in size, dry and dark yellow. The brain substance round it is stained a lighter yellow.

Clot II is still somewhat gelatinous, dark brown, but with a distinct admixture of grey; it is somewhat adherent to the brain substance round it.

Clot III is quite recent, soft, dark purple, and does not at all adhere to the brain substance.

April 19*th*, 1898.

---

3. *Tumour of the spinal cord.*

By H. Morley Fletcher, M.D.

This specimen was taken from the body of a carpenter aged 55, who was admitted in January, 1898, to St. Bartholomew's Hospital, under the care of Dr. Gee.

In October, 1896, fifteen months before admission, he suffered from pain and weakness in the *right* knee, which he thought at the time was rheumatism. There was no history of injury.

In December, 1897, the *left* knee became similarly affected, and he had to leave his work and take to his bed. A fortnight before admission he had difficulty in micturition. At no time had he pains in the back. There was a history of gonorrhœa and syphilis; he had been married thirty-two years, and had seven living, healthy children.

The chief points of interest, taken from the clinical notes by Dr. Horder, are as follow:

He was a healthy-looking man with no general wasting. There was loss of power in both legs, more on the left than the right side. There was left foot-drop. The muscles of both legs were flabby, and there was some glossiness of the skin of the left leg and foot. Both knee-jerks were absent. The plantar reflexes were present, though sluggish on the left side. Sensation was impaired over both legs and trunk as high as the upper edge of the sacrum and the anterior superior spine, but was nowhere completely absent.

Faradic irritability was absent in the left anterior tibial and peroneal muscles, and diminished in the same muscles of the right leg. There was no tenderness on pressure over the spine. The temperature was normal.

Dr. Gee's diagnosis was a tumour involving the lumbar enlargement of the cord.

The patient was in the hospital for four weeks, during which the pains and weakness in the legs rapidly increased, and cystitis supervened.

On February 17th he had a sudden attack of acute abdominal pain, attended by symptoms of great collapse. There was marked pallor, and the pulse became imperceptible. The pain lasted about two hours, and then the patient died. The termination was so unusually sudden that it was suggested that it might be due to an abdominal aneurysm which had ruptured into the retro-peritoneal tissues. The total duration of symptoms was *sixteen months*. I have to thank Dr. Gee for his kind permission to use the notes on the case.

The *post-mortem* examination was made by Dr. Garrod eighteen hours after death, and nothing of interest was found beyond the tumour which I now show. There were no other growths in any organ. There is an oval nodulated tumour 1½ inches long in the lumbar enlargement. It had a slightly translucent appearance when freshly removed. Its upper limit is just below the twelfth dorsal nerve-root. It lies on the posterior surface of the cord, extending round on both sides, but does not involve the anterior surface, which is seen to be quite unaffected. It is firmly attached to the cord in its central part, but the outer portions of the growth appear to be less firmly attached. The tumour is thicker on the right than on the left side, and the root of the twelfth dorsal nerve is much involved. There is an extension of the growth at its lower part, forming a ridged, varicose thickening on each side of the posterior surface. A complete transverse section of the tumour and cord was made through its thickest portion, and a piece about the thickness of a shilling was removed for microscopical examination. Sections of this piece show that the growth appears to have started in the posterior half of the cord close to the central canal, though it is difficult to decide the precise region. It has destroyed the posterior cornua, and has grown round to envelop half the cord. The anterior cornua and columns are not invaded, though they are considerably altered as the result of pressure.

The growth itself is a glio-sarcoma; it contains spindle, oval, and round cells. There are a few large mononucleated cells, possibly degenerate nerve-cells, with here and there some large polynucleated cells. There are numerous corpora amylacea. In the

outer portion of the growth there is seen a considerable number of small branched cells with delicate fibrillæ resembling neuroglia cells. Sections of the upper regions of the cord show secondary degeneration in Goll's column, which is chiefly confined to the posterior part of this tract.

Primary malignant tumours *within* the cord are of considerable rarity. Very few cases have been shown before this Society. I have only been able to find three, and the histological characters of two of these (shown by Sir S. Wilkes and Sir Risdon Bennett) are not quite clear, one being probably a fibro-sarcoma, and the other a glioma. The third, shown by Dr. Herringham and Mr. Power, was a round-celled sarcoma associated with similar growths in the brain. Dr. Hughes Bennett showed a round-celled sarcoma of the cord at the Clinical Society, in which the growth was dotted along the cord, membranes, and posterior nerve-roots. Of growths occurring within the spinal cord glioma is the commonest, glio-sarcoma the next, and pure sarcoma by far the rarest. I find in von Ziemmsen's 'Encyclopædia' the statement that Virchow had never met with an instance of pure sarcoma of the cord.

It is interesting to note in the cases of intra-spinal growths I have been able to find in this country and abroad, how frequently there is a history of a blow or fall on the back, and this is especially so with the younger patients.

The age of this patient is considerably above that of any other case of primary intra-spinal malignant tumour which I have found. The other points of clinical interest were the complete absence of pain in the back, and the extremely sudden termination with symptoms of profound collapse.

May 17th, 1898.

---

4. *An unusual case of spina bifida.*

By R. Henslowe Wellington.

The specimen consists of the lower end of the spinal column, with the sacrum and right os innominatum. The sacrum is so twisted that its anterior surface looks directly to the right, and its

apex almost touches the right ischium in the site of the ischial spine. On the back of the spine there is an oval aperture, due to non-closure of the lower lumbar and sacral arches (spina bifida). Through this protrudes the pedicle of a large cystic tumour. On laying open the tumour it is found to be unilocular, and its wall is made up of skin and dura mater. Projecting into the cavity of this main cyst is a much smaller secondary cyst, which is due to dilatation of the lower end of the arachnoid sac. Owing to the torsion of the sacrum and spinal column the sac of the spina bifida rests on the back of the right ilium, and this forms a prominence on the right buttock.

June 10th, 1893, I attended Mrs. L—, aged about 32, in her first confinement, which lasted about twenty-four hours. She was a tall, big, heavy, fair-complexioned woman—so much fat that it made it difficult to get the forceps adjusted. *Presentation* of child was in first position, vertex. *Delivery* was easy with forceps as far as the lumbar region, then it required great force to obtain the buttocks. Mother did well. Child presented curious appearance, with a large cystic tumour 10″ × 4″, oval in shape, lying along the right gluteal region, not in the middle line, the upper border of tumour coursing along the crest of ilium by hard and fast line, the attachment not extending beyond it. The inner boundary extended up to the middle line. Child appeared otherwise healthy, normal, and fairly strong, but did not take nourishment readily. About a week after birth the cyst appeared so tight, and had increased so much in size, that I aspirated, drawing off ten ounces of clear straw-coloured fluid, like hydrocele fluid. On the collapsing of the cyst I felt a tense rounded tumour inside. I withdrew my cannula, but the cyst filled again in less than twenty-four hours, when I again drew off about ten ounces of the same kind of fluid. Before withdrawing the cannula I re-inserted the trocar and passed it on into the inner cyst, this time tapping clear cerebro-spinal fluid from a true spina bifida, proved by depression at anterior fontanelle and convulsive movements of the child. I decided to leave the case alone, as the child now refused all nourishment. It died about three weeks from birth.

Post-mortem.—With difficulty I obtained a *post-mortem.* The specimen was removed by dislocating the two femora and cutting through the spine with bone forceps.

The liver had an extra lobe, and the gall-bladder was situated low down in the pelvis anterior to the urinary bladder.

21*st December*, 1897.

Report of the Morbid Growths Committee on Mr. Wellington's specimen of spina bifida.—We have carefully examined the specimen of spina bifida referred to us, and confirm the foregoing description, to which, however, we may add the following:

The deeper or inner sac presents interiorly the usual characters of a meningo-myelocele, *i. e.* from its posterior wall there arise the roots of the lower spinal nerves, which anteriorly perforate the dura mater, and afterwards pursue their normal course.

The unusual feature of the specimen consists in the separation of the dura mater from the arachnoid by a second collection of fluid.

There is no communication between the two sacs, and we have, for this reason, no hesitation in adopting the conclusions drawn by the author from the clinical aspect of the case.

J. H. Targett.
Samuel G. Shattock, *Chairman.*

---

5. *Specimens of nerves from a case of chronic traumatic neuritis.*

By Walter G. Spencer.

The microscopic specimens shown are longitudinal sections of nerves dissected out from an amputated leg. It can be seen that in comparison with normal nerves they are infiltrated by leucocytes, and that many degenerated fibres have been replaced by fibrous tissue. The muscle of the limb was wasted, but not more than disuse would account for. There was no other lesion.

The patient was a married woman, now aged 43, accustomed to house and garden work, who until the accident had always been in good health. Neither before nor since the accident has there existed any other cause for the neuritis. Four and a half years before the amputation she slipped off a chair and injured her left

foot and ankle. She was attended by Drs. Ferris, Davidson, and Francis of Uxbridge, who found marked swelling and bruising of the lower part of the leg and ankle, but no positive evidence of a fracture. As the nature of the accident was doubtful she was treated for a fractured fibula. After the swelling had subsided the patient could not put the foot to the ground for pain. I first saw her nine months after the accident. She complained of pain, which was so great at night that she could not sleep; the least touch even of the bedclothes caused pain. There occurred also patches of transient œdema. Nothing positive could be made out as to the cause of the pain; even under an anæsthetic there was no deformity nor adhesions. Massage and passive motion gave the patient pain, and did no good. The foot and leg were put in plaster, and she got about on a kneeling-pin. A year afterwards the patient again came into the hospital with constant hyperæsthesia and pain, attended intermittently by œdema. The worst pain was under the heel, and after observing her for some months I excised the os calcis. I did so with some misgivings, but the patient declared that the pain was relieved. Four and a half years after the accident she returned with ulceration and necrosis of the toes, beyond which was a dusky red zone, and marked œdema, especially of the dorsum of the foot. The pain had spread up the leg to the external popliteal, especially felt when the nerve was pressed against the fibula. The hyperæsthesia and pain about the ankle had also become worse.

It was now evident that the case was one of spreading chronic neuritis, and that ulceration and necrosis would gradually extend to the foot. I thereupon amputated through the knee-joint by Stephen Smith's method, so that the patient might be able to use the same pin as before, and bear weight upon the comparatively insensitive skin in front of the knee. It would clearly have been useless to amputate lower down, not only because of the hyperæsthesia existing in the leg, but the leg also had become permanently flexed by the prolonged use of the kneeling-pin. The stump healed by first intention, and the patient has been getting about on it, and complains of pain referred to the amputated leg and foot.

The case is of interest, for until more than four years after the accident, when the ulceration and necrosis of the toes commenced, there was no certain sign of an organic lesion. Since the accident the woman has developed many nervous and hysterical symptoms of

a general character, and these, taking into consideration her age as approaching the climacteric, would undoubtedly favour the idea that the whole complaint was a neurosis. It is further of importance pathologically as exhibiting a very chronic spreading traumatic neuritis arising from a purely subcutaneous injury, in the absence of any of the recognised causes of peripheral neuritis.

November 2nd, 1897.

II. DISEASES, ETC., OF THE ORGANS OF RESPIRATION.

1. *Laminated fibrous nodules on pleura.*

By Cecil F. Beadles.

A portion of lung is shown which presents a condition of the pleura that I believe to be rare, although a similar condition on the capsule of the spleen is one of the commoner incidental lesions met with after death. The lesion referred to consists of the presence of a number of small raised nodules and white flattened masses of cartilaginous hardness on the surface of the organ, which on microscopical examination are found composed of a laminated fibrous structure.

The origin of these nodules and plaques does not appear to be known. I have seen it suggested that they may be of syphilitic origin, but I believe there is no clear evidence on that point. I remember reading some years ago that thickenings on the splenic capsule are common in persons who had malarial diseases, but do not remember what explanation was adduced. It may have been suggested that it resulted from the shrinking that followed a stretching of the capsule, which must necessarily accompany a distension of the organ. Such an explanation seems to me on the whole the most feasible, especially when we associate together the two facts that the spleen is almost solely affected in this way, and it is an organ in which we have a soft pulpy tissue confined in a fibrous sac, rapidly and constantly enlarging and decreasing in size.

That something more than mere cicatricial shrinking is necessary is evident from the rarity of the condition at the apex of the lung, where puckering on the pleura is so constantly seen, generally held to be evidence of old or pre-existing tubercle, but here

there has been no marked previous distension. This thickening is due to a simple increase in the fibrous tissue of the serous covering of the lung, associated sometimes with the deposit of calcareous matter amongst the fibrous bundles. The specimen exhibited is not a simple case of this kind, for here we have distinct raised nodules presenting both to the naked eye and microscopically a structure similar to those found on the spleen. I do not remember to have seen another instance of this.

The apices of both lungs were affected, but the left to the greater extent. Spread over an area of 1½ square inches are some twoscore of round raised nodules projecting from the surface of the pleura, few of which reach much beyond the size of a large pin's head. They are of an opaque white colour, and cannot be peeled off. There were no pleuritic adhesions. The right apex was adherent; there was a patch of opaque thickening on the pleura, and two or three small nodules in its vicinity. Both lungs were congested, the right most so; neither contained any trace of tubercle.

Sections made through the pleura and nodules show that the former is thickened by a layer of tissue on its exterior, which resembles in its structure that of organised lymph becoming converted into connective tissue, but a considerable part of it remains of an amorphous structureless nature. The nodule is formed by a heaping up of homogeneous tissue arranged in bands one over the other, and blending at the edges of the nodule with the false membrane above referred to. There is an absence of nuclei and of new blood-vessels throughout the raised areas, except for a few capillary slit-like spaces with nucleated cells between some of the laminæ. In the true tissue of the pleura, which is also thickened beneath the centre of these adventitious masses, there are in a number of cases small areas of calcareous degeneration.

The heart was hypertrophied, the myocardium of the left ventricle was distinctly fibrous in places; slight thickening of the mitral flaps, and early atheromatous change in the interior of the aortic arch. Spleen small, weighing only 1¾ ounces, its capsule not affected. Both kidneys a little reduced in size, with capsules adherent and surfaces granular. Brain slightly wasted, œdematous, great excess of cerebro-spinal fluid, pia arachnoid a little thickened, vessels at base in an advanced stage of atheroma.

From a female lunatic aged 75, who died with senile melancholia

of a few months' duration. Most of the time she lay in a state of stupor without speaking, and always had to be fed. A sister was insane.

November 16th, 1897.

---

2. *Primary myxo-sarcoma of the pleura.*

By Percy Kidd, M.D., and S. H. Habershon, M.D.

The patient, L. G—, a girl aged 18½ years, was admitted into the Brompton Hospital on September 1st, 1897, suffering from pain on the left side and dyspnœa.

The history was that from the age of thirteen to fifteen she had been anæmic.

In October, 1895, she was laid up for five weeks with pleurisy, but which side was affected was uncertain. Since this attack she had never been well, and had been troubled with more or less cough.

The present illness began suddenly with severe pain on the left side and dyspnœa about a month before admission, but she was not confined to bed.

On admission there were signs of a large effusion into the left pleura, the heart being displaced to the right of the sternum. But at first it was noted that although the dulness in front extended from apex to base, posteriorly the dulness did not reach higher than the middle of the scapula. By degrees the dulness behind extended up to the summit of the thorax, and the heart became further displaced to the mid-axillary line, and at the same time the dulness above the heart reached into the right half of the thorax as far as the mid-clavicular line. No enlarged glands could be detected, and the laryngoscope showed that there was no paralysis of the vocal cords. The temperature once reached 102°, but for the most part it did not exceed 100°. Paracentesis was performed on four occasions, but nothing more than a little fluid blood was obtained. Dyspnœa and exhaustion gradually increased, and the patient died on October 29th, 1897, about three months after the onset of her illness.

Autopsy (summary).—On removing the sternum an enormous mass was seen filling the left chest, and extending into the right side as far as the mid-clavicular line, the heart lying entirely to the right of the sternum. The pleural cavity was almost completely obliterated by soft spongy adhesions. The left lung was displaced backwards, and was entirely hidden.

When the mass was removed it was seen to consist of a soft and somewhat lobulated growth, which was loosely attached to the anterior surface of the left upper lobe, and seemed to be more firmly adherent to the lateral aspect of the lower lobe. The whole tumour was covered with a thin pleura-like membrane, and on section it consisted of a coarse fibrous network enclosing large blood-cysts, cystic spaces containing viscid puriform material, and towards the sternal border a few soft yellowish-white masses of growth. The blood-cysts, which were the predominant feature, contained fluid and coagulated blood, as much as two pints of blood escaping from two or three punctures.

The left lung was completely collapsed, grey and carnified.

The right lung was partially collapsed.

Both lungs were free from any other change. The bronchial and mediastinal glands were not enlarged or altered in any way.

The liver, spleen, and kidneys presented the appearances of chronic congestion, but there was no other disease of any organ.

The softened puriform matter from the growth proved on microscopic examination to consist almost entirely of stellate and pyriform cells, with here and there a few ordinary granular pus cells.

Sections of different parts of the tumour show various appearances.

Some consist mainly of a coarse fibrinous network enclosing red blood-corpuscles in its meshes, and many large thin-walled vessels filled with blood.

In its more solid parts the growth is composed of closely packed round-cells, with very scanty stroma, resembling a round-celled sarcoma. Many of the individual cells contain clear rounded vesicular spaces or drops, apparently the result of mucoid degeneration.

In other parts the structure consists of branching cells more or less widely separated from one another, many of them containing clear mucoid drops.

The growth seems to be best described as a myxo-sarcoma.

The extraordinary number of blood-cysts is probably related to the markedly angiomatous character of the growth.

The rarity of primary tumours of the pleura need not be insisted upon.

It is suggested that the growth sprang from the subserous tissue in the neighbourhood of the root of the lung.

From the clinical side attention may be drawn to the very great displacement of the heart, which, as far as our experience goes, is most uncommon. In fact, the extreme dislocation of the heart seemed to warrant the conviction that we had to deal with a pleural effusion as well as a growth, in spite of the negative results of paracentesis.

April 5th, 1898.

---

3. *Primary sarcoma of the left lung simulating empyema and producing great contraction of the affected side.*

By S. H. Habershon, M.D.

From its clinical aspect this case is one of importance, because it is always a point of some difficulty to determine how far contraction of the side is compatible with the presence of a malignant growth.

The specimen is from an old man, B. B—, aged 78, who was admitted to the Brompton Hospital on October 2nd, 1897, under my care in the absence of my colleague, Dr. Kidd.

The disease began insidiously with cough and difficult expectoration some few months before he came under observation. For two months there had been a difficulty in swallowing food, which was said to return immediately after taking it. Increasing dyspnœa and weakness, with the inability to take food, were the immediate symptoms.

Previous to admission physical signs of fluid in the left pleural cavity had gradually appeared, and paracentesis of the chest had produced a small quantity of pus. Dr. Dodwell, under whose charge

the case was, had at this time considered the probability of malignant disease of lung or pleura.

On admission the patient presented all the signs of pleural effusion of the left side, but, instead of prominence or bulging, the side was considerably smaller than the right side of the chest. The right lung extended as far as two fingers' breadth to the left of the sternal margin, and the apex of the heart was felt in the fifth intercostal space in the left anterior axillary line. In the region of the apex beat a to-and-fro friction sound synchronous with the heart-sounds could be heard. This physical sign raised the question of whether any fluid could be present in the pleural cavity, and the anomalous digestive symptoms made the diagnosis of malignant disease of lung extremely probable.

On October 9th Mr. Godlee aspirated the left side of the chest, and about half a drachm of thick pus was drawn off. He considered that the pus came from a cavity in the lung. The temperature was of a hectic type, rarely rising above 101° at night.

No further operative measures were deemed advisable, especially in view of the feebleness of the patient. Death occurred on October 26th.

At the autopsy the body was found to be fairly nourished, and with a considerable coating of subcutaneous fat. The left pleural cavity was obliterated, and the pleura thickened. Over the upper third of the lung a fatty deposit nearly half an inch in thickness was found between the thickened visceral and costal layers of pleura. The left lung and side were contracted, and the heart and pericardium drawn to the left. The right pleura was healthy. The œsophagus was healthy to a point immediately below the bifurcation of the trachea. Here there was a long oval perforation to the extent of 1½ inches on the left anterior wall, leading to a large ulcerated sinus overlying but not communicating with the left bronchus. Its direction was downwards towards a softened mass at the root of the left lung.

Around the perforation of the œsophagus and infiltrating the surrounding walls for a distance of one third of an inch was a flattened shallow growth underlying the mucous membrane, soft but not ulcerated. The left bronchus was surrounded by new growth, commencing just below the tracheal bifurcation, thickening its walls, and constricting the lumen immediately above the main bronchus to the left upper lobe. This growth of bronchial wall was about

¼ inch in thickness, and on the posterior surface of the bronchus was softened and sloughing, and formed the floor of the ulcerated tract seen through the perforation of the œsophagus from behind. The infiltrated tissues were adherent above to the lower part of the arch of the aorta, thickening but not penetrating its wall.

A section of the left lung revealed the following appearances. The lung was contracted and the pleura generally thickened. The upper lobe was condensed, extremely firm, deeply pigmented, and in the recent state marbled somewhat after the manner of steatite. In places there were pale lobulated areas separated by pigmented lung. Both appearance and microscopic section were suggestive of chronic fibroid change. Many of the smaller bronchi were dilated. The chief disease was in the lower lobe, the root and central portions of which were occupied by a large circumscribed mass of the size of a fœtal head, irregularly globular in shape, and occupying the upper two thirds of the lobe, extending as far as the septum except at the posterior part of the apex, where the growth was separated from the surface by a layer of pigmented and condensed lung of some ½ to ¾ inch in thickness. The mass approached the surface of the lung only at the posterior part of the root, where it had ulcerated into the œsophagus. This large new growth was entirely in a softened sloughing condition, with a large ragged cavity in its centre, but without fœtor. Around its edge the colour was of a pale yellow, deeply mottled with grey pigment, but entirely friable and soft. The base of the lobe was unusually pigmented, and firmer than usual.

There were no secondary growths discovered in any organ. The mediastinal glands were deeply pigmented, but not enlarged. The heart was large and flabby, and there were some atheromatous patches in the thoracic aorta. With these exceptions, other organs were healthy.

The microscopic examination of portions of the growth shows an extensive large round-celled infiltration with a few spindle cells without stroma and without any sign of alveolar arrangement. The general type is that of a sarcoma.

The growth is intersected in places with ill-defined trabeculæ of fibrous tissue containing elongated nuclei, and scattered irregularly throughout are areas in which the cells are indistinctly stained and apparently undergoing necrosis.

It is difficult to exclude the origin of this growth from a bronchial

gland, but the absence of visible enlargement of the glands in the fork of the trachea or elsewhere seems to render it probable that the new growth originates in the lung.

April 5th, 1898.

---

4. *Nose and lung from a case of glanders.*

By James Berry, B.S.

John H—, a painter, aged 37, was admitted into St. Bartholomew's Hospital, under the care of Mr. Howard Marsh, on October 26th, 1897, suffering from tertiary syphilis affecting chiefly the throat and face. He had also a recent acute inflammation of the skin of the face. He was very ill and rapidly grew worse, the inflammation of the face spread quickly, and patches of gangrene appeared about the forehead and nose. The temperature varied between 101° and 103°. Two days after admission a profuse discharge of mucus from the nose was first noticed, and on the fourth day he died.

Sixteen years previously he had contracted syphilis and he had been under treatment for this in several hospitals. Ten days before admission the left eyelid began to swell, and it was chiefly on account of this that he came to the hospital. He had not, so far as could be ascertained, been in contact with glandered horses; nor did his occupation, that of painting coffins, throw any light upon the source of his infection.

The *post-mortem* examination showed the following condition:

External appearances.—The face was horribly disfigured by numerous blotches, scabs and areas of ulceration. The nose and large portions of the upper lip and cheeks were covered with thick scabs, upon the removal of which superficial ulceration of the skin was seen. Over the right malar bone was a circular black slough an inch in diameter, surrounded by a hard, raised, reddish-purple ring of infiltrated skin and subcutaneous tissue, about a quarter of an inch wide, and resembling the chronic infiltrating lesions of tertiary syphilis. On the left side of the forehead was a larger

patch of similar nature. There was a complete absence of any old scarring and of any deeply cut ulceration about the face. The *eyes* showed no signs of disease.

In various parts of the body, but chiefly in front of the right shoulder and left knee, were scattered, raised, firm, reddish-yellow nodules about a quarter of an inch in diameter. They were situated in the skin and subcutaneous tissue, and were not suppurating.

Internal appearances.—Mouth.—In the anterior part of the *hard palate* was some shallow and rather foul ulceration. The *soft palate* showed puckering and scarring, apparently from old destructive syphilitic disease, unconnected with the recent ulceration.

The *teeth, gums,* and *tongue* showed no disease.

Nose.—Both nostrils contained much foul mucus. The mucous membrane of all parts of both nostrils was much thickened and inflamed, and in places superficially ulcerated. In many parts, especially in the septum, were numerous small bright yellow submucous tubercles about as large as millet seeds. At the posterior and lower part of the septum was an oval perforation in which lay a thin plate of necrosed vomer, not yet separated. This necrosis was apparently quite recent; there was no evidence of any old disease about the interior of the nose.

The *larynx* showed shallow ulceration and pitting about that part of it that lay above the true cords. There was no extensive destruction and no scarring.

The *trachea* was much congested, but not ulcerated.

The *heart* and *pericardium* were normal.

The *pleuræ* showed slight injection of various parts, and on the parietal pleura near the middle of the seventh right rib was a patch of bright yellow deposit, about a quarter of an inch in diameter, similar to those on the septum of the nose.

The *lungs* were both intensely engorged and showed numerous disseminated glanders tubercles. Both lungs were in an exactly similar condition. Each contained numerous raised, rounded, firm, yellow patches varying in diameter from a sixth to a third of an inch; most of them were on the surface, but some were deeply seated in the substance of the lungs. At first sight they looked like ordinary pyæmic abscesses, but they were much harder, and when cut into were found to be solid throughout.

The *spleen* contained a single yellow nodule similar to those in the lungs.

The *liver, stomach, intestines, kidneys,* and *bladder* showed no signs of disease.

It was suspected at the time of the *post-mortem* examination that the case was one of glanders, although some of the lesions found were obviously due to syphilis. The following account of the bacteriological examination made by my colleague Dr. Andrewes left no room for doubt.[1]

December 7th, 1897.

---

5. *Section of glanders nodule in human lung, stained with Löffler's methylene blue, and showing a few bacilli.* (*Card specimen.*)

By F. W. Andrewes, M.D.

Under $\frac{1}{12}$ inch oil immersion.

The bacilli are scanty in numbers, but three or four can be seen in the field, and are characteristic enough. They are found in this specimen only in the central part of the nodule, where the polynuclear leucocytes are most densely crowded.

Cultures on potato were typical.

December 7th, 1897.

---

6. *Ulceration of a caseous bronchial gland into the bronchus; fatal asphyxia.*

By Arthur Voelcker, M.D.

The specimen was obtained from a girl, aged 5 years, who was left apparently in good health by her mother in a room, on the floor of which she was found dead some twenty minutes later. At the *post-mortem* examination there was no external evidence of

[1] The septum of the nose and part of one lung are preserved in the Museum of St. Bartholomew's Hospital.

injury, the body was well nourished, and there was no obvious cyanosis. The brain showed nothing abnormal beyond slight congestion. The heart was firmly contracted, the heart muscle and valves healthy, and there were no subserous ecchymoses. The lungs were markedly distended with air except for a patch of collapse in the right upper lobe. There was no interstitial emphysema. The tonsils were large but free from exudation. On looking into the glottis, the aperture was seen to be blocked by a whitish yellow mass. On displacing this with a probe, air rushed out with a hissing sound and the lungs began to collapse, though when the probe was removed the mass effectually prevented any further escape of air. On opening up the trachea, the larynx below the cords was found to be blocked with a caseous mass about half an inch long which lay just below the vocal cords. The right bronchus at its lower part and just at its origin was perforated by an opening half an inch long through which some caseous material and some connective tissue (gland capsule) projected. The bronchial glands on both sides, but more so on the right side, were enlarged and caseous, and some were softening, and the tracheal glands were in a similar condition. There was a little caseous material in the trachea. The other viscera showed nothing abnormal.

The occurrence of ulceration of the air passages as the result of the presence of caseous bronchial or tracheal glands has been long known, and is mentioned by Laennec in his 'Treatise on the Diseases of the Chest,' and several instances have been brought before this and other societies. In 1891 Mr. R. W. Parker read before the Clinical Society an interesting paper, and showed the specimen from a case in which sudden dyspnœa, followed, in spite of tracheotomy, by death in one and three quarter hours, was due to the ulceration of a caseous gland into the trachea, and its retention by the capsule of the gland, just above the bifurcation of the trachea, thus causing fatal asphyxia. In his paper Mr. Parker gives references to several cases of a similar nature, and Dr. Coupland, in the twenty-fifth volume of the 'Transactions' of our Society, records the case of a child aged four who was asphyxiated by a caseous mass which had ulcerated into the trachea and blocked its lower end.

My object, however, is not so much to call attention to the occurrence of this lesion as to place on record the much rarer event of their causing, in apparently healthy children, sudden death.

Dr. Wynn Westcott in the 'British Medical Journal' for 1881 (vol. i, p. 386), described a case which appears very similar to the one I have just described. It was in a child aged three, who died in a few minutes, and at the autopsy a caseous gland was found impacted in the glottis, and there was a perforation in the trachea.

In 1893 I examined the organs from a child aged 3, who was said to have been choked by a piece of apple. The specimen was sent me with this "piece of apple" impacted in the glottis, but I found on careful examination that what had been taken for a piece of apple was really a caseous bronchial gland which had ulcerated into the left bronchus and then become impacted in the glottis.

When writing this paper I received a letter from Dr. Kelynack, to whose kindness I am indebted for the following case. He wrote to me that recently, in the course of a medico-legal examination, he came across a condition similar to the one I have brought before you to-night. A child had been partaking of toffee, when suddenly signs of suffocation appeared. The sweet was thought to have "gone the wrong way." Death occurred almost immediately. At the *post-mortem* examination a caseous bronchial gland was found to have ulcerated through a bronchus, and becoming detached had blocked the tube and produced the sudden asphyxia.

All the cases of sudden asphyxia from the ulceration of caseous glands into the air passages I have brought before you this evening occurred in children, and it is well known that the ulceration of caseous glands into the air passages is very much more frequent in children than in adults. Dr. Colman, at the Hospital for Sick Children, found 2 cases in 180 autopsies (1·1 per cent.), and Dr. Batten in 290 cases found 11 (3·9 per cent.). While pathologist at the same hospital I made 326 autopsies and found 12 cases (3·7 per cent.), an experience closely allied to that of Dr. Batten; ten of these were in children under 5 years of age. When, however, we compare these results with those derived from autopsies at a general hospital we find a great difference in frequency. In about 1800 autopsies which I have made at the Middlesex Hospital I have only observed six cases in which ulceration took place into the main air passages, all of them into the bronchi. Of these six cases three were in children 5 years or younger, the other cases occurring at 14, 24, and 57 years respectively.

With regard to the site of perforation, Dr. Batten has called attention to the greater frequency of occurrence on the right side,

and this quite coincides with my experience. In the cases at Great Ormond Street I found the trachea perforated once, the right bronchus seven times, and the left four times, and at Middlesex Hospital I found the right bronchus perforated four times, the left once, and both once. From this it would appear that perforation of a bronchus is more common than of the trachea, and of the right bronchus more often than of the left.

The preponderance of incidence on the right side, which was noted by Dr. Colman and Dr. Batten, is possibly due to the fact that the right bronchus is shorter than the left, and that therefore the glands are more closely disposed on the right than the left side, and also that the right lung is larger than the left, and consequently the possibilities of infection with tubercular material greater.

The actual perforation of the air passage generally takes place after softening of the gland, and such a softened gland may discharge by a small opening causing no obvious clinical signs, but if a rapid necrosis of the wall of the air-tube occur, and the gland have undergone but little softening, then such an accident as the discharge of a large caseous mass, and its impaction in the trachea, as in Dr. Coupland's and Mr. Parker's cases, or the larynx, as in Dr. Wynn Westcott's, Dr. Kelynack's, and my cases.

The caseous mass acts as a ball in a ball-and-socket valve, and thus while air can get in it cannot get out, and so the lungs become distended with air. The patches of collapse are probably due to the obstruction of the bronchi supplying the collapsed areas by caseous material inhaled into those bronchi.

Death in this case seems to have been due to cardiac inhibition, the right side showing no evidence of distension, the whole heart being firmly contracted.

February 15*th*, 1898.

---

7. *Ulceration of tubercular gland into trachea, with rapidly fatal result.*

By Cyril Ogle, M.B.

The larynx and trachea of a boy, aged 5 years, are shown. Whilst stooping, the child was seized with violent cough and dyspnœa. When seen half an hour later, he was half asphyxiated; there appeared to be some impediment to the entry of air into the lungs, as several inspiratory efforts would be made in quick succession, and then the chest, distended to the utmost, would slowly subside. As the child had previously been in apparently good health, tracheotomy was performed under the idea that there might be a foreign body lodged in the trachea or glottis. The breathing was not relieved, and death resulted within a few minutes. The boy had had none of the illnesses of childhood, and had not had any spasmodic cough or asthmatic attacks. There were scars of tubercular glands in the neck of the mother.

In front and to the right of the lower part of the trachea, just above the root of the right lung, and extending so far upwards as to surround the vena cava and right subclavian vessels, is seen a mass of enlarged glands. This has caused a bulging of the trachea, on its right side, at half an inch above its bifurcation; and just below this point there projects into the trachea, through an opening in its wall, an oval, firm lump, of the size of a hazel nut ($\frac{1}{2}$ inch by $\frac{3}{8}$ inch) which is continuous with the mass outside the trachea, and is of such a size, and in such a position, as practically to obstruct both bronchi.

A microscopic section of that part which is outside the tube simply shows the structure usually seen in tubercular infiltration, lymphoid, fibroblastic, and giant-cells, with a reticulum, the giant-cells being very numerous. There is remarkably little caseation, and the whole mass is very firm.

Although many instances have been recorded of ulceration of the trachea, and even of the œsophagus, produced by tubercular

glands, in the 'Transactions' of this society and elsewhere,[1] there appear to be only two in the 'Transactions' where the sudden extension, apparently, of a portion of gland through an ulcerated opening into the lumen of the trachea has produced a rapidly fatal result, one recorded by Dr. Percy Kidd in vol. xxxvi, and one by Dr. Gulliver in vol. xl; and these, in their clinical symptoms, were almost precisely similar to the present case.

February 15*th*, 1898.

---

8. *A case of an anæmic infarct in the lung.*

By L. Freyberger, M.D.

[With Plate X, fig 1.]

E. G—, 42 years old, housewife, was admitted to the Great Northern Central Hospital, February 18th, 1898, under the care of Dr. Beevor.

Patient stated that she had had a bad heart for years, and that for the last three weeks she felt short of breath. She complained of a feeling of pressure over the heart; she also had on several occasions coughed up considerable quantities of blood. The cough was dry and the expectoration sticky.

For the last fourteen days the tip of her nose had gradually become black; she had no feeling there, but it was very tender to touch.

Thirty years ago she had rheumatic fever, and her heart then became affected. Her father died of heart disease.

On admission.—A very anæmic and cachectic-looking woman; fingers slightly clubbed; radial pulse 108, very small and compressible, regular; resp. 48, temperature subnormal. The heart apex beat in the eighth space in the nipple line; it was heaving. Well-marked pulsation could be felt in the epigastrium; there was also a presystolic thrill. At the apex there was a loud presystolic murmur, which led up to a short ringing first sound which

[1] *Vide* "On Tuberculosis of Œsophagus," by C. Cone, M.B., 'Bulletin of Johns Hopkins Hosp.,' Nov., 1897.

was accompanied by a short systolic murmur. The second pulmonary sound was accentuated and reduplicated.

There was a small patch of dry gangrene on the tip of the nose.

The lungs were practically healthy, with the exception of the left base, where one heard loud consonating râles.

There was œdema of the legs and feet, the urine was acid, sp. gr. = 1045, with a trace of albumen.

The patient became gradually weaker, the pulse at the wrist and even at the elbow became impalpable, the gangrene spread rapidly from the tip of the nose over the whole of the alæ nasi and the cartilaginous part of the septum, and she became insensible on the sixth day after admission. Death occurred on February 27th.

At the *post-mortem examination* (eighteen hours after death) the following conditions were noted.

Body much wasted; small petechial hæmorrhages on both arms; dry gangrene of the tip of the nose and the nasal septum; œdema of the legs and ankles; extensive pale livid *post-mortem* stains on the back of the trunk and extremities; no rigor. Tongue, larynx, pharynx, œsophagus, and trachea pale, but without any morbid changes. In the right pleural cavity about 20, and in the left 27 oz. of clear straw-coloured fluid; the right lung adherent posteriorly, the left free. Both lungs together contained twenty-two infarcts; twenty-one of these were hæmorrhagic; the pleura over them dark bluish-purple in colour, without its natural lustre and beginning to become turbid; they all projected over the surface of the pulmonary pleura. One, however, situated in the posterior border of the right lung, at the level of the sixth rib, in the scapular line, presented the same outward signs as the others, except that the pleura over it was still smooth and shiny; when cut into it was seen to possess an irregular conical shape; it was spongy and of a pale greyish-brown colour; in its substance were found the cut orifices of two small branches of the pulmonary artery, which contained a little blood-clot. Parallel to the irregular wavy outline of the infarct, but $\frac{1}{16}$ inch inside, there ran a somewhat darker line, internal to which the substance of the infarct was a shade lighter. Immediately under the pleura there was an extremely narrow strip of dark purple hæmorrhagic tissue. There was no evidence of any reaction in the pleura over, or in the lung tissue around, the anæmic infarct.

The pericardial sac contained about two ounces of clear serum. The heart was enlarged and dilated, especially the left auricle, right auricle, and right ventricle, and contained large laminated blood-clots; the mitral valve, which was very much thickened and shortened from a previous endocardial affection, was the seat of a recent endocarditic vegetation which occupies the valvular attachments of the tendinous cords of the anterior papillary muscle; this vegetation formed an irregularly shaped roundish plug which protruded upwards into the left auricle, thereby blocking the narrowed mitral ostium to such an extent that a goose-quill could only be passed through it with difficulty; a similar but much smaller orifice was formed by a cleft within the vegetation itself. Aortic valves natural; pulmonary valves natural; tricuspid valves incompetent owing to overstretching of the valvular attachments. The spleen contained an anæmic infarct; liver and kidneys were anæmic and cloudy. The brain was not examined.

Minute anatomy of the anæmic infarct.—Subsequent examination of the lung showed that the interalveolar septa of the lung tissue around the infarct are thickened, the capillaries distended with blood, the epithelial lining of the alveoli thickened; in many instances the alveoli are filled with mucus and epithelial cells; occasionally one meets with small interstitial hæmorrhages or with dark brown granular blood pigment, either lying free in the interstitial tissue or being already intra-cellular. The alveolar lumina are smaller than natural.

The tissue of the infarct is stained of a uniform pale greyish blue and shows no nuclear staining at all with Ehrlich's hæmatoxylin; the arteries and veins are empty, the interalveolar septa and the alveolar epithelium finely granular and opaque, the nuclei very indistinct; the alveoli contain epithelial detritus and mucus.

Immediately under the pleura the tissue, for a depth of about two or three rows of alveoli, contains much blood, which fills the interstitial septa and alveoli as in the case of a hæmorrhagic infarct. The pleura over the infarct shows no signs of reaction.

Anæmic infarcts in the lung are very seldom found at *post-mortem* examinations. Although theoretically every infarct in the lung at the moment of, and for some little time after, its formation must of necessity be anæmic, collateral circulation by means of the pulmonary capillary anastomoses, and of the bronchial, mediastinal, and pleural arteries, is quickly established, and the paralysed vessels

of the infarct are filled with blood to the bursting point. But when, as in this case, the action of the heart is failing, and, owing to mitral stenosis, only a diminished quantity of blood is sent out into the general circulation by the left ventricle, the chances of the establishment of a collateral circulation in the embolised section of the lung through the auxiliary vessels become very small indeed. In our case the only effort at collateral circulation seems to have been made by the pleural vessels, as the narrow band of hyperæmic tissue under the pleura over the infarct shows. The absence of any turbidity or dulness of the pleura over the infarct makes it probable that the infarct occurred shortly before death, and that there was not sufficient time for the infarct to be filled with blood and to become hæmorrhagic.

March 15*th* and *May* 3*rd*, 1898.

III. DISEASES, ETC., OF THE ORGANS OF CIRCULATION.

1. *Calcification of pericardium following suppurative pericarditis.* (*Card specimen.*)

By James Calvert, M.D., and T. Strangeways Pigg.

W. D—, aged 25, admitted 24th May, 1897, into St. Bartholomew's Hospital under Dr. Hensley.

History.—Five years ago, after an exhausting walk, he felt his "heart tumbling about;" he fainted, but he was not confined to his bed at this time. Since then has suffered from heart symptoms; fourteen days ago rigor, and laid up in bed for the first time in his life.

On examination found to have left pleuritic effusion and some bronchitic sounds on the right.

Heart.—Apex not felt, dulness increased to right, systolic murmur round apex.

Died on 1st June—three weeks after rigor—from failure of right ventricle.

Post-mortem.—Recent pleurisy with effusion on left side.

Heart.—Weight with pericardium 22 ounces. Pericardium adherent over greater part of heart and much thickened, and, with the exception of some soft nodules over the ventricles, the pericardium was *calcified*, forming a rigid casing over both ventricles and over the front and side of right auricle. The soft nodules contained fluid yellow pus.

Over the right ventricle the parietal pericardium was separated from the partly calcified visceral layer by a cavity which extended into the muscle of left ventricle near apex. This cavity contained pus. Left ventricle somewhat hypertrophied. No tubercle. No actinomyces could be found.

November 2nd, 1897.

2. *Cancerous pericarditis secondary to malignant stricture of the œsophagus.* (*Card specimen.*)

By R. G. Hebb, M.D.

The specimen was taken from a female aged 67, who was admitted to the Westminster Hospital for difficulty of swallowing. The dysphagia, first noticed about the end of February, 1897, increased until she was able to swallow only fluids. On June 9th, 1897, the first part of the operation for gastrostomy was performed by Mr. Stonham, the stomach being opened on the 12th. The patient died on June 16th.

At the autopsy it was found that the œsophagus for a distance of four inches from its commencement was infiltrated with a firm white neoplasm. The lumen of the tube was greatly stenosed, and the internal surface ulcerated. The growth had invaded the left thyroid lobe, and had implicated the recurrent laryngeal nerve. The heart, with the pericardium, which was universally adherent and greatly thickened, weighed 28 ounces. The thickening and adhesion were due to the presence of a firm white growth, which had also invaded the right ventricle, appearing on the endocardial surface as a raised, flat, white layer with a diameter of $\frac{3}{4}$ inch. In the neck and near the heart were a few enlarged lymphatic glands. There were no other secondary deposits. Microscopical examination showed the nature of the œsophageal growth to be squamous epithelioma, there being numerous collections of large keratinised epithelial cells and cell-nests. In the pericardial infiltration, which must be regarded as a metastatic deposit, the appearances are frequently those of alveolar carcinoma, though here too there are numerous collections of large keratinised epithelial cells.

The case is recorded to show the general cancerous infiltration of the pericardium following on a primary growth in the œsophagus and the invasion of the cardiac muscle. It is also interesting from the fact that during the first operation the patient was under the influence of an anæsthetic for a little over an hour. At first chloroform was used, but finding that the patient did not bear this well, the anæsthetist (Mr. McLeod) changed it for the A.C.E. mixture.

May 3rd, 1898.

3. *Extensive metastatic deposits of carcinoma in the heart.* (*Card specimen.*)

By Arthur Voelcker, M.D.

The anterior longitudinal furrow and the posterior portion of the auriculo-ventricular furrow are the seats of an extensive deposit of pale, firm new growth. The cavities of the heart have been opened on the posterior aspect.

A large nodule of growth is seen at the base of the papillary muscles in the right ventricle. It is the size of a filbert.

At the anterior portion of the conus arteriosus is another discoid patch of new growth half an inch in diameter. Several smaller nodules of new growth are seen in the walls and on the surface of the left ventricle and auricle. The primary growth was at the pyloric end of the stomach.

From a woman aged 61, who was admitted into the Middlesex Hospital, September 27th, 1897, and died October 18th, 1897.

During life there were no abnormal heart-sounds. A recent hæmorrhagic infarct of the lung and thrombosis of the left saphenous vein were found at the autopsy.

October 19*th*, 1897.

---

4. *Fatty infiltration of the heart; death after ether anæsthesia.* (*Card specimen.*)

By R. G. Hebb, M.D.

The microscopical preparations exhibited were taken from the heart of a female, aged 52, who was admitted to the Westminster Hospital, under the care of Mr. Spencer, on June 24th, 1897, for enlarged and thickened bursæ patellæ, which had caused much pain and inability to work. After a careful examination, in which nothing abnormal was detected, the patient was anæsthetised with gas and ether. No inconvenient symptoms occurred during

the operation, which was a short one, and the administration of the anæsthetic had ceased for about five minutes, when, as the patient was being removed from the theatre, her face was noticed to become blue, and abundant frothy mucus began to pour from her mouth. Tracheotomy was done, and much of the frothy mucus was sucked out. It tasted as salt as sea water, and slightly but not markedly of ether. She gradually stopped breathing, gasping at increasing intervals, and all attempts at resuscitation were without avail.

For the foregoing I am indebted to the notes of the surgical registrar, and to information supplied by Mr. Spencer.

The autopsy was made twenty-three hours after death. Body adipose. Heart twelve ounces; the blood in the cavities is dark and fluid. There is excess of subepicardial adipose tissue. About the apex of the right ventricle the muscle is practically replaced by fat. On section the wall of the ventricle is seen to be studded all over with yellow striæ, and immediately beneath the endocardium are numerous yellow deposits. In the left ventricle the appearances are similar though less frequent and extensive. Arteries atheromatous. Lungs large, emphysematous, and very œdematous. Abdominal viscera not specially noteworthy.

Microscopical examination of the walls of the ventricles shows numerous collections of adipose tissue scattered between the muscle bundles and immediately beneath the endocardium. The muscle fibres seem rather thin, but their striation is clear and definite, and nowhere can any pigment granules be seen in them.

The case affords an example of the fatty heart properly so-called, and is recorded on account of the general infiltration of the ventricular walls with adipose tissue.

The case is also interesting, owing to death following the administration of ether. This, as suggested by Mr. Spencer from the phenomena exhibited by the moribund patient, might be due to acute pulmonary œdema, or, as I prefer to think, chiefly to the weakness of the heart itself, and the toxic action of the ether on the blood.

February 1st, 1898.

5. *A case of patent septum interventriculare, patent foramen ovale, and congenital stenosis of the pulmonary artery, coupled with an anomalous distribution of the thoracic veins.*

By Ludwig Freyberger, M.D.

William F—, 11 months old, was admitted into the Great Northern Central Hospital on February 8th, 1896, suffering from rickets and basic meningitis. The area of cardiac dulness was slightly increased, there was a systolic thrill, and a systolic murmur which could be heard loudest in the second intercostal space near the left edge of the sternum. At the apex, which beat in the fifth intercostal space a little to the left of the nipple line, a loud systolic murmur and an accentuated second sound were heard; there was much epigastric pulsation and slight general cyanosis.

Death on the 9th February.

At the *post-mortem* examination, sixteen hours after death, besides rickets and posterior basic meningitis, the following abnormal conditions of the circulatory system were found:

1. Two descending venæ cavæ; the right following the course of the normal descending cava, the left running down to the left of, and parallel to, the œsophagus, and entering the coronary sinus. The two cavæ are connected with each other across the jugulum by means of a small vein which represents the ill-developed left innominate vein. Each of the descending cavæ has an azygos vein of its own which courses upwards over the capitula of the ribs, and, turning forwards over the branches, joins its descending cava where it pierces the pericardial sac; there is no trace of the usual connection between the two azygos veins across the bodies of the seventh or ninth vertebræ.

2. On opening the pericardial sac the heart is found lying transversely almost at a right angle with the median axis. The anterior aspect of the heart is formed by the much distended right auricle and the dilated right ventricle, which also forms the apex. The aorta measures nearly one inch across, there is no pulmonary conus, and the pulmonary artery, a collapsed, narrow, thin-walled vessel of about one third inch diameter, is inserted to the left of

and a little behind the aorta, between this vessel and the auricular appendix of the left atrium. The left ventricle is situated on the posterior aspect of the heart; it is much smaller than the right, by which it is completely hidden from view. The left auricle cannot be seen because it is entirely covered by the enormously dilated coronary sinus and the cardiac end of the left descending vena cava.

3. On opening the ventricles laterally, the wall of the right is found nearly half an inch thick, that of the left a quarter of an inch. The membranous part of the interventricular septum is entirely absent; the defect thus formed in the septum admits the tip of one's little finger. The tricuspid valves are well developed and competent; a steep funnel-shaped ascent leads to the narrow pulmonary ostium, which is formed by two lip-shaped rudimentary valves and admits a glass rod not thicker than one twelfth of an inch.

4. The left ventricle, besides being small, presents nothing abnormal; the mitral valves are well developed and competent. The aortic ostium is nearly two thirds of an inch wide, and so situated above the defective interventricular septum that it looks as if it had been inserted into the right rather than the left ventricle; it can be reached from both ventricles. The aortic valves are natural and competent.

5. The right auricle is very spacious, its muscular wall of considerable thickness. The foramen Thebesii, through which the coronary sinus empties itself into the right auricle, has a diameter of over half an inch, and leads into the enormous coronary sinus, which practically is the auricular termination of the left descending vena cava; the foramen ovale is also patent; it measures $\frac{1}{8} \times \frac{1}{3}$ inch; its longer axis is nearly horizontal.

6. The left auricle is small; it could only be reached by an incision through the anterior wall of the coronary sinus. The left auricular appendix protrudes a little between the aorta and the descending cava.

7. There is not the slightest trace of fœtal endocarditis on any of the valves.

8. The ductus arteriosus Botallii is still patent, and admits a glass rod one sixteenth of an inch in thickness.

The lungs are well developed, and overlap the pericardium completely. Liver, spleen, and kidneys are somewhat firmer than natural, and slightly cyanosed.

There is no clubbing of the finger ends.

Conclusions.—I. The absence of any signs of fœtal endocarditis shows that the malformation of the heart is due to an arrest of development which occurred at some time during the second month of fœtal life, a view which is further supported by the concomitant anomaly of the thoracic veins.

II. The full development of the lungs and the slight cyanosis during life show that there must have been a sufficient circulation of blood in the branches of the pulmonary artery, although the pulmonary ostium is almost impassable.

III. This circulation of blood has taken place through the stenosed pulmonary ostium, the Botallian duct, and the anterior and posterior bronchial arteries which come from the internal mammary artery and the thoracic aorta respectively. These arteries form more or less wide anastomoses with the capillaries of the pulmonary artery, and may in this case have helped to supplement the pulmonary circulation.

November 16th, 1897.

---

6. *Heart with tumour of the pulmonary valves.*

By Raymond Crawfurd, M.D.

This heart was removed from an inmate of the Essex County Asylum, and was kindly sent to me by the medical officers. The patient, W. T—, was a labourer aged 72. He had been insane with delusions for two and a half years, and an inmate of the asylum on and off for eight months, when one morning, while dressing himself, he suddenly fell down dead. I have ascertained from his successive medical attendants that there was no sign or symptom of cardiac trouble until two years before his death; indeed the first positive sign was detected less than a month before his death, when he is said to have had a systolic aortic murmur audible both at the base and apex of the heart: the autopsy, however, leaves little room for doubt that this murmur was produced at the

pulmonary orifice. The rest of the clinical history is not materia to the present issue. The following facts were noted *post mortem:* there was serous effusion in both *pleural sacs*, 600 c.c. on the right side and 250 c.c. on the left. The *left lung* was adherent to the chest wall at the base behind, and very congested throughout; *right lung* very emphysematous. The *pericardium* contained 115 c.c. of clear serum, and there was a little fluid free in the *peritoneum*. The *liver* was large, rough, and cirrhotic. The *spleen* large and very soft. The *kidneys* large and tough and deeply congested; cortex narrow; pelvis fatty; capsule peeled readily. There was no growth in any organ of the body except the heart. The *heart* was bulky, and weighed 15 ounces; fatty changes were not noticeable. The *right auricle* was enormously ballooned, and the wall so thin as to be almost transparent in places; the *right auricular appendix* was dilated, but its walls were not so thinned. The *tricuspid orifice* was markedly dilated, as also the cavity of the *right ventricle;* the wall of the right ventricle was nearly twice the usual thickness. The *left auricle* seemed unaltered, but there was considerable hypertrophy of the wall of the *left ventricle*. The interventricular and interauricular *septa* were perfect, and the *aortic*, *mitral*, and *tricuspid* valves healthy. There was commencing atheroma at the root of the *aorta*, but no occlusion of the *coronary arteries*. The two *anterior pulmonary semilunar cusps* were healthy and normal, but growing from the *posterior cusp* and the contiguous portions of the artery and of the wall of the right ventricle was a large tumour. This was roughly ovoid in form, deeply lobulated, elastic, and greyish white, and glistening in appearance; one or two dark patches at the surface suggested minute hæmorrhages into its substance. It was 5 cm. in length, and 3 cm. in its transverse measurement; it was sessile, and its centre was on a level with the centre of the pulmonary valve; above this point it extended 3·5 cm. upwards into the pulmonary artery, and 1·5 cm. downwards into the right ventricle. The fixed base of the tumour seemed to extend about 1 cm. in every direction from the centre of the posterior cusp of the pulmonary valve. There was no obvious dilatation of the *pulmonary artery*, and its channel was completely blocked by the tumour, except for a sinuous furrow along its anterior surface, with a channel about equal to that of the brachial artery. On dissecting the aorta from the pulmonary artery, the outer walls of the pulmonary artery appeared perfectly normal.

FIG. 1.

The upper two thirds of a heart, showing a tumour of the pulmonary valve. A portion of the tumour has been removed for microscopical examination.

Death was almost certainly due to the tumour suddenly blocking the pulmonary orifice.

For microscopic examination the tumour was hardened in formalin, embedded in paraffin, and stained with alum carmine; the sections extend from the surface right down to the centre of the mass. There is a rind of fibrin which has fallen off from the greater part of the surface of the tumour, probably in the process of preparation. That this is fibrin there can be no doubt, both from its laminated arrangement and from the peculiar deep staining with carmine so characteristic of degenerate fibrin, and so well seen in grey hepatisation. Immediately beneath this and forming the deepest part of the section is a wide area of fully-developed fibrous tissue, in which are well-formed blood-vessels. From this tissue fibro-cellular strands traverse the whole of the section, and at their distal ends pass insensibly into the general material of the tumour. Starting out as lateral excrescences from these chief strands are collections of cells in an earlier stage of development; some are simply round cells, but some are markedly fusiform, and the clumping together of groups of spindle-cells, all at much the same stage of maturity, gives a first impression of spindle-celled sarcoma. These processes, however, merge naturally into the fully formed fibrous tissue, and put malignancy out of the question. Here and there are numbers of closely-packed red corpuscles side by side with an open network of fibrin.

Remarks.—Taking all the facts together, it seems most probable that the initial nucleus of this tumour was a thrombus, formed for some or other reason on and about the pulmonary valve; the clinical history and the healthy character of the other cusps certainly do not suggest an inflammation of the valve, so that presumably the thrombosis was spontaneous. Several points suggest that the thrombus was gradually built up, such, to wit, as the changes in the walls of the auricle and ventricle, the absence of any clinical symptoms, and the absence of pigment, showing that the clot was not one in which red corpuscles were largely included. This thrombosis would seem to be the scaffolding on which the whole tumour has been constructed. Under this thrombus proliferation of the endocardium has gone on luxuriantly, and fibro-cellular outgrowth has replaced nearly the whole of it; in fact, the condition is that which is found in the organising of every endocardial vegetation, only that we have it here on a large scale. The wonder of the tumour

is not "what it is," but "what it did, or, rather, did not do," for the patient lived up to the moment of his death without any sensible inconvenience from its presence.

March 1*st*, 1898.

Report of the Morbid Growths Committee on Dr. Crawfurd's tumour of the pulmonary valves.—We agree with the description supplied by the author, but he has omitted to mention that besides the main tumour there is a distinct infiltration of the pulmonary artery itself above the valves. The infiltration is nodular and hæmorrhagic. It is situated in the intima, and apparently does not extend beyond the elastic layer.

The tumour is either a sarcoma or an organised blood-clot. Taking the microscopical appearances with the clinical history, we think that it is an organised blood-clot. We are unable, however, to exclude sarcoma with absolute certainty, although the clinical history is against it, and the microscopical structure too typical and regular for sarcoma.

In certain situations, moreover, there is well-formed vascular fibrous tissue, in others there are coagula or hæmorrhages; the cells are spindle-shaped but very regular.

A. A. Kanthack.
D'Arcy Power.

The other members of the Committee who examined the specimens were of opinion that the tumour was a spindle-celled sarcoma.

Norman Moore, *Chairman.*

---

7. *Heart with extreme calcification of the aortic and mitral orifices, from a case with exceptional physical signs.*

By F. Parkes Weber, M.D.

The heart weighs 24 oz., and the increased weight depends mainly on hypertrophy of the left ventricle. The aortic valves are much thickened, calcified, and partially adherent to each other, so that only a rigid triangular space, just admitting the tip of the

little finger, is left, through which the blood-stream had to pass. The mitral valves are likewise thickened and much calcified. The coronary arteries are only very little affected, the orifice of one of them being slightly stenosed. A small, red, adherent thrombus was found at the *post-mortem* examination, plugging the coronary vein on the front of the heart, exactly over the upper part of the septum ventriculorum. This thrombus had probably not existed a very long time before death. The aorta showed no great amount of atheroma, and there was no aneurysmal dilatation.

Much interest is attached to the physical signs presented by the patient during life (see 'Clinic. Soc. Trans.,' vol. xxx, p. 224). The impulse at the apex was heaving and diffused, but the apex-beat could be approximately located in the sixth left intercostal space, 1½ inches outside the nipple line. The cardiac dulness on the left side of the sternum commenced above the fourth rib, and extended downwards to the apex-beat. To the right of the sternum the dulness extended for about 1½ inches, and reached upwards to the third space, that is, considerably higher up than on the left of the sternum. A harsh systolic thrill was felt in the second and third intercostal spaces to the right of the sternum, and over the area of the thrill a systolic murmur could easily be heard without a stethoscope, if the ear were placed within an inch or two of the chest. The same systolic murmur was likewise heard with the stethoscope over the rest of the cardiac area and over a considerable part of the back and front of the chest, and was conducted loudly into the vessels of the neck.

The diagnosis lay between the rare condition of extreme "pure aortic stenosis," and aneurysm of the first part of the aorta. The symptoms might be compared to those in the case of a man mentioned by Dr. Foxwell ('Brit. Med. Journ.,' 1896, vol. ii, p. 1574), who during life was supposed to have aneurysm, but at the necropsy was found to have only pure aortic stenosis.

My patient was a man, aged 45, tall and fairly well built, but pale and emaciated. He had more or less permanent dyspnœa, and persistent bradycardia. The frequency of the heart's action varied between 44 and 48 beats in the minute, and was not influenced by exercise or drugs. The pulse was regular, of rather slow rise (as shown by sphygmographic tracings) and of moderate tension. The man had lived an active life and had enjoyed good health. He had had syphilis when seventeen years old, but never

rheumatic fever. In 1889 he was told that his heart was diseased, but he continued to enjoy tolerable health till 1896, when he complained of shortness of breath and nervousness, with occasional syncopal attacks. In 1897 there was obvious failure of compensation; the dropsy and the dyspnœa increased and the patient died in May, 1897. Amongst the drugs employed iron seemed to have been of some use for a time.

The fact that the dulness at the base of the heart reached higher up on the right side of the sternum than on the left was somewhat suggestive of aneurysm. The thrill over this region was accompanied by slight pulsation, but there was no definite expansile pulsation, nor any notable difference between the two radial pulses, nor were there other signs of aneurysm. Clinically, therefore, the case appeared one of "pure aortic stenosis," though a slight diastolic murmur over the cardiac base was heard in addition to the systolic roar during the last months of life. It may be mentioned also that the "pulse-delay" between the heart and the radial artery was not very great.

The exact connection of bradycardia with such extreme cases of aortic stenosis has not, as far as I know, been yet satisfactorily explained. The almost persistent dyspnœa is, I am inclined to think, in great part due to cerebral anæmia, for it shows itself before decided signs of imperfect compensation. The marked extent upwards of the dulness on the right of the sternum was probably due to a change in the position of the whole heart in relation to the sternum, but I was not myself present at the *post-mortem* examination, and this point was not specially investigated.

As in most other cases of marked bradycardia, so also in this one, the frequency of the heart's action was not increased by drugs or exercise. The heart in these cases cannot make up for diminished driving power of the individual pulsations by increased frequency of action. Sir W. Broadbent has pointed out in his Croonian Lectures ('Lancet,' 1887, vol. i, p. 659), that bradycardia, even without any obvious organic disease, may prove a serious danger in some circumstances.

Naturally when there is persistent bradycardia the action of drugs like digitalis cannot be easily controlled, but digitalis was used temporarily in the present case, and with apparently temporary (subjective) good effect. The patient appeared likewise for a time to derive benefit from iron preparations.

He was discharged from the police force in 1889 on account of heart disease, but it was only in 1896, I believe, that he became incapacitated for work. I cannot help suspecting that the change from an active to a sedentary life, consequent on his change of occupation, may have led to extreme calcification (a regular petrifaction) taking place in the already diseased valves—especially the aortic ones. If this was so, the change to a sedentary kind of life may actually have accelerated death. Rumpf ('Berliner klin. Wochenschr.,' 1897, Nos. 13 and 14), has regard to cardio-vascular cases of this kind when he advocates the introduction into the body of only as much lime salts as are excreted by the motions and the urine.

December 7th, 1897.

---

8. *Anomalous truncus brachiocephalicus associated with aortic incompetence and symptoms simulating aneurysm.*

By Ludwig Freyberger, M.D.

Rebecca P—, 26 years old, servant, was admitted to the Great Northern Central Hospital on May 5th, 1896, under the care of Dr. Clifford Beale.

Previous history.—Several months before admission the patient found herself getting tired and short of breath after exertion, her ankles began to swell, and she began to lose flesh. She also complained often of pain in the left side of her chest, and she repeatedly spat up red frothy blood. A few weeks before admission she noticed a "lump beating in the neck," which since has gradually grown larger. She had rheumatic fever in 1897, when all her joints were affected in turn; since then her heart was weak.

On admission.—Respiration orthopnœic. The apex beat in the sixth intercostal space, four and a half inches from the midsternal line; the impulse localised, faintly heaving; no thrill. There was a blowing systolic murmur at the apex, somewhat high-pitched, audible in the axilla, but disappearing in the third left space. There was also a systolic and diastolic bruit at the second right cartilage. The second sound at the fourth left rib was "knocking."

The arteries: a pulsating swelling was visible above the right sterno-clavicular articulation; its centre was covered by the sternal and clavicular insertions of the sterno-cleido-mastoid muscle; the swelling measured 1½ inches from side to side, and about 1 inch from above downwards. There was no thrill, but a to-and-fro bruit could be heard over it. The pulse was visible at the bend of the elbow and at the wrist. Death took place on the 21st of July.

Clinical diagnosis: Morbus cordis; double aortic murmur; aneurysmal dilatation of the innominate artery.

Post-mortem.—At the *post-mortem* examination, eighteen hours after death, the following conditions were found:

Body much wasted; malleolar œdema; extensive dark livid *post-mortem* stains on the back of the trunk and extremities; rigor present. In the jugular fossa, which was very deep, a bulging body could be seen and felt, which extended across from one sterno-mastoid to the other; its upper border was about half an inch above the notch of the manubrium sterni, its lower border could not be felt; on the right and the left the swelling seemed to extend beneath the insertions of the two sterno-mastoid muscles. On dissecting back the skin and the platysma this bulging was seen to be caused by an abnormally wide truncus brachiocephalicus (*sive anonymus*) into which were inserted the arteria thyreoidea ima and the left common carotid artery. This short common trunk was right in front of the trachea, and measured *in situ* about half an inch across. It gave off the right subclavian and right common carotid arteries, the arteria thyreoidea ima and the left common carotid artery. The left subclavian artery was found in its normal place and position. The ascending aorta was considerably wider than natural; transverse and descending aorta showed no abnormal conditions.

The heart was hypertrophied, especially in its left half. The tricuspid, pulmonary, and mitral valves were natural; the aortic valves atheromatous, shortened, and incompetent; the ascending aorta slightly atheromatous.

There was brown induration of the lungs, which were firmly adherent at their apices, nutmeg liver, cyanotic spleen, and granular kidneys.

The union of the left carotid artery with the innominate artery into a common truncus brachiocephalicus is of comparatively frequent occurrence, and is the normal condition in most apes.

What makes this anomaly interesting, from a pathological point of view, is the fact that, occurring in a subject suffering from aortic incompetence and a moderate degree of atheromatosis, it produced abnormal pulsation in the jugular fossa and beneath the right sterno-mastoid muscle, which together with the to-and-fro murmur heard over that area suggested the presence of an aneurysm of the innominate artery.

January 18*th*, 1898.

---

9. *Aortic incompetence due to dilatation of the orifice without disease of the valves.*

By G. Newton Pitt, M.D.

[With Plate I, figs. 1 and 2.]

Case 1.—I have for many years past looked upon it as one of the accepted facts in pathology, that dilatation and yielding of the first portion of the aorta was capable of producing regurgitation through the aortic orifice, and that in such cases shrinkage and cicatricial contraction of the cusps was not an essential part of the process. The late Dr. Moxon used to teach this, and I remember more than one case in which the correct diagnosis of aortic incompetence without disease of the valves was made. I have myself made a similar diagnosis, which at the inspection was found to be correct, and the same has been the experience of others.

When, a short time ago, a physician of large experience asked what published evidence there was of the pathological proof of this view, I found that there was none very definite, and I therefore thought it would be of interest to lay before the Society the notes of the following eight cases, four of which are drawn from the *post-mortem* records of Guy's Hospital, and four are specimens in the museum. It would not be difficult to collect many more, were it necessary.

Case 1.—A man aged 42, admitted with a to-and-fro aortic and an apical systolic bruit. The heart weighed 20 oz. Mr. Targett, who made the *post-mortem*, described the first part of the aorta as

DESCRIPTION OF PLATE I.

Illustrating Dr. Newton Pitt's paper on "Aortic Incompetence, due to Dilatation of the Orifice, without Disease of the Valves." (Page 46.)

FIG. 1 (Case 5).—The atheromatous condition of the aorta above the valves has produced incompetence, as shown by the dilated condition of the left ventricle. The cusps are not thickened.

FIG. 2 (Case 8).—The extensive atheroma of the aorta has caused considerable pouching, which has enlarged the orifice. There is some thickening of the cusps, but the incompetence has mainly or entirely arisen from the stretching of the orifice, and not from the condition of the cusps.

Fig. 1.

Fig. 2.

DESCRIPTION OF PLATE

[illegible] Dr. Newton Pitt's pa[illegible] Dilatation of the Orifice, with [illegible] (Page 46.)

[illegible] Case 5.—The [illegible] condition [illegible] competence, as shown by the [illegible] condition of [illegible] Tor cusps are not thickened.

[illegible] Case 8.—The extensive atheroma of [illegible] has enlarged the orifice. There is some [illegible] incompetence has many or [illegible] arisen [illegible] and not from the condition of tor cusps.

CASE 6.—A woman aged 50, who died with carcinoma of the uterus. A to-and-fro aortic bruit had been audible during life. There is a saccular aneurysm of the arch of the aorta, some three inches across, which has stretched the aortic orifice. The aortic valves are slightly thickened, but are neither shrunken nor shortened. There would have been no incompetence of the valves if the orifice had not been dilated. The small size of the left ventricle shows that but a small amount of leakage had taken place.

CASE 7.—A man aged 25, a sailor who had had a chancre but no secondaries. During life a to-and-fro aortic bruit had been audible. The valves are normal, but the orifice is stretched, so that the valves are narrower than normal, and are markedly incompetent. There is an acute atheromatous condition of the aorta for some distance above the valves. The surface of the vessel is wrinkled, and the wall has yielded, the lumen being dilated. This yielding has involved the attachment of the valves. The disease is limited to the first inch and a half of the aorta, and there is also a small amount near the origin of the great vessels, but the rest of the aorta is free from disease. The left ventricle is dilated; there was mitral incompetence. The rest of the viscera are normal.

CASE 8.—A woman who was brought in dead. The left ventricle is dilated and hypertrophied. The aorta is atheromatous and has yielded in consequence of the change. The orifice is stretched, so that one cusp lies close along aorta, and a finger-tip cannot be introduced behind it. There was the scar of a bubo, but there was no evidence of syphilis. (Plate I, fig. 2.)

February 1st, 1898.

---

10. *An aortic aneurysm which ruptured externally.*

By LEE DICKINSON, M.D.

THE specimen was taken from a coachman aged 39, who died in St. George's Hospital on November 10th, 1897. He had lived temperately and quietly, and there was no history or suspicion of syphilis. He came under medical treatment with symptoms of thoracic aneurysm about ten months before his death, and within that time a pulsating tumour made its appearance at

the front of the chest, and steadily increased in size. A few days before the end, blood began to leak from the most prominent part of the tumour, and at last it burst out suddenly and forcibly. The house physician was quickly at hand, and the patient lived for about twenty minutes. The loss of blood was hardly profuse, but it was enough to be the cause of death, coming, as it did, after a long period of pain and depression.

Post-mortem.—The tumour, though sufficiently striking, was less so than it had been during life. It was roughly hemispherical in shape, and occupied the greater part of the front of the chest from the first rib downwards. The circumference of the tumour measured 21½ inches, and the summit was full 6 inches in advance of what would have been the normal level of the chest wall. This great prominence was largely due to tilting forward of the sternum by the aneurysm behind, partly to the presence of a secondary sac or diffuse aneurysm outside the bony thorax. The secondary sac was of the size of a large orange, and communicated with the other by an irregular opening which had been formed by absorption of the second, third, fourth, and fifth cartilages on the right side, with part of the corresponding ribs and edge of the sternum. The aneurysm proper was larger than a cocoanut, and of true saccular form, springing from the anterior and right aspect of the aorta, one inch and a half above the valves, by a mouth the size of a five shilling piece. The aneurysm had grown mainly to the front, and showed no tendency to rupture in any other direction; the right lung, however, was partly, and the left innominate vein completely compressed.

Both sacs contained a considerable quantity of old clot, but the deposit was irregular and partly broken up, having evidently been disturbed by the force of the blood-current.

The heart was small, otherwise healthy. The aorta was remarkably free from atheroma, of which, indeed, there was no trace, except a little roughening near the mouth of the aneurysm. The vessel was conspicuously thin walled, and somewhat small in calibre. It was estimated that at the end of the arch the wall was of not more than three fifths the ordinary thickness. The three coats were present in their proper proportions, and no fatty or other degeneration could be detected under the microscope.

The liver, spleen, kidneys, and other abdominal organs were perfectly healthy.

It is not very uncommon for an aneurysm to present at the front of the chest in such a way that external rupture and death by fulminating hæmorrhage appear to be imminent; but such an end is, in fact, extremely rare. The external tumour which looks so threatening during life is usually found afterwards to be not the aneurysm itself, but a more or less diffuse extravasation under the muscles and integuments of the chest, where coagulation readily occurs. Blood may ooze from one or more points for days together, and even when a tangible rupture takes place the clot acts like a valve, and moderates the violence of the hæmorrhage. The subject has been dealt with in some detail by Dr. Boinet in two interesting papers in the 'Revue de Médecine' for May, 1897, and February, 1898; and I will only remark further that aneurysms which threaten to rupture externally are often upon anatomical grounds particularly suitable for medical treatment. That they are not necessarily fatal, even after the occurrence of rupture, is shown by the two classical cases reported by Syme and Neligan.

Part of the interest of the specimen shown consists in the hypoplasia of the aorta, which must be regarded as, at any rate, the predisposing cause of the aneurysm. In the forty-fifth volume of the 'Pathological Transactions' I have recorded two cases of aortic aneurysm apparently due to hypoplasia; but I do not know of any other observations of the kind. Virchow is the one authority upon arterial hypoplasia, and as regards its connection with aneurysm he merely remarks upon the liability of the hypoplastic aorta to fatty degeneration of its middle coat, and so to spontaneous rupture and dissecting aneurysm.[1] However, it is not impossible that a slight degree of hypoplasia may be the unrecognised ally of certain aneurysms which prove obstinately progressive. Women are specially liable to hypoplasia, and when aneurysms occur in women they go from bad to worse more readily than in men, and are far more apt to rupture externally.

Hypoplasia of the arteries is occasionally associated with hæmophilia. Virchow appears to have met with several cases. I may briefly mention one which occurred at St. George's in 1894.

A man aged 35 sustained a comparatively trivial head injury followed by symptoms of compression of the brain, for which he was trephined. The compression was found to be due to hæmorrhage which could not be traced to any particular vessel, and the

[1] 'Ueber die Chlorose,' 1872.

operation was followed by fatal oozing of blood from the wound. It was subsequently learnt that the man had been recognised as a bleeder some years before. The aorta and great arteries were conspicuously thin and narrow.

I am not aware that aortic aneurysm has ever been found to coexist with hæmophilia. A more untoward combination could hardly be imagined.

April 19th, 1898.

---

11. *Aneurysm of the ascending aorta perforating externally.*

By Ludwig Freyberger, M.D.

Mrs. E. B—, 52 years old, laundress, was admitted into the Great Northern Central Hospital under the care of Dr. Beevor, on April 4th, 1898.

About two years before admission she noticed a small tumour the size of a split pea, which was freely moveable and was situated under the skin over the right second intercostal space; it caused no pain. The tumour grew gradually larger and spread forwards and downwards over the right mamma.

Three months before admission (January, 1898) she noticed pulsation in the tumour; during the last two months the tumour grew rapidly, the skin over it became inflamed; the tumour was painful for about three weeks before admission. Patient had not been treated for it, but continued working until the day before her admission into the hospital.

No history of syphilis could be obtained. Patient had two miscarriages; one child which had been born at full term is alive and in very good health.

On admission.—An unhealthy-looking woman. Lies in bed mainly on her back with the right arm overhead, in which position she gets more relief from the pain in the tumour. Pulse 108 small, but regular; arteries hard and somewhat tortuous; temp. 101° at night. Heart apex-beat in the fifth space in the nipple line, heaving; area of cardiac dulness extends over the third, fourth, and fifth spaces from the sternum to the nipple line. At the apex there is a systolic and diastolic to-and-fro murmur, replacing the heart-sounds; the

systolic murmur is conducted to the axilla, but is gradually lost up the sternum ; the diastolic is conducted from the base and heard all over. At the base there is also a diastolic and a systolic murmur.

A pulsating expansible tumour covers the front of the right half of the chest from the first to the fifth rib, and from the sternum to the anterior axillary line; it reaches forward three inches from the chest wall and measures seventeen inches in circumference, resembling an ostrich egg in shape and size; the skin covering it is shining and inflamed, and much stretched. There is no thrill; the percussion note is dull ; a systolic and diastolic murmur can be heard over it; the tumour expands immediately after the heart systole. The radial pulse at both wrists is equal in strength ; both jugular veins are distended.

Since her admission the tumour increased still more in size ; this increase became more rapid during the second week.

On April 9th (five days after admission) a black slough appeared over the centre of the tumour which gradually extended over the top of the tumour.

On April 12th blood began to ooze from a superficial crack in the skin over the tumour; the bleeding soon became more copious. Two needles were inserted into the tumour for about four inches, after compression of the tumour had proved without effect.

On April 14th the tumour suddenly ruptured; pressure was applied, but the hæmorrhage continued, and death occurred two hours later.

At the *post-mortem* examination, twelve hours after death, the body was found wasted, pale, with extensive pale livid *post mortem* stains on the back of the trunk and extremities; rigor mortis well developed.

The region of the right mamma was occupied by a large bulging tumour, which measured 23 inches round the base and 16 inches over its convexity. The skin was fixed over it, discoloured and excoriated, especially on the top of the tumour, where there was also an irregular opening which had been plugged with cotton wool. The tumour fluctuated. The nipple was found near the base of the tumour and internally to its proper position. On being cut open the tumour was seen to consist mainly of a dark brown, somewhat firm blood-clot which was arranged in concentric layers. It measured 3½ inches in width, and was covered externally mainly by the skin and the attenuated layers of the great pectoral

muscle; the blood-clot, which exhibited an irregular internal surface covered by a thin layer of grey clot, formed the wall of a cavity, 2 inches in diameter, which communicated with a similar cavity inside the chest by means of an oblong opening measuring $2\frac{1}{2}$ inches in the horizontal and $1\frac{1}{2}$ in the vertical diameter. Near the ribs this cavity is lined by a firm fibrous membrane $\frac{1}{8}$ inch thick, which is continued into the sac of the second compartment inside the chest wall; it is fairly cylindrical in shape, 2 inches long and $1\frac{3}{4}$ inches wide. This sac is a continuation of the wall of the aorta, about $\frac{1}{20}$ inch thick, its inner surface uneven, yellowish brown, and covered by a thin layer of light brown blood-clot. Where this sac joins the wall of the aortic arch there it is marked off the aorta by a distinct rounded-off ridge, which is $\frac{1}{4}$ inch high and represents the thickened limb of the opening in the aortic arch.

This aneurysmal sac contains in its anterior wall the sternal end of the second rib; this piece of rib is $1\frac{3}{4}$ inches long, and consists of the costal cartilage ($\frac{3}{4}$ inch) and an equally long piece of the adjoining osseous part of the rib; the free end of the fragment is somewhat irregular in shape, but is fairly smooth; the lateral portion of the second rib is not visible inside the aneurysmal sac, it ends just outside the sac; between the two portions of the rib there is a distance of nearly $1\frac{1}{2}$ inches; that part of the anterior wall of the aneurysm in which the rib lies is formed by the intercostal muscles and part of the inner surface of the manubrium sterni.

The ascending and horizontal portions of the aortic arch measure $2\frac{1}{3}$ inches in diameter; their surface is very uneven, covered by numerous atheromatous ulcers and thickened plaques; in the anterior wall of the aortic arch, $1\frac{1}{2}$ inches below the insertion of the brachiocephalic trunk, there is a stiff, fibrous, ring-like foramen, the size and shape of a bean, which leads into a small cavity not much larger than a French bean. The descending aorta is rather narrow, its wall thin and atheromatous.

The aortic valves were atheromatous, shortened and incompetent; the aortic orifice somewhat stenosed. The heart is slightly hypertrophied; the heart muscle pale, greyish red and somewhat friable. Mitral, tricuspid, and pulmonary valves natural.

The kidneys were small and granular. Liver and spleen fairly healthy.

The right lung was universally adherent, the left free; both natural on section.

Points of interest: 1. The size of the whole tumour and of the blood-clot it contains.

2. The size and shape of the aneurysm proper, which is both intra- and extra-thoracic, and contains the sternal portion of the second rib in its anterior wall.

3. The absence of any of the symptoms which usually accompany thoracic aneurysms.

4. Its rapid growth during the last three weeks of the patient's life.

May 3rd, 1898.

---

12. *Circumscribed traumatic aneurysm of innominate artery.*

By George Heaton.

The first specimen I have the opportunity of showing you to-night is interesting owing to its extreme rarity. It is a circumscribed traumatic aneurysm of the innominate artery, which, after existing with very few physical signs, caused sudden death by rupture into the pericardial sac.

The clinical notes of the case are briefly as follows:

W. B—, a male aged 20, was admitted into hospital on September 16th, 1897, in a collapsed condition. Blood was oozing from a small oblique wound above the left sterno-clavicular joint. He had been stabbed about a quarter of an hour previously with a pocket-knife.

Hæmorrhage ceased on admission. In two days he had quite recovered from his collapse, and at the end of six days he was discharged from hospital as convalescent.

On October 5th he was again seized with sudden collapse, which passed off, leaving him slightly feverish, and he was again admitted into hospital.

He looked ill, has some slight irritable cough, and breathed with a loud stertorous noise when asleep. He quickly recovered

again after a few days' rest in bed, and expressed himself as quite well except for stertor at night.

A careful physical examination of his chest revealed an area of dulness under the manubrium sterni. The heart-sounds were quite normal; there was no abnormal pulsation discoverable. The pulses in the right and left radial were equal.

There was no fulness in either side of the neck, no cyanosis, and no evidence of any pressure on the veins of the neck.

An examination of his throat showed that he had very large tonsils, and the laryngoscope showed adductor paralysis of the right vocal cord.

He was advised to have the tonsils excised. This was done under cocaine at midday on October 14th. He walked back to the ward, and during the day expressed himself as much relieved. He was seen asleep at 11.30 p.m. that night, still breathing rather noisily. At 12.50 a.m. he was found collapsed with all the evidence of internal hæmorrhage, and died in a few minutes, twenty-nine days after the injury.

A *post-mortem* was made the following day.

The pericardium was distended with blood, and contained 8 or 9 oz. of blood-clot and serum. There was a rent in its upper part extending into an aneurysmal sac, which lay behind and to the right of the manubrium sterni. The sac was adherent by inflammatory tissue to the back of the sternum.

The specimen which I show you was removed. It consists of the heart and great blood-vessels, with a part of the pericardium, together with the trachea, œsophagus, and the roots of the right and left lungs. The left ventricle has been laid open close to the ventricular septum.

Situated above and a little to the right of the ascending and transverse parts of the arch of the aorta is an aneurysmal sac about the size of a Tangerine orange. Its anterior wall, which was of considerable thickness, has been laid open, and in doing so the left innominate vein which projected into the aneurysmal sac (making it hour-glass in shape) has been cut through. The walls of the cavity are thick anteriorly and thin above and below. They are lined in places with laminated blood-clot.

The aortic arch projects upwards, forming the floor of the sac.

On the posterior wall of the sac and somewhat to its left side is the innominate artery, the external coat of the vessel being covered

with old blood-clot. About ⅛ inch from the origin of the innominate artery from the arch and on its front aspect is an oval aperture leading from the blood-vessel directly into this sac. The long axis of the hole is ¼ inch in length, and lies in the long axis of the blood-vessel; its margins are smooth.

In the floor of the aneurysmal sac is an irregular-shaped rent, ¾ inch long, which leads into the sac of the pericardium just at the line of reflection of the pericardium on to the first part of the arch.

The aneurysmal sac contained recent blood-clot.

Glass rods have been passed through the opening into the innominate artery, and through the rent into the pericardium.

The right vagus and recurrent laryngeal nerves have been dissected out as they lay compressed by the aneurysmal sac and the inflammatory tissue surrounding it.

A circumscribed traumatic aneurysm of the innominate artery is of extreme rarity. I can find no mention of one in any of the authorities I have been able to refer to, though perhaps there may be a specimen of one in some of the London museums.

In the excellent article on "Aneurysm" in Treves' 'System of Surgery' it is stated to be unknown.

Patients have been known to survive several days after wounds of the artery. In Ashhurst's 'International Encyclopædia of Surgery,'[1] reference is made to two cases reported in the 'Medical and Surgical History of the War of Rebellion' (vol. i, Surgical, pp. 520, 521).

One case, a soldier aged 20, lived twenty-four days after a bullet wound which caused sloughing of the coats of the artery.

The other was a soldier aged 26, who lived for six days after a wound ½ inch in length of the innominate artery. *Post mortem* there was a large diffuse traumatic aneurysm.

The fact that the wound was small (¼ inch), and lay in the axis of the blood-vessel, probably accounts for the formation of a definite aneurysm in this case.

The other point of interest in the case is the almost total absence of any definite physical signs of its presence. There was some localised dulness over the upper part of the sternum, and adductor paralysis of the right vocal cord. Apart from this there was no evidence of pressure.

March 1st, 1898

[1] Ibid., vol. iii, p. 224.

13. *Congenital abnormality of sternum and diaphragm; protrusion of heart in epigastric region.*

By F. C. Abbott.

The condition in this child during life was very striking, and more obvious than in the specimen preserved. The specimen was obtained from a male child, who was admitted into hospital when eight weeks old, and died outside one month later.

The preparation was made by Mr. Shattock, but we were unable to retain the other half of the thorax.

Fig. 2.

Vertical section of the thorax, taken to the left of the mid-line, showing the protruding apex of the heart, which lies close beneath the integument below the limit of the thoracic wall. The anterior piece of glass rod is passed from the pulmonary artery into the right ventricle; the posterior, from the aorta into the left ventricle.

The baby was well nourished, and just below the end of the sternum, which was short and apparently possessed no ensiform cartilage, was a very prominent pulsating swelling evidently part

of the heart. The abdominal wall over this swelling was intensely thin and appeared to consist only of skin, and there was thought to be separation of the upper part of the recti. So thin was the wall and the heart so prominent that the ventricles could be picked up between the fingers. They felt stony hard when they contracted, the swelling at the same time becoming more globular.

Much handling greatly upset the cardiac rhythm. The portion of the heart exposed below the sternum measured one and a quarter inches from above downwards and three quarters of an inch from side to side, and in this a double murmur could be heard. There was no other deformity.

During life the heart was thought to be prolapsed through the sternal and costal portions of the diaphragm, with separation of recti and absence of ensiform cartilage.

The specimen shows a vertical section of the body taken just to the left of the mid-line.

The section of cartilage seen above is the first piece of the sternum, that below is the sixth and seventh right rib cartilages coming across the mid-line, the sternum being deficient in its lower part.

The posterior and lateral lines of attachment of the diaphragm can be seen, but its anterior attachment from the abdominal wall is below the lower limit of the specimen. In the mid-line throughout the diaphragm is only fibrous, and there is evident deficiency of muscular fibre for some distance outwards, but it forms a complete septum. The pericardium lines its upper surface.

The narrow conical apex of the heart is formed by the right ventricle, and extends nearly one inch below the seventh rib cartilage.

The cavity seen on the lower side of the heart is the right ventricle, with the right auricle behind it.

A considerable portion of the heart muscle seen on section belongs to the left ventricle, but this does not form the apex. Most of the left ventricular cavity is on the side removed, but a small portion remains on this side, with the large cavity of the left auricle behind it forming the back of the heart.

The anterior surface of the heart is attached by a strong pericardial fold to the anterior abdominal wall, though this may possibly be a strong adhesion produced by the exposure.

There is a very wide separation between the recti in front, the

section of the right one being shown. The anterior abdominal wall between them is composed only of skin and pericardium.

The chief defect appears to be deficiency in the muscle of the upper abdominal wall with want of development of sternum, and downward shifting of the origin of the anterior part of the diaphragm. It thus happens that part of what is usually anterior abdominal wall forms thoracic wall, and behind this projects the long conical right ventricle beating directly under the thin abdominal wall.

December 7th, 1897.

IV. DISEASES, ETC., OF THE ORGANS OF DIGESTION.

1. *A case of sarcoma of the tongue.*

By H. Littlewood.

Sarcoma of the tongue is fortunately a rare affection. In the 'Transactions' of this Society only two cases are recorded, one by Mr. Heath in 1869 and another by Mr. Godlee in 1887. I venture to think its rarity is a sufficient reason for bringing this case before you to-night.

Patient, Joseph M—, aged 17, sent to me by Drs. Ling and Tyrie, of Keighley. He was admitted to the Leeds Infirmary on July 28th, 1896.

Patient was suffering from a growth in the tongue which had so greatly enlarged the organ that it nearly filled the mouth, making articulation difficult, and mastication and deglutition well nigh impossible.

He is a healthy-looking, well-nourished boy, and was quite well until March 21st, 1896. On that date he scalded the dorsum of his tongue whilst eating a hot potato pie. A "sore place" formed which never healed up.

On April 12th he consulted Drs. Ling and Tyrie; at that time there was an ulcer about the size of a sixpence on the dorsum of the tongue. The tongue was greatly swollen, and patient complained of a great deal of pain. Carbolic lotion was ordered as a mouth wash, and pieces of slough were removed from the ulcer two or three times. As there was no improvement in his condition, mercury and iodide of potassium were given; this he took for three months. The tongue steadily increased in size, and glands on the

left side of the neck became enlarged, and later an enlarged gland was found in the right side.

Note taken on admission.—There is a tumour occupying about the middle two-fourths of the tongue. The tip and posterior portion appear not to be involved. The dorsum of the tongue is rounded and practically fits into and fills up the roof of the mouth. He can close the mouth, and when closed the parts below the jaw become more prominent. The tongue can be protruded. The growth is firm, and nowhere appears to fluctuate. An exploring needle was introduced and some blood drawn off. The mucous membrane over the tumour is covered with whitish fur, the part anterior to the growth is clean. There is an ulcerated patch about the size of a shilling near the right of the middle line, and another ulcer on the right side about $\frac{1}{2} \times \frac{1}{4}$ inch, about the level of the teeth. These bleed readily. The breath is offensive, and there is a considerable flow of saliva. At times he complains of great pain. The palate, fauces, and tonsils are free from growth. There is some enlargement of the glands on the left side in the submaxillary and carotid regions, and an enlarged gland can be felt just below the right angle of the jaw.

August 1st. — Operation. Patient under chloroform, a preliminary laryngotomy was performed, pharynx packed with a sponge. The whole tongue was removed by Syme's operation. Patient made a good recovery from the operation; the parts having quite healed, and he was taking food without the assistance of a tube, within three weeks.

On August 23rd seven or eight glands were removed from the left side of the neck, and one gland from the right side.

Description of the parts removed.—The growth was about the size of an orange, and found to involve a greater portion of the tongue than could be ascertained before removal; it appeared to involve the two halves to an equal extent. The parts not being affected are small portions near the tip and base. There is an ulcerated patch, about the size of a shilling, on the outer surface of the right side of the growth near the middle line, and below this another ulcer about $\frac{1}{2} \times \frac{1}{4}$ inch, corresponding to the level of the teeth.

The whole organ was placed in a weak solution of formol for fourteen days, and then divided in the middle line into two equal parts along the dorsum (Fig. 3). The growth had a whitish

appearance, and was of firm consistence. There was a reddish portion in the anterior part, evidently due to blood that had extravasated in the position of the exploratory puncture.

FIG. 3.

A diagrammatic vertical section through the tongue. The lightly-shaded area shows the extent to which the sarcoma involved the organ.

Microscopically the growth is a round-celled sarcoma. It is very vascular; the intercellular substance is homogeneous. The growth in the glands had a similar appearance.

A month after leaving the Infirmary he complained of some difficulty in swallowing. A growth was then noticed in the left tonsil and in the glands on the left side of the neck, below the angle of the jaw.

I saw him on December 12th, 1896. There was then a large growth in the left side of the neck which appeared continuous with a mass of growth in the left side of the fauces; this mass inside the mouth extended nearly across the fauces, so that he could only swallow with great difficulty. There was some enlargement in the glands of the right submaxillary region, and a new growth in the left temporal muscle just above the zygoma. There was no return of growth in the tongue.

Patient died on December 29th, 1896. During the last six weeks of life he was unable to sleep without morphia on account of sharp, shooting pains in the hand. He at times suffered from coughing and vomiting, and during the last four or five days of life he was able to swallow but very little. No *post-mortem* examination was made.

The case recorded is one of round-celled sarcoma of the interstitial variety, involving nearly the whole of the tongue.

Mr. Targett's classical paper in the Guy's 'Reports' of 1890, with a record of eleven cases, is well known. He there gives an account of the first recorded case of sarcoma of the tongue, which was under the care of Mr. Durham, and appeared in the Guy's 'Reports' of 1867. Mr. Heath's is the second case, recorded in the 'Transactions' of this Society in 1869.

'The Annals of Surgery,' 1896, has the record of a case by Dr. Perkins of Utah, which is not included in an exhaustive paper by G. Marion in the 'Revue de Chirurgie,' 1897. This writer has collected twenty-nine cases; three of these he describes as lymphosarcoma, and puts in a separate class. The English pathologists who have described these tumours speak of lymphosarcoma and round-celled sarcoma as being identical.

In the case now recorded the tumour is composed of round cells; the intercellular substance is homogeneous, and not reticulated. The growth appeared to have started after the formation of the ulcer produced by the burn; this ulcer never healed.

It appears very probable there is some direct relation between the ulcer and the genesis of the tumour. *February* 15*th*, 1898.

Report of the Morbid Growths Committee on Mr. H. Littlewood's specimen of sarcoma of the tongue.—We agree with the author that the growth is a medium-sized round-celled sarcoma. It clearly grew with great rapidity, as a number of cells were in a state of active division.

The growth shows extensive hæmorrhage, and might best be described as a hæmorrhagic sarcoma.

W. G. Spencer.
H. D. Rolleston.
Samuel G. Shattock, *Chairman.*

2. *An unusual fistula in the middle line of the anterior part of the tongue, probably congenital.*

By Percy Furnivall.

1. Description of the Case.—(*a*) *Clinical.*—L. S—, a male aged 42, was admitted under my care into the Metropolitan Hospital on June 29th, 1897, suffering from a swelling in the middle line of the tongue.

He stated that he had first noticed a swelling under his tongue "like a pimple" in February, 1896. He went to a hospital in March, 1896, and had it "pricked" and "cauterised" several times. He stated that the swelling varied in size; sometimes it was larger, at others smaller again; at times "matter" came away from it. It was never painful. He refused to go into the hospital and be operated on.

When I first saw the patient in June, 1897, there was an ill-defined, firm lump about the size of a hazel nut, situated in the substance of the tongue, in the middle line close to the tip. It projected slightly from the under surface of the tongue, about half-way between the tip of the tongue and the floor of the mouth.

I could not pass a probe into a tiny whitish papule situated on the centre of the swelling.

Fig. 4.

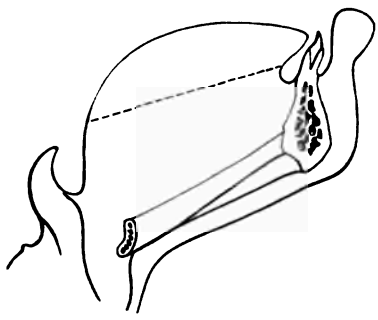

The man was put on large doses of iodide of potassium for two weeks, but the swelling did not alter.

On July 13th I cut into the swelling and found that it consisted

of a mass of fibrous tissue. Thinking that it was a new growth, I excised a V-shaped piece of the anterior part of the tongue. At the apex of the wound that was left, *i. e.* in the middle line of the tongue, I found a round hole. A probe passed along it (Fig. 4) came out at the foramen cæcum. I split the tongue along the middle line, dissected out the fistula, and sewed up the tongue with deep sutures. The foramen cæcum was *not* patent, and nothing abnormal was discovered about the tongue, floor of the mouth, or throat.

The patient made an uneventful recovery.

(*b*) *Macroscopic appearance of the fistula.*—The fistula removed was about 1½ inches long, it easily admitted an ordinary probe, the inner wall was smooth and even; it felt like a vas deferens. The anterior end was surrounded by a mass of cicatricial tissue, probably the result of the cautery which the patient stated had been applied to it.

(*c*) *Microscopical appearances of the fistula.*—A transverse section shows a more or less circular fistula with a lumen about one eighth of an inch in diameter. It is lined by squamous epithelium of the same nature as that of the buccal cavity. Outside this is a layer of loose connective tissue, in which a very small amount of adenoid tissue can be seen. Externally there is a layer of fibrous tissue, which is surrounded by the muscular tissues of the tongue.

2. Development of the Tongue and Floor of the Mouth (mesobranchial area).—In considering the origin of this fistula, it may not be out of place to refer briefly to the development of the tongue and the floor of the mouth.

According to His, the tongue is developed in two parts, (*a*) an anterior and (*b*) a posterior one.

The *anterior* one, which corresponds to the body and point of the tongue, is developed from the tuberculum impar, a rounded tubercle rising in the angular space between the first and second visceral arches.

The *posterior* one, which corresponds to the base of the tongue, arises from a mass formed by the conjoined extremities of the second and third arches on either side. This mass diverges in a V-shaped manner to embrace the anterior part of the organ. At the angle of the V a deep depression, the foramen cæcum, is found.

Now between these three masses which form the tongue there

is a deep sinus, which, according to His, corresponds to the outgrowth of the pharyngeal epithelium in other vertebrates, which is the progenitor of the thyroid gland.

As these masses approach one another the sinus is transformed into an epithelial vesicle, which for some time communicates with the surface of the tongue by means of a narrow duct, the ductus thyreoglossus. As the thyroid gland gradually moves downwards, this duct is lengthened out and converted into a narrow epithelial tube, the ostium of which is always found at the foramen cæcum. As a rule, the foramen is all that is left of the duct, but at times the latter persists more or less. Thus, at times a canal may be traced from the foramen cæcum to the body of the os hyoideum, the ductus lingualis.

Mr. Bland Sutton and Marshall fully endorse His's views.

Kanthack, after careful anatomical researches, is convinced that though the foramen cæcum and the thyroid duct are both developed from the pharynx, they are quite distinct one from the other.

Kostanecki and Mielecki, and Schmidt more recently, agree with Kanthack's conclusions.

3. Ducts or Fistulæ in the Tongue.—In discussing ducts or fistulæ of the tongue one must consider (*a*) *those found posteriorly*, and (*b*) *those found anteriorly*.

(*a*) *Posterior*.—The lingual duct opens at the foramen cæcum, and belongs to the posterior half of the tongue. Cysts in the posterior part of the tongue were regarded as developed from the remains of the embryonic lingual duct, especially by Streckeisen and Bland Sutton.

Kanthack, however, has shown that they are due to cystic changes in the mucous glands opening into the foramen cæcum and its blind cul-de-sac like prolongation.

This has since been more fully described by Schmidt (Dr. Martin B. Schmidt, 'Ueber die Flimmercysten der Zungenwurzel,' &c., Jena, 1896). These are not very uncommon.

There remain to be considered—

(*b*) *Those found anteriorly*, which cannot be thus derived.

I have been unable to find any recorded cases of ducts or fistulæ in the anterior part of the tongue.

The fistula in my case could not be due to a defective union of the first pair of branchial bars, for this does not lead to a fistula but

to a more complicated deformity, viz. cleft lower lip and inferior maxilla, and possibly cleft tongue.

Such deformities involving the tongue, as cleft tongue, must be due to disturbances not only in the first branchial arch, but also in the mesobranchial field of His.

Two possible explanations of the origin of the fistula in my case occur to me:

1. It might be an intra-branchial fistula, *i. e.* between the first and second branchial bars.

2. It might possibly be a cyst of the lingual duct which had burrowed forwards along the middle line of the tongue and burst anteriorly, the lingual duct itself being obliterated, and a fistula left open.

The first explanation seems the more likely one to me, but I am quite uncertain as to what its origin really was.

February 15*th*, 1898.

---

3. *Latent tuberculosis of the tonsil.*

By Hugh Walsham, M.D.Cantab.

[With Plates II and III.]

My attention was first directed to this subject by an address of Dr. G. Sims Woodhead entitled "The Channels of Infection in Tuberculosis." In this very thoughtful and suggestive paper Dr. Woodhead, after reviewing the various ways in which the tubercle bacillus might conceivably gain entrance into the living organism, sums up as follows:

"I am driven to the conclusion that this method of infection of the glands of the neck through the tonsils must be a comparatively frequent occurrence, especially in children living under insanitary conditions, and subjected to various devitalising influences."

On a subject so important I determined to make use of my opportunity as pathologist to the City of London Hospital for

Diseases of the Chest to investigate, as far as possible, if this mode of infection of the glands of the neck through the tonsils really took place. I proposed to make a careful histological examination of the tonsils and follicular glands at the base of the tongue of every case of tuberculosis that came before me for *post-mortem* examination, in the hope that such examination might possibly throw some light on this subject.

My investigations, however, were soon directed into a wide channel by a communication of M. Dieulafoy [1] to the Academy of Medicine of Paris, entitled 'Latent Tuberculosis of the Three Tonsils.' M. Dieulafoy made an experimental investigation to ascertain whether hypertrophy of the tonsils and adenoid vegetations of the pharynx are in any cases of tuberculous nature, and if so, in what proportion. He obtained a number of portions of tonsils and adenoid vegetations which had been removed on account of overgrowth.

Hypertrophied tonsils from twenty-one cases were inoculated into guinea-pigs, and eight of the animals became tuberculous. Adenoid vegetations from thirty-five cases were inoculated, and seven of the guinea-pigs became tuberculous. Thus one in eight of the cases of apparently simple hypertrophy of the tonsils and one in five of the cases of adenoid vegetations were, according to M. Dieulafoy, tuberculous.

M. Dieulafoy's communication met with much adverse criticism at the hands of his colleagues in the Academy, as he had made no histological examination of the portions of tonsils so injected.

It was pointed out that inoculation experiments were open to the objection that virulent tubercle bacilli might be entangled in the mucus of the tonsillar crypts without these organs being necessarily tuberculous, so in addition to the histological examination of the tonsils removed from the dead subject I set myself the task of examining histologically portions of tonsils removed from the living patient, and here I wish to thank Mr. Bowlby, assistant surgeon to St. Bartholomew's Hospital, for his kind permission for me to examine portions of tonsils and adenoid vegetations removed by him in the throat department of the hospital.

At the outset of an investigation such as this, I naturally turned first of all to the classical works of pathology in this country, and here I must admit I met with nothing but disappointment; in fact,

[1] 'Bull. Acad. Méd.,' 3rd ser., t. xxxiii, 1895.

the tonsils seem almost to have escaped the scrutiny of English pathologists.

Drs. Wilks and Moxon in their well-known work write as follows:—"Occasionally tubercles may be found isolated on the palate, tonsils, and other parts of the mouth, commencing as white spots, and then softening until ulcers are formed."

Dr. Coats in his text-book of pathology says, tuberculosis of the tonsils occurs chiefly in connection with that of the epiglottis and tongue.

Dr. Osler in his text-book of medicine says, tuberculosis of the tonsils has been recorded in a few cases.

Professor Hamilton is the only British pathologist who makes any mention of a possible connection between tuberculosis of the tonsils and cervical gland enlargement. He says, "It has even been alleged that tuberculous enlargement of the glands of the neck may be caused by absorption of the tubercle bacillus through the tonsils and analogous structures in the neighbourhood." By analogous structures in the neighbourhood I take Professor Hamilton to mean the follicular glands at the base of the tongue and generally the whole adenoid ring surrounding the entrance to the respiratory and digestive tracts. Prof. Virchow, in his work, 'Die Krankhaften Geschwülste,' has this remarkable sentence. He says, "I know not how it is that tuberculosis of the tonsils has never been observed; perhaps it is only from want of observation. Nevertheless, if it should be ultimately shown that the tonsils are ever affected with tubercle, still the disease must be so rare that these organs must be supposed to enjoy an immunity from this disease." It is far otherwise.

From the text-books of pathology I turned to the *post-mortem* records of the City of London Hospital for Diseases of the Chest. On carefully going through the *post-mortem* books from 1854 to the present time, I find no mention of the tonsils being affected with tubercle, and yet, as my investigations will show, how often must these organs have been tuberculous.

Dr. J. Purves Stewart, in May, 1895, communicated to the 'British Medical Journal' a short paper on the occurrence of giant-cells in the tonsils. The case described by Dr. Stewart appeared to be merely one of ordinary chronic enlargement of the tonsils with pharyngeal adenoids associated with post-scarlatinal otorrhœa and enlargement of the cervical glands in a child aged ten years.

The tonsils were removed. On a naked-eye examination they differed in no way in their appearance from ordinary chronically enlarged tonsil. On microscopical examination, however, the following appearances were found. Scattered through the substance of the lymphoid tissue were large numbers of tuberculous giant-cell systems, apparently most numerous close beneath the epithelial surface of the tonsil. The giant-cells were of the typical multinuclear form characteristic of tubercle, surrounded by the usual epitheloid and lymphoid cells. Staining with Niellson and Gram's method failed to demonstrate bacilli in the sections. The pharyngeal adenoids on section were found free from tubercles. Some enlarged cervical glands were subsequently removed from the same patient, and these on microscopical examination showed definite tuberculosis in various stages of advance, from simple enlargement to caseation.

My subject naturally falls into two principal divisions. Firstly I shall give the results of my examination of the tonsils, cervical glands, and follicular glands of the tongue in cases of tuberculosis that came before me for *post-mortem* examination, and secondly I shall give the results of my examination of portions of hypertrophied tonsils and adenoid vegetations removed from the living patient.

Firstly, post-mortem cases.—In all the cases I am about to describe, with two exceptions, there was nothing during the life of the patient to call attention to the tonsils.

In the majority of the patients the tonsils were atrophied, in only one or two was there anything approaching hypertrophy. There was no complaint of pain or difficulty in swallowing. In short, there was nothing to call attention to the organ. This being so, I have ventured, following M. Dieulafoy, to call this variety of tonsillar tuberculosis latent. Out of thirty-four consecutive *post-mortems* I found the tonsils to be more or less tuberculous in twenty.

I will now give short notes of the cases.

Post-mortem Cases.

1. *Post-mortem,* September 9th, 1895. Henry W—, aged 32. Chronic pulmonary tuberculosis.

Small recent cavity at apex of right upper lobe; a large, much

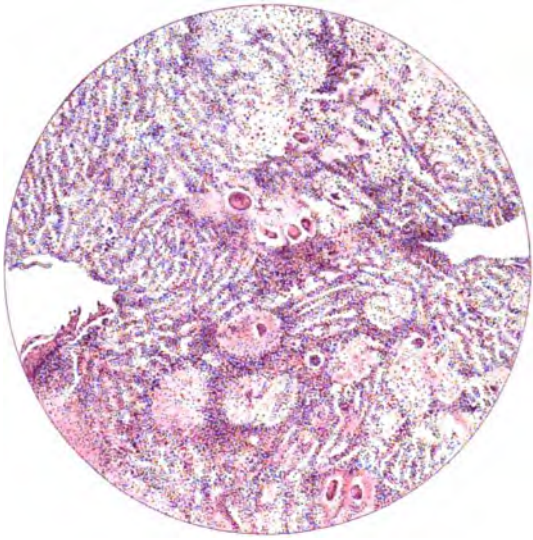

Fig. 1.

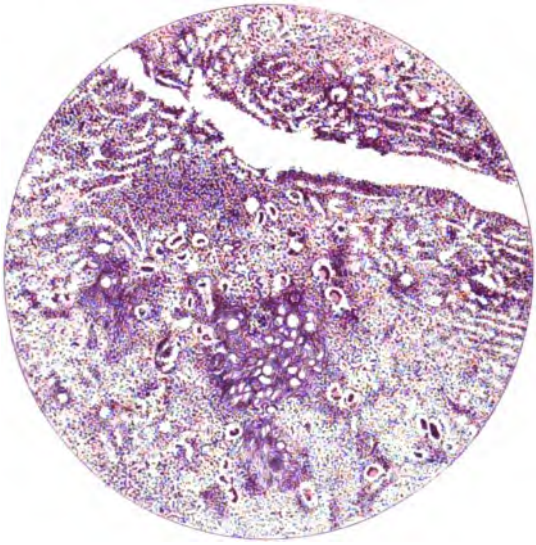

Fig. 2.

Drawn from Nature and Lith. by Bale, Sons & Danielsson, Ltd.

DESCRIPTION OF PLATE [illegible]

[illegible] Dr. [illegible] Walsham's paper on [illegible] Tuber-[illegible]sis of the Tonsil." (Page 67.)

[illegible] Vertical section through the tonsil [illegible] case 1. The [illegible] the tonsillar crypts has [illegible] disappeared. [illegible] of the [illegible] of the tubercle [illegible] remedy [illegible] noticed. (Zeiss [illegible]

[illegible] Vertical section through the tonsil of [illegible] the crypts has disappeared. The [illegible] undergone a fibroid change but there [illegible] scattered throughout the organ. (Zeiss, [illegible]

DESCRIPTION OF PLATE II.

Illustrating Dr. Hugh Walsham's paper on "Latent Tuberculosis of the Tonsil." (Page 67.)

FIG. 1.—Vertical section through the tonsil of Case 1. The stratified epithelium lining the tonsillar crypt has completely disappeared. Numerous miliary tubercles are scattered through the adenoid tissue of the organ. The giant-cells in some of the tubercles are extremely well marked. (Zeiss, obj. A, oc. 2.)

FIG. 2.—Vertical section through the tonsil of Case 2. Here also the epithelial lining of the crypts has disappeared. The tubercular foci appear in places to have undergone a fibroid change, but there are many fresh miliary tubercles scattered throughout the organ. (Zeiss, obj. A, oc. 2.)

older cavity at apex of left upper lobe. Larynx and trachea normal. Ulceration of ileum. Cervical and bronchial glands tuberculous.

Tonsils.—Both tonsils are somewhat atrophied. The stratified epithelium lining the crypts is for the most part desquamated. Miliary tubercle scattered throughout both tonsils. Tubercles very rich in giant-cells—some have undergone slight caseous change. Tongue free. Expectoration slight. T.B. xx.[1]

2. *Post-mortem*, September 9th, 1895. Thomas T—, aged 55. Chronic pulmonary tuberculosis, granular kidney.

Small recent cavity at apex of right upper lobe. Three small cavities at upper part of left upper lobe. Larynx and trachea normal. Bronchial glands tubercular. Few scattered tubercles in ileum, with a few small ulcers.

Tonsils.—Slightly atrophied, much fibroid change. The epithelium lining the crypts is desquamated in parts. Old tubercle undergoing fibroid change with the addition of far more recent tubercle scattered throughout. Expectoration copious. T.B. xx.

3. *Post-mortem*, September 18th, 1895. Sarah B—, aged 36. Acute pulmonary tuberculosis, alcoholic neuritis, granular kidney.

Small recent cavity, size of a Brazil nut, in the middle of the left upper lobe, apex and lower lobe free from tubercle; there is also a small recent cavity, size of a small walnut, at the apex of the left lower lobe. Small and large intestine ulcerated throughout. Larynx and trachea normal. Cervical glands normal.

Tonsils.—Both tonsils free from tubercle. Expectoration *nil.* No tubercle at base of tongue.

4. *Post-mortem*, September 19th, 1895. George H—, aged 52. Morbus cordis, aortic and mitral, miliary tuberculosis of lungs.

Tubercular ulceration of base of tongue, pharynx, and larynx. Both lungs stuffed with grey miliary tubercle from apex to base. Cervical glands enlarged, tuberculous. Extensive ulceration of ileum.

Tonsils.—The left tonsil is completely free from any trace of tubercle. The right tonsil was unfortunately lost. Expectoration *nil.* T.B. x.

[1] The xx denote approximately the number of Tubercle bacilli. xx. In moderate quantity. x. Very few.

5. *Post-mortem*, October 10th, 1895. William S—, aged 38. Acute miliary tuberculosis, caseous supra-renals, no pigmentation.

Both lungs are stuffed with miliary tubercle from apex to base. Larynx and trachea normal. Cervical glands *nil*. Tubercle in kidney and liver.

Tonsils.—Small deposit of tubercle in one tonsil. Giant-cells ill marked. Expectoration very slight. T.B. x.

6. *Post-mortem*, October 22nd, 1895. J. W. B—, aged 39. Chronic pulmonary tuberculosis.

Both lungs contain numerous cavities throughout. Bronchial and cervical glands tuberculous. Extensive ulceration of larynx. Small and large intestine ulcerated.

Tonsils.—Tonsils hypertrophied, crypts very wide. Epithelium desquamated in parts. Small tuberculous foci in one. Expectoration slight. T.B. x.

7. *Post-mortem*, October 3rd, 1895. Thomas R—, aged 50. Acute pulmonary tuberculosis.

Larynx, trachea, normal. Left lung infiltrated throughout with caseous tubercle, no cavitation. The whole of right upper lobe riddled with small cavities. Bronchial glands caseous. Small intestine ulcerated throughout, four ulcers in ascending colon.

Tonsils.—Atrophied; crypts very wide. Epithelial lining crypts intact. Calcified plates scattered throughout both tonsils. Small deposit of epithelial tubercle in one. Much increase of fibroid tissue throughout both. Expectoration not stated.

8. *Post-mortem*, October 24th, 1895. Marie D—, aged 13. Chronic pulmonary tuberculosis.

Larynx, trachea, and bronchi normal. Bronchial, cervical, and anterior mediastinal glands tuberculous.

Lungs.—Numerous old cavities in both lungs.

Small tubercular ulcer on dorsum of tongue. Caseous tubercle scattered through lower ileum. Half a dozen small tubercular ulcers in ascending colon.

Tonsils.—Normal in size; crypts very wide. Epithelial lining to crypts normal. Epithelial tubercle in both. Giant-cells not marked. Expectoration slight. T.B. x.

9. *Post-mortem*, October 26th, 1895. Hadley S—, aged 31. Chronic pulmonary tuberculosis, morbus cordis, tricuspid regurgitation, emphysema.

Larynx and trachea normal. Bronchial glands deeply pigmented, tuberculous.

Lungs.—Old cavity at apex of right upper lobe; cavity small at apex of right lower lobe. Tubercle scattered sparsely through left lung.

Tonsils.—Both tonsils are free from tubercle. Expectoration not examined, as patient died shortly after admission. No tubercle in tongue.

10. *Post-mortem*, October 29th, 1895. Thomas H—, aged 44. Pulmonary tuberculosis, tubercular peritonitis, tuberculous ulceration of pharynx and soft palate.

There is much superficial ulceration of the epiglottis. Small tubercular ulcer about one inch from the tip of the tongue. Ulceration of larynx. Bronchial and cervical glands tuberculous.

Lungs.—Small recent cavity about the size of a cob-nut at the apex of the right upper lobe. Miliary and caseous tubercle scattered through middle and lower lobes. Left lung no cavitation; fresh grey tubercle scattered through upper lobe.

Tonsils.—Both tonsils are almost completely destroyed by tuberculous ulceration; in fact, there is hardly any of the proper adenoid tissue of the organ left.

The follicular glands at the base of the tongue are tuberculous. Expectoration slight. T. B. xx.

11. *Post-mortem*, October 30th, 1895. James M—, aged 30. Chronic pulmonary tuberculosis.

Lardaceous disease of liver, spleen, intestines.

Lungs.—Both riddled with old cavities. Bronchial glands caseous. Laryngeal ulceration. Trachea normal.

Tonsils.—Both tonsils somewhat atrophied, especially the right. Caseous-looking nodules in right tonsil. Tubercle in both. Slight superficial ulceration in left. Expectoration not stated.

12. *Post-mortem*, November 1st, 1895. Rose T—, aged 15. Caseous and calcareous bronchial glands.

Lungs congested, but free from tubercle. Yellowish patch on

each tonsil. ? Diphtheritic membrane, a cultivation taken on solid blood serum. Streptococci and staphylococci cultivated, but no diphtheria bacilli found. With this exception, nothing was found to account for death.

Tonsils.—No tubercle.

13. *Post-mortem*, November 2nd, 1895. William McG—, aged 38. Chronic pulmonary tuberculosis, acute nephritis, laryngeal ulceration.

Bronchial glands caseous. Three very old cavities in right upper lobe. Small cavity in middle of left upper lobe; apex free; no intestinal ulceration.

Tonsils.—Slightly hypertrophied. Epithelial lining of crypts deficient in places. Few sparsely scattered tubercles in both.

14. *Post-mortem*, November 8th, 1895. George T—, aged 39. Chronic pulmonary tuberculosis.

Old fibroid phthisis. Larynx and trachea normal. Right lung is a beautiful specimen of tuberculo-fibroid change. Cylindrical bronchiectasis. Old cavity in right upper lobe. General disseminated tubercle throughout left lung. No intestinal ulceration.

Tonsils.—Much fibroid substitution; sparsely scattered tubercle through one.

15. *Post-mortem*, November 11th, 1895. Benjamin S—, aged 39. Acute pulmonary tuberculosis.

Epiglottis superficially ulcerated. Pharyngeal ulceration. Extensive ulceration of trachea. Five small cavities in right upper lobe. The left lung is infiltrated throughout with tubercle; no cavitation. Few scattered tubercles in cortex of both kidneys. Four or five small ulcers in ileum.

Tonsils.—Atrophy of both tonsils. Crypts contain much broken-down epithelial *débris*. Few tubercles in one.

16. *Post-mortem*, November 13th, 1895. William J. C—, aged 44. Chronic pulmonary tuberculosis.

Larynx and trachea normal. Bronchial and cervical enlarged tuberculosis. Large cavity at apex of right upper lobe. Three small cavities and general tuberculous infiltration of left upper lobe. Calcareous mesenteric glands. No ulceration of intestines.

Tonsils.—Both somewhat atrophied with much fibroid induration Few tuberculous nodules scattered through one. Much expectoration. T. B. x.

17. *Post-mortem,* November 19th, 1895. Thomas J. M—, aged 22. Chronic pulmonary tuberculosis, lardaceous disease.

Larynx and trachea normal. Bronchial glands caseous. Cavity size of a walnut at apex of right upper lobe; much larger cavity at apex of the left upper lobe.

No ulceration of intestines.

Liver, spleen, and kidneys lardaceous.

Tonsils.—Normal in size. Epithelium desquamated in places. Both tonsils contain tubercle. Very little fibroid change.

No tubercle in follicular glands of tongue.

18. *Post-mortem,* November 20th, 1895. Joseph R—, aged 46. Morbus cordis. Adherent and calcified pericardium. Empyema, miliary tuberculosis.

Larynx, trachea, and bronchi normal. At the apex of each lung there are numerous grey miliary tubercles. Bronchial glands enlarged, not tuberculous.

Tonsils.—No tubercle in either tonsil. No tubercle in follicular glands of tongue.

19. *Post-mortem,* December 9th, 1895. Fred P—, aged 32. Chronic pulmonary tuberculosis. Lardaceous disease. Tricuspid regurgitation. Much œdema of lower extremities. No pigmentation.

Old cavity size of a walnut at the apex of the right upper lobe. Few caseous nodules at apex of the left upper lobe. Larynx and trachea normal. Bronchial glands tuberculous. Cervical glands *nil.* Lardaceous disease of liver, spleen, and kidneys. No ulceration of intestines.

Tonsils.—Both tonsils hypertrophied, markedly congested. Epithelium deficient in parts. No tubercle in either. Follicular glands at the base of the tongue very congested, but no tubercle discovered.

20. *Post-mortem,* December 9th, 1895. Bertha C—, aged 19. Chronic pulmonary tuberculosis.

Chronic nephritis (large white kidney). Lardaceous disease. Left upper lobe riddled with small cavities. Cavity at apex of left lower lobe. Caseous and calcified bronchial glands. Larynx and trachea normal. Few caseous tubercles in ileum; no ulceration. Spleen and kidneys lardaceous.

Tonsils.—Tubercle in both tonsils. No tubercle in tongue.

21. *Post-mortem*, November 25th, 1895. Arthur H—, aged 27. Chronic pulmonary tuberculosis.

Ulceration of larynx. Bronchial glands caseous. Cavities in both upper lobes. No intestinal ulceration.

Tonsils.—Both tonsils atrophied; crypts very wide. Tubercle in both. No tubercle in follicular glands of tongue.

22. *Post-mortem*, December 14th, 1895. William N—, aged 39, Chronic pulmonary tuberculosis.

Larynx and trachea normal. Old cavities in both upper lobes. Bronchial and mediastinal glands tuberculous. No ulceration of intestines.

Tonsils.—Atrophied; remarkably wide crypts, some fibroid increase; no tubercle in either tonsil. Tongue is free from tubercle. Expectoration much. T.B. x.

23. *Post-mortem*, December 21st, 1895. William B—, aged 19. Chronic pulmonary tuberculosis, cirrhosis of the liver.

Larynx healthy. Large old cavities in both lungs. Ulceration of ileum. Few ulcers in ascending colon.

Tonsils.—Both tonsils much congested. Numerous tubercles scattered through both.

24. *Post-mortem*, October 10th, 1895. Charles W—, aged 34. Morbus cordis. Double aortic mitral regurgitation. Infarcts in lungs.

Tonsils.—Both tonsils congested. No tubercle.

25. *Post-mortem*, October 9th, 1895. Frederick N—, aged 17. Morbus cordis. Double aortic and double mitral.

Tonsils.—Deeply congested. No tubercle.

26. *Post-mortem*, January 3rd, 1896. Henry S—, aged 8. Gangrene of right lung, pulmonary tuberculosis, pneumonia.

Three small recent cavities at apex of right upper lobe. The apex of the lower lobe is gangrenous and breaking down, and rest of the lower lobe is solid (pneumonic). The left lung—small calcareous patch at the extreme apex of the right upper lobe. No ulceration of intestines. Larynx healthy. Bronchial glands enlarged and caseous.

Tonsils.—Hypertrophied. Very congested. No tubercle in either.

27. *Post-mortem,* February 25th, 1896. John W—, aged 43. Chronic pulmonary tuberculosis.

Perforation of intestine (tuberculous), peritonitis. Both lungs contain much caseous tubercle. Larynx and trachea normal. Ulceration of ileum; one ulcer situated about two inches from ileo-cæcal valve had a large perforation in its floor. Liver tuberculous. Kidneys tuberculous.

Tonsils.—There is some superficial ulceration in the left tonsil. Both the organs, however, are free from any trace of tubercle.

28. *Post-mortem,* William D—, aged 30. Acute miliary tuberculosis.

Old cavity surrounded by dense fibrous tissue at apex of right upper lobe. The rest of the right lung as also the left lung are simply stuffed with grey miliary tubercle. Larynx: right vocal cord almost completely destroyed by ulceration. Under surface of epiglottis is extensively ulcerated. Spleen, kidneys, and intestine contain many miliary tubercles.

Tonsils.—Hypertrophied. Tubercle scattered through both.

29. *Post-mortem,* March 2nd, 1896. Richard P—, aged 41. Chronic pulmonary tuberculosis.

Small ulcer at base of right vocal cord. Superficial ulceration of the soft palate (tuberculous). Bronchial and cervical glands tuberculous. Huge old cavity excavating the whole of the right upper lobe and part of middle lobe. Small cavities more recent in left upper lobe. No ulceration in intestine. Kidneys tuberculous.

Tonsils.—Epithelium lining crypts is deficient in parts. Numerous tubercles scattered throughout both tonsils. No caseation.

30. *Post-mortem,* March 11th, 1896. William D—, aged 24. Chronic pulmonary tuberculosis, pneumothorax.

Cavities in both lungs. Laryngeal ulceration. Trachea and bronchi are thickly set with tubercle. Tuberculous ulceration of both large and small intestine.

Tonsils.—Tubercle in both tonsils, some beginning to caseate. Both organs somewhat hypertrophied.

31. *Post-mortem*, February 21st, 1896. John C—, aged 29. Chronic pulmonary tuberculosis, suffocative hæmoptysis.

Larynx healthy. Bronchial glands caseous. Large cavity at the apex of the right upper lobe. Small cavity in the middle of the left upper lobe, communicating with a large branch of the pulmonary artery. Ulceration of ileum.

Tonsils.—Both tonsils hypertrophied. Both simply stuffed with tubercle.

32. *Post-mortem*, April 19th, 1896. James J—, aged 46. Chronic pulmonary tuberculosis, emphysema, suffocative hæmoptysis.

Large old cavity excavating nearly whole of the left upper lobe. Right lung nearly free from tubercle. Bronchial glands caseous. Larynx not examined. Tuberculous ulceration of lower ileum, caseous tubercle in kidneys.

Tonsils.—No tubercle in either tonsil or tongue.

33. *Post-mortem*, December 11th, 1896. Agnes A—, aged 18. Chronic pulmonary tuberculosis.

Small recent cavity at right apex, caseous tubercle at apex of left upper lobe. No intestinal ulceration. Bronchial glands caseous. Larynx healthy.

Tonsils.—Both tonsils free from any trace of tubercle. Both hypertrophied. No tubercle in tongue.

34. *Post-mortem*, March 4th, 1896. Elizabeth Y—, aged 17. Chronic pulmonary tuberculosis.

Tubercular peritonitis. Perforation of intestine (ileum). Cervical and bronchial glands tuberculous, some calcareous. Larynx and trachea are normal. Large cavity excavating left upper lobe. Small cavity at apex of left upper lobe. Extensive ulceration in lower ileum.

Tonsils.—Both tonsils are tuberculous. No tubercle in tongue.

Fig. 1.

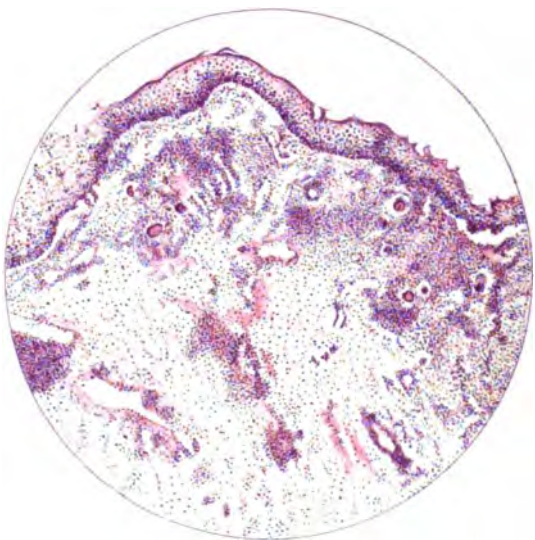

Fig. 2.

Drawn from Nature and Lith. by Bale, Sons & Danielsson, Ltd.

DESCRIPTION OF [illegible]

[illegible] Dr. Hugh W[illegible]
of the Tonsil." P[illegible]

1.—Vertical section th[illegible]
[illegible] normal. There are [illegible]
[illegible] (Zeiss, obj. A, oc. 1.)

2. Vertical section through [illegible] of tong[illegible]
[illegible] and the base of epiglottis. Numerous [illegible]
[illegible]. The lining epithelium of the [illegible]
[illegible] (Zeiss, obj. A, oc. 2.)

DESCRIPTION OF PLATE III.

Illustrating Dr. Hugh Walsham's paper on "Latent Tuberculosis of the Tonsil." (Page 67.)

FIG. 1.—Vertical section through the tonsil of Case 34. The epithelium of the crypt is normal. There are a few miliary tubercles in the adenoid tissue of the tonsil. (Zeiss, obj. A, oc. 4.)

FIG. 2.—Vertical section through base of tongue between the circumvallate papillæ and the base of epiglottis. Numerous tubercles are seen in the adenoid accumulations. The lining epithelium of the tongue is normal; no ulceration is present. (Zeiss, obj. A, oc. 2.)

I think the results of *post-mortem* examinations are sufficient to disprove what is generally held to be true, that the tonsils are very rarely affected by tubercle.

Now what is the significance of these miliary tubercles in the tonsils?

Is the tonsil primarily affected? Are we to suppose that the tuberculous virus may first gain entrance to the human organism by the way of the tonsil, spreading from thence to the cervical and mediastinal glands, and so to the thoracic duct, right side of heart, and lung? Or are we to look upon this tonsillar tuberculosis as altogether secondary, and, in short, auto-infection from the sputum passing over them?

I think both suppositions are true. In support of the first I will take the results of the *post-mortem* examinations of Cases 4 and 10.

In the case of George H—, the primary cause of death here was the aortic and mitral insufficiency. The tuberculosis was altogether secondary. The tuberculous ulcer at the back of the pharynx was very chronic in its course; in fact there were appearances of healing at some parts. Microscopically also the sections show the fibroid character of the tubercle. The infection starting thence from the pharynx gradually spread to the cervical glands, which are found *post-mortem* to be tuberculous. From here we may conceive that the bacilli may reach the thoracic duct and right side of heart, pulmonary artery, and lungs. Now what do we find? Exactly what one would expect: a general shower of miliary tubercle all over both lungs. My *post-mortem* note on the lungs is as follows: Both lungs are stuffed from apex to base with grey miliary tubercle.

This case is, I think, clear and conclusive. The old tuberculous ulceration in the fauces and the fresh grey miliary tubercle in the cervical glands and lungs leads one irresistibly to the conclusion that the primary source of infection was in the pharynx. There could be no question here of the pharynx being infected by the passage over it of sputa laden with bacilli, for, as usually happens in these cases of miliary tuberculosis of the lungs, there was no sputum.

The second case (10) is that of Thomas H—. Here we find tuberculous ulceration of the tonsils and soft palate. The follicular glands at the base of the tongue are tuberculous, although no ulce-

ration is present. Cervical and bronchial glands contain tubercle. The condition of the lungs is much the same as in the former case. We find grey miliary tubercle scattered through both lobes of the left lung, a small recent cavity about the size of a small cob-nut at the apex of the right upper lobe, and the middle and lower lobes containing miliary tubercle, some beginning to caseate.

Here also I think the evidence that the tonsil was the primary source of infection is conclusive. The faucial ulceration was much older than the tubercle in the lung. True, we have a small recent cavity at the right apex, and the tubercle in the right upper lobe had begun to caseate, but I do not think this is evidence against the tonsillar origin of the infection.

These are the only two cases in my series in which the tonsil could be regarded as the primary source of infection.

The next of my cases are two of acute miliary tuberculosis, Nos. 5 and 28. Both of these cases contained miliary tubercle in the tonsils.

In the case of William S— (5) both lungs were stuffed with miliary tubercle throughout. The only caseous focus was in the supra-renal capsules.

Here at first I was at a complete loss to account for the tonsillar tuberculosis. On reflection I think it can only be explained by supposing the infection to have been conveyed to the tonsil, as it is to the other organs, by the blood-stream; that is, that the tonsil does not receive the infection from the outside, but from the blood-current.

In this case the tubercles were very sparsely scattered in the organ.

Case 28 (that of William D—) is a little different. Here the primary source of infection was, no doubt, the apparently old so-called quiescent cavity at the apex of the right upper lobe.

The history appeared to be this: For some unexplained reason this old cavity gave rise to the general dissemination of grey tubercle to tonsils, spleen, kidneys, and intestines, the tonsils being infected, as the other viscera, through the blood-stream.

The remaining cases appeared to be instances of auto-infection, from the passage of bacilli-laden sputum passing over the tonsils. The adenoid tissue of the organs becomes affected in the same way as the adenoid tissue of the Peyer's patches in the intestine and the lymphoid accumulations in the larynx and tongue.

Tubercle as it occurs in the tonsil is generally miliary in character; only very occasionally was there evidence of beginning caseation. In some cases the tubercles were very rich in giant-cells, resembling those found in lymphatic glands; in other cases these cells were absent (epithelioid tubercle).

The tubercles vary extremely in number; they may be thickly scattered all through the substance of the tonsil, or one or two may be all that are found after diligent search through many microscopical sections. Bacilli are generally scanty in number, but may be found if diligently searched for.

How do the bacilli gain entrance to the substance of the tonsil? Can they penetrate the normal intact epithelium lining the tonsillar crypts?

In some of my cases the epithelial lining was in parts desquamated. But this does not appear to be necessary for the penetration of the bacillus. If the tonsillar crypts be carefully examined, search being made over hundreds of sections, places will be found where there are conical lymphoid accumulations first described by Stöhr. These lymphoid accumulations completely obscure the epithelium lining the crypts at these points, but the epithelial cells on careful observation are found to be intact.

There is no doubt that the lymphoid corpuscles wander from the deeper adenoid tissue of the tonsil to the surface. The bacilli, perhaps, enter the adenoid tissue of the tonsil at these spots. Here, being destroyed by the phagocytes, their life history may abruptly come to an end. But if too numerous, victory may be theirs, and the partially destroyed phagocyte may actually form the nourishing material on which they may live and propagate.

What is the connection between the so-called strumous cervical glands and the tonsils? Are the tonsils the primary place of infection in these cases? Is it possible for the tubercle bacillus to be absorbed through the tonsils and so reach the lymphatic glands of the neck without leaving a trace behind them in the organ? I think from my investigations we are justified in answering the first question in the affirmative, and the second in the negative. I think my observations show that the tonsil is an organ very easily infected with tubercle. It was found to be so twenty times out of thirty-one cases of acute and chronic tuberculosis.

I come now to the second division of my subject. I have to

state the result of my examination of the tonsils and adenoid vegetations removed from the living patients.

Here my investigations have been entirely negative. I have examined microscopically many portions of hypertrophied tonsils and adenoid vegetations without finding any trace of tubercle; other observers, however, have been more fortunate. In addition to the observation of Dr. Purves Stewart referred to above, M. A. Pilliet in 1892 contributed a short note to the Société Anatomique of Paris upon the presence of giant-cells in adenoid vegetations of the pharynx, and a very interesting paper by M. Lermoyez in 1894, communicated to the Société Médicale des Hôpitaux, is entitled 'Tuberculous Adenoid Vegetations of the Naso-pharynx.' The following case appears to me to be so important that I quote it at length; it is from M. Lermoyez' paper.

A woman aged 38, married, suffered from chronic nasal obstruction since childhood; she came to the hospital complaining of a purulent discharge from the left ear with deafness; apart from this there was nothing pathological. Husband healthy, three healthy children. She presented a characteristic adenoid facies. Adenoid vegetations were diagnosed and removed. One month after the operation her general condition was found to be very unsatisfactory. She had a cough, night sweats, loss of appetite, and wasting. On examination there was dulness, with prolonged expiration under the right clavicle, and six months later the diagnosis of pulmonary tuberculosis was confirmed. No chest disease was discoverable at the time of the operation.

Now in this case three suppositions are possible:

1. The patient may have been infected at the time of the operation.

2. There was latent tuberculous disease of the right lung at the time of the operation, which developed after.

3. The adenoids were tuberculous from the first, the operation letting the bacilli into the general circulation.

Unfortunately no histological examination of the removed adenoids seems to have been made. The first hypothesis in these latter days of aseptic surgery is not, I think, possible. The second is possible but not probable. The third is most likely.

M. Lermoyez gives a second similar case in a child aged six years. Adenoids were removed. Microscopical examination revealed the presence of giant-cells and tubercle bacilli.

A third case came under my notice in March, 1896, in a young woman aged 17. No family history of tubercle. Adenoid vegetations were removed one year ago. The chest was carefully examined at that time and no physical sign of disease was discovered. Mother living and healthy, father died of morbus cordis; she is the only child. She never quite recovered after the operation. Cough, wasting, and night sweats were marked six months after. On examination the physical signs of a cavity are found at the apex of the right upper lobe.

It is possible, of course, that latent chest disease existed at the time of the operation, but there was no evidence of this. Unfortunately no microscopical or bacteriological examination was made of the adenoid vegetations removed. The following conclusions, I think, are justifiable:

1. That the tonsils, instead of being almost immune from tuberculous disease, are very frequently affected.

2. That tubercle may be primary in the tonsil.

3. That the tonsils are very frequently affected secondarily in persons suffering with chronic pulmonary tuberculosis.

4. That when the tonsils are tuberculous the cervical glands receiving the lymphatics from these organs are also frequently affected with tubercle.

5. That the follicular glands at the base of the tongue are occasionally found tuberculous.

6. That tonsils may be affected from without or through the blood-stream in acute miliary tuberculosis.

The *post-mortem* examinations were, with one exception, made by myself.

The tonsils on removal were at once placed in absolute alcohol to harden.

When sufficiently hard they were cut with Williams' ether freezing microtome and stained in hæmatoxylin and eosin.

In examination for bacilli, carbol fuchsine and methylene blue were used.

Literature.

1. *R. Virchow.*—'Die Krankhaften Geschwülste,' ii, 1864, p. 674.

2. *Dmochowski.*—"Ueber secundäre Erkrankungen der Mandeln und der Balgdrüsen an der Zungenwurzel bei Schwindsüchtigen." 'Ziegler's Beiträge zur Pathol. Anat.,' x, 1891.

3. *Strassmann.*—"Ueber Tuberculose der Tonsillen." 'Virchow's Archiv,' Bd. xcvi.

4. *Schlenker.*—"Beiträge zur Lehre von der Menschlichen Tuberculose." Ibid., Bd. cxxxiv.

5. *Krückmann.*—"Ueber die Beziehungen der Tuberculose der Halslymphdrüsen zu der Tonsillen." Ibid., Bd. cxxxviii.

6. *Dieulafoy.*—"De la tuberculose larvée des trois amygdales." 'Bull. de l'acad. de méd.,' t. xxxiii, 17–20, 1895.

7. *Couvreur.*—'De l'adénopathie cervicale tuberculeuse considérée surtout dans ses rapports avec la tuberculose pulmonaire.' Paris, 1892.

8. *Stöhr.*—"Ueber Mandeln und Balgdrusen." 'Virchow's Archiv,' Bd. xcvii.

9. *M. J. Straus.*—"Sur la presence du bacille de la tuberculose dans les cavités nasales de l'homme sain." 'Bull. de l'acad. de Méd.,' No. 27, t. xxxii.

10. *Starck.*—"Tuberculöse Drüsen im Zusammenhang mit cariosen Zähnen." 'Münch. med. Wochenschr.,' 1896–7.

11. *Buss.*—"Ueber die Beziehungen zwischen Angina und acutem Gelenkrheumatismus." 'Archiv. f. klin. Med.,' liv, 1895.

12. *Ruge.*—"Die Tuberculose der Tonsillen vom klinischen Standpunkte." 'Virchow's Archiv,' Bd. cxliv, Heft 3.

13. *A. Pilliet.*—"Note sur presence de cellules géantes dans les végétations adénoides du pharynx." 'Bull. de la Société anatomique de Paris,' t. vi, Fascicule, No. 8.

14. *Lermoyez.*—"Des végétations adénoides Tuberculeuses du Pharynx nasal." 'Bull. et Mem. Société Médicale des Hôpitaux de Paris,' ii, 3rd série.

15. *Barth.*—'De la Tuberculose du Pharynx et de l'angine Tuberculeuse.' Paris, 1880.

16. *Purves Stewart.*—'Tuberculosis of the Tonsil.' 'Brit. Med. Journ.,' May, 1885, No. 1792.

17. *Woodhead.*—"The Channels of Infection in Tuberculosis." 'Lancet,' 1894, vol. ii.

18. *Gee.*—"On Tuberculous Angina Faucium." 'St. Bartholomew's Hospital Reports,' vol. xi and vol. xii.

19. *McBride and Turner.*—'Edinburgh Med. Journ.,' May, 1897.

Good abstracts of Ruge and Dieulafoy's papers will be found in the 'Brit. Med. Journ.' for June 1st, 1895, and August 1st, 1896, respectively.

4. *Calculous disease of the submaxillary salivary gland.*

By W. G. Spencer.

A girl aged 20 had obstruction of the orifice of Wharton's duct, followed by distension of the duct in the floor of the mouth and inflammation of the submaxillary salivary gland. On freely incising the duct, ropy mucus escaped with small calculi of the size and shape of rice grains. The incision was kept open by passing a probe for a time, during which more calculi of a similar kind were discharged. The patient then let the duct close, causing a return of the distension and of the inflammation of the gland. The duct was reopened under an anæsthetic, and more calculi were scraped out. Finally, on return of the symptoms, the gland had to be excised to avoid suppuration. On cutting across the gland with a knife, calculi were found scattered throughout the section. These consisted of carbonates, and required to be dissolved by acid before a microscopic section could be prepared.

The microscopic sections show inflammation of the whole gland, with dilatation of the smaller ducts. These are filled with inspissated mucus, in which the carbonates were being precipitated.

Since this case I have seen a similar one in a young man under Dr. Dundas Grant, calculi of the above kind being discharged from Wharton's duct.

Doubtless the cause is the same as in the ordinary type, where the almond-shaped calculus is formed within the main duct. But, as an exception to the rule, multiple calculi here arose in the substance of the gland, comparable to the formation of calculi in the substance of the liver or kidney.

November 2nd, 1897.

---

5. *Adenochondroma of the right submaxillary gland.*

By H. J. Curtis.

The case occurred in a lady 24 years of age, who was a private patient of Mr. A. E. Barker's in July 1897.

The swelling below the jaw had been noticed for eight or nine

years, and slowly began to increase in size three years previously to 1897, and apparently following upon the subsidence of a glandular enlargement in the same region due to carious teeth which were extracted.

The tumour formed a prominence below the middle of the right lower jaw. It was very hard and felt the size of a walnut. It moved freely beneath the skin, but a process could be felt extending inwards from its deep surface, and, in fact, on this account the local medical attendant had dissuaded the patient from undergoing an operation for its removal at a much earlier date.

It could also be felt in the floor of the mouth, where it could be rendered still more prominent by external pressure.

In removing it through an incision below the jaws it was found necessary to notch some of the posterior fibres of the mylohyoid muscle so as to free the deep process referred to above.

The wound healed by primary union, and there has been no sign of recurrence though it is now nine months since the operation.

Description of the tumour.—The tumour exhibited is the size of a small Tangerine orange, is nodulated and enclosed in a firm fibrous capsule, to which part of the submaxillary gland is still adherent.

On section.—Pearly white, cartilaginous-looking patches are seen to be scattered throughout the cut surface of the growth, which elsewhere is of a light buff colour and glistening appearance.

Microscopically the white patches referred to are seen to be made of hyaline cartilage containing numerous stellate cells in places pointing to an immature or embryonic condition of the latter.

The only other tissue present in any quantity is the cubical or spheroidal epithelium, which forms solid and more or less branching columns of cells interlacing with those of the cartilage seen everywhere, and also forming tubular acini; in the lumen of some of the tubules secretion can still be seen. All stages intermediate between the solid cylinder of cells and the gland tubules are met with.

The vessels are but few, and there is very little myxomatous tissue.

Microscopic examination of the fleshy or gland-like mass attached to the capsule of the tumour shows it to be typical submaxillary gland.

Diagnosis.—We are here evidently dealing with an adenochondroma of the submaxillary gland such as is far more frequently found in the parotid, and also occurs in the testicle, lachrymal, and mammary glands.

Literature.—In 1896 Mr. Jonathan Hutchinson, jun., brought a case of his own before this Society and referred to others, which I shall quote presently. In the same year appeared an exhaustive paper, occupying seventy-five pages of the 'Beiträge zur Klinischer Chirurgie,' by Küttner, of Tübingen, dealing with "The Tumours of the Submaxillary Gland" generally.

After careful examination of the journals, I think we may conclude that at present there are some twenty-one or twenty-two cases of adenochondroma of the submaxillary gland on record.

Beginning with Continental observers, up to 1879 Nepveu had collected eight cases, and by 1895 Malherbe and Pérochaud mention three or four more, not including the following nine cases recorded in England.

"In 1877," to quote Mr. Hutchinson, "Mr. Butlin described (in the 'Transactions' for 1877) the first example shown at this Society."

In 1890 Mr. Arbuthnot Lane had two cases, and at the discussion of his paper at the Clinical Society Mr. Parkin brought forward three more cases which he had collected from the previous ten years' records at Guy's Hospital; and at the same time Mr. Pearce Gould mentioned one of his own.

In 1896 Mr. Jonathan Hutchinson showed a series of specimens to this Society from the case referred to already.

And lastly, the one shown this evening completes the list of twenty-one or twenty-two cases on record.

But it seems highly probable that many such cases go unrecorded. I hope, therefore, to hear the experience of other members, as it may serve to emphasise the fact that benign tumours identical with those so commonly found in the parotid may rarely, but perhaps less rarely than we have hitherto supposed, be also met with in the submaxillary gland.

April 4th, 1898.

6. *Periœsophageal cyst.* (*Card specimen.*)

By R. G. Hebb, M.D.

The specimen was taken from a female aged 31, who died of heart disease.

The cyst, about the size of a pigeon's egg, was attached to the œsophagus about an inch and a half below the left lobe of the thyroid body, lying in the angle between the œsophagus and trachea, with the recurrent laryngeal nerve passing over it. There was no communication, and no naked-eye evidence of previous association with the œsophagus.

Microscopical examination of the wall of the cyst shows that it is composed chiefly of muscular tissue, and that it is lined by a mucosa.

The muscular tissue is striped and unstriped; externally there is a layer of striped muscle, next to this a single layer of unstriped muscle cut transversely, and next internally are several layers of unstriped muscle, the fibres being arranged parallel to their long axes and to the outline of the cyst. The mucosa consists of two to three layers of cells, the superficial one being columnar ciliated epithelium.

April 19th, 1898.

---

7. *Two specimens of œsophagitis in infants.* (*Card specimens.*)

By T. D. Lister, M.D.

1. Acute Hæmorrhagic Œsophagitis.—A spirit preparation showing a sloughy condition of the mucous membrane of the lower two inches of the œsophagus. There was a thickening, whitening, and loosening of the superficial layers of the epithelium, which appeared in the bleached specimen as an almost membranous, brittle, fissured "exudation," stripping readily from the

roughened surface beneath. In the fresh state this roughened surface had been intensely congested, exhibiting petechial spots on removal of the discoloured shed epithelium.

Abstract of case.—Ethel B—, aged 8 months, was admitted to the East London Hospital for Children on the 24th of February, 1897. She had been seized with acute vomiting without any known cause the day before admission. On admission the child had constant retching with marked unwillingness to suck, and immediate regurgitation after swallowing, and died on February 26th with a slight convulsion.

At the *autopsy* the above condition was found, also slight congestion of the lungs, kidneys, and the cortical vessels of the brain. (Sections of the kidney showed simple hyperæmia.) The vessels at the root of the tongue were plainly visible, but not markedly engorged; the stomach and intestinal mucous membrane were hyperæmic but healthy; there were no other signs of possible chemical or traumatic irritation anywhere present. There was no stomatitis. The exterior of the œsophagus was healthy.

Microscopical preparations.—The superficial epithelium of the œsophagus was in a condition of rapid colliquative necrosis; small irregular spaces containing fibrin threads, red and white corpuscles, and in some cases fibrin threads only, where the corpuscles had escaped, were present in the deeper layers of the stratified epithelium and beneath the epithelium, and a few in the connective tissue of the submucosa. The largest hæmorrhagic spaces were immediately beneath the epithelium, and in parts of the sections formed almost continuous spaces separating the epithelium from the connective tissue. The stratified epithelium exhibited every degree of destructive change, the superficial cells being completely degenerated and broken down, the deepest cells normal. The vessels of the mucous and muscular coat exhibited capillary repletion. The cells of the connective tissue exhibited a marked general proliferation, commencing. Among the *débris* on the surface of the necrosing epithelium were a large number of small staphylococci and a few bacilli (not differentiated). In a very few of the subepithelial hæmorrhagic spaces were present a few threads of a fungus resembling the so-called "*oidium albicans.*" This only occurred in one or two spaces in each section. The spaces varied in size from $\frac{1}{80}$ to $\frac{1}{200}$ of an inch in length, parallel to the surface and $\frac{1}{100}$ inch in depth.

2. THRUSH OF THE ŒSOPHAGUS.—A formalin preparation showing a typical condition of severe thrush of the œsophagus. Scattered in the œsophagus and increasing in frequency from above downwards, until the lower two inches of the œsophagus (where the condition surrounded the œsophagus) were typical raised elliptical plaques, greyish in colour. For the lower two inches the plaques completely covering the interior of the tube formed a rough exudation, arranged in vertical mammillated rows, ending at the cardiac opening of the stomach. This exudation varied in thickness from 1 to 2 mm. It was readily removable from the surface beneath by a strong jet of water, or by stripping with the nail or a blunt instrument. The mucous membrane beneath was of a pale pink colour, and not markedly roughened or eroded.

Abstract of case.—Charles F—, aged 8 months, was admitted to the East London Hospital for Children on the 18th March, 1898, for broncho-pneumonia. For the last sixteen days of life the child suffered also from profuse, offensive, watery diarrhœa. Its temperature ran a markedly irregular course, rising to 106° shortly before death, with symptoms of heart and respiratory failure.

At the autopsy the œsophagus was found to be in the condition described above. There was found: general broncho-pneumonia, with friable breaking-down lung in the most advanced areas of inflammation; catarrhal inflammation of the colon with follicular ulceration, limited to the upper two thirds of the colon. Right side of the heart dilated. Other viscera healthy. No stomatitis apparent.

Microscopical preparations (with a Zeiss D).—On the surface of the mucous membrane of the œsophagus was present a general proliferation of cells replacing the typical epithelium. Among these cells, forming a complete vertical palisade between them, were the mycelial threads very equal in length throughout the section, reaching perpendicularly to the surface everywhere down to the submucous tissue, but only a few threads entering it. At parts of the section, among the surface matting, were present numerous separate oval spores. The ends of the mycelial threads at the surface of the submucosa were mostly clubbed. With a one-twelfth immersion it could be seen that there was irregular staining of granules in the threads, and that they were jointed in segments of very unequal length. The scanty threads that entered the submucosa ended just within its surface. There were no hæmorrhages,

and the connective-tissue cells were not proliferated except in the immediate neighbourhood of the mycelial threads.

REFERENCES.

Acute Hæmorrhagic Œsophagitis.

J. Parrot.—"Muguet de l'Œsophage," 'L'Athrepsie,' p. 215, case of M. Seux.
Zenker.—Von Ziemssen's 'Cyclopaedia,' vol. viii, 1878, case of Gerhardt; Paris, G. Masson, edition 1877.
Heller.—'Deutsche Archiv f. klin. Med.,' lv, 1895, p. 123, Tafel iv, 4.
Osler.—"Acute Œsophagitis in Sucklings," 'Text-book of Medicine.'

Thrush of the Œsophagus.

E. Wagner.—"Zur Kenntniss des Soors des Oesophagus," 'Jahrb. d. Kinderheilkunde' (1868).
Plaut.—'Centralblatt für Bakter. und Parasitenkunde,' i, 527, 1887 (rep.), "Thrush Fungus Identical with *Monilia candida.*"
Rosenberg.—'Centralblatt f. alg. Path.,' iii, 1892.
M. B. Schmidt.—'Ziegler's Beiträge,' viii, 1890 (drawings resembling specimen 2).
Heller.—'Deutsche Archiv f. klin. Med.,' lv, 1895.

---

8. *Sarcoma of œsophagus with secondary deposit in tongue.* (*Card specimen.*)

By G. BROOKSBANK JAMES.

AT the lower end of the œsophagus there is a new growth, white, soft, encircling almost entirely the short axis of the tube for a distance of four inches. Microscope shows large alveoli packed with spindle-shaped cells. Growth in tongue of similar character; also in glands of neck.

History.—Trouble in throat three months; difficulty in swallowing more recently. Bougie could not be passed. Died two days after admission.

May 3rd, 1898.

9. *Carcinoma of the œsophagus which proved fatal by perforation of the aorta.*

By Archibald E. Garrod, M.D.

The patient, a man aged 62, was admitted to St. Bartholomew's Hospital on account of hæmatemesis, and died a few minutes after his admission. At the *post-mortem* examination the œsophagus was found to be the seat of a carcinomatous growth, which had become converted into an extensive malignant ulcer almost surrounding the lumen of the tube, which was not appreciably narrowed. The ulcer had a long diameter of three inches, and its upper border reached to a point five inches below the arytæno-epiglottidean folds. It was most extensive on the anterior aspect of the œsophagus, and was situated behind the bifurcation of the trachea. The margins of the ulcerated surface were nodular, but its central portions had undergone extensive necrotic change. Near its left border the ulcer had extended deeply, forming a channel which communicated with the descending portion of the arch of the aorta. The growth, which had not extended far in any other direction, and did not involve the trachea or other neighbouring structures, was found, on microscopical examination, to be a squamous epithelioma.

The orifice in the aortic wall was linear and irregular (quarter of an inch in length), and was surrounded by a narrow zone of greenish discoloration. In other respects the aorta was fairly healthy, showing only a few pale patches of incipient atheroma.

The stomach was distended with blood-clot, and a large clot filled the lumen of the œsophagus at the level of the ulcer. The duodenum contained a little blood, but the remainder of the intestines were free from clot.

No secondary growths were found in any organ.

The kidneys showed well-marked interstitial change. The liver was fatty. The heart was somewhat hypertrophied, and the mitral and aortic curtains showed some thickening. The metatarso-phalangeal joint of the left great toe contained an abundant uratic deposit.

Although a considerable number of such cases are recorded in

medical literature, perforation of the aorta appears to be one of the least common accidents of carcinoma of the œsophagus, and in a search through the 'Transactions' of the Pathological Society I have not met with any other case of the kind.

April 19th, 1898.

---

10. *A case of columnar-celled carcinoma of the œsophagus.*

By Charles Powell White, M.B.

This specimen is the œsophagus of a man aged 47, who was admitted to the General Hospital, Birmingham, under the care of Mr. Barling early in the present year. The only point of interest in the history is that it was of a very rapid growth.

Immediately above the cardiac orifice of the stomach is a mass of growth two inches long, one inch deep, and one and a half inches wide. It springs entirely from the anterior wall of the œsophagus, and projects into and distends the lumen. It infiltrates slightly the muscular wall, but the œsophagus is not adherent to the surrounding structures except to the diaphragm, which is slightly infiltrated.

The surface of the growth is denuded of epithelium, and in the upper part there is some pigmentation due to old hæmorrhages.

On section the tumour is soft and homogeneous, and yields an abundant exudation on scraping. The growth is limited below by the cardiac orifice, and it does not appear to have originated in the stomach.

A few glands near the cardiac orifice are enlarged and infiltrated with growth, but there are no secondary deposits elsewhere.

Microscopically the growth is a typical columnar-celled carcinoma with well-marked alveoli, lined for the most part by a single layer of columnar cells, though here and there are two or three layers. The lumen of each alveolus is large and filled with mucoid secretion.

A section taken immediately above the cardiac orifice shows the growth invading and splitting up the muscular coat. The tubules are mostly very large, and lined with a single layer of epithelium.

A section of the gland also shows the same character of new growth.

I have only been able to find one case of columnar-celled carcinoma of the œsophagus in the books I have been able to refer to. It is a case described by Newman in 'Malignant Disease of the Nose and Throat,' and quoted by Dr. Rolleston in Clifford Allbutt's 'System of Medicine.' In this case there was no ulceration, and the growth uniformly infiltrated the wall of the œsophagus for the lower three inches. The parts below the cardiac orifice were normal.

April 19*th*, 1898.

---

11. *Perigastric cyst.* (*Card specimen.*)

By R. G. Hebb, M.D.

The specimen was obtained from a male aged 21, who was brought into Westminster Hospital in a moribund condition from concussion of the brain and rupture of the liver and spleen.

The cyst, size of a pigeon's egg, is loosely attached to the cardiac end of the stomach just below the diaphragm.

Microscopical examination shows that its wall consists of unstriped muscular tissue. The wall is well supplied with blood-vessels, and there is much extravasation of blood between the muscle bundles.

There is no very definite arrangement of these bundles, though the general disposition seems to be two longitudinal and one transverse, the latter being sandwiched between the former.

It is lined by a single layer of stumpy epithelioid cells, a few of which are cuboidal.

May 3*rd*, 1898.

---

12. *Stomach showing double perforating ulcer and a perforation of the colon.*

By Charles D. Green, M.D.

The specimen was removed from the body of a single woman aged 22 years, who died after a few hours' acute illness with peritonitis, under circumstances which gave rise to an inquest.

At the autopsy there was acute general peritonitis with extravasation of gastric contents and fæcal matter. On the anterior aspect of the stomach is an oval perforation. On the posterior aspect is a much larger and older perforation; this was loosely adherent to the colon, and the adhesions had to some extent broken down during life. In the colon there is a small perforation, through which mucous membrane prolapsed.

The patient vomited copiously after the perforation, but I did not see her nor any of the vomited matter.

There was a history of "indigestion" and epigastric pains extending over three years. There had never been any hæmatemesis.

The pylorus shows some degree of contraction.

No other disease was found in the body.

April 19*th*, 1898.

---

13. *A case of extreme contraction of the stomach, with some remarks on the pathology of this condition.*

By G. Bertram Hunt, M.D.

This specimen was removed from the body of a man aged 57, who died in Dr. Poore's ward last year in University College Hospital.

The clinical aspect of the case closely resembled that of œsophageal obstruction, there being regurgitation of solid food, while liquids could be taken slowly and with difficulty. There was but occasional vomiting of recognisable food particles, but frequent

regurgigation of clear, sour-smelling liquid of alkaline reaction. Great pain was felt on swallowing at the lower end of the sternum. Emaciation was a marked and rapidly progressive feature of the case. Cancer of the œsophagus was, however, excluded by the easy passage of a full-sized bougie. Gastric cancer was then the most probable diagnosis, but no tumour was felt at any time. The patient died gradually from wasting and exhaustion seven months after the first onset of the symptoms.

The specimen shows the entire stomach laid open, the cardiac and pyloric openings being marked by horsehairs.

Before removal from the body the stomach was drawn right up under the left lobe of the liver, so that it could not possibly have been felt during life. It was found to be converted into a simple tubular organ 5½ inches long, all trace of the normal fundus having vanished. It had a general resemblance to a piece of thick-walled india-rubber tubing, with the external diameter rather less than that of the small intestine. Before being opened the cardiac end would just admit the forefinger, while the tip of the little finger could with difficulty be introduced into the pylorus. The middle of the organ was even more contracted, so much so that a No. 11 English gum-elastic catheter could only just be passed along the lumen. The cavity of the stomach was so reduced that it could not possibly have contained more than an ounce to an ounce and a half of fluid. On cutting the organ open the walls were found to be hard and much thickened, especially at the pyloric end and the centre, the thickness of the wall gradually decreasing towards the cardiac end. The greater part of this was due to increase of the submucous and muscular coats, the mucous membrane and peritoneal coats being affected in a less degree. The gastric cavity was found to be irregular and tortuous in the middle, resembling nothing so much as a strictured or puckered urethra, but towards each end of the organ the cavity was more expanded. In the centre were ulcers, one large and one small, affecting the mucous membrane only, and with no thickening of the edges. These ulcers were evidently secondary erosions of the mucous membrane at the spot where there was the greatest obstruction; they had no resemblance either to the ordinary peptic ulcer or to a malignant ulcer of the stomach. The lower end of the œsophagus was slightly dilated, but the rest of the alimentary tract was normal. There was chronic peritonitis with adhesions in the neighbourhood of the

stomach, and slight signs of general acute peritonitis with a few flakes of lymph over the whole peritoneal surface. The mesenteric and cœliac lymphatic glands were carefully examined, but they were not enlarged, and no trace of growth could be found in them.

At the end of the naked-eye examination I was still in doubt whether it was a specimen of simple fibrosis of the stomach, or one of diffuse infiltrating cancer. Microscopical examination, however, showed that in parts there was distinct evidence of glandular carcinoma in the submucous and muscular layers, the main thickening consisting of a structureless substance through which were scattered isolated cells and bands of poorly defined fibrous tissue; and there was also considerable hypertrophy of the muscular coats. The mucous membrane, except over the ulcerated area, seemed little altered, but there was considerable thickening of the peritoneal coat. The conclusion drawn from the microscopical examination was that the specimen showed diffuse infiltration of the submucous and muscular layers by glandular carcinoma, which had undergone considerable colloid degeneration.

I have brought the specimen before this Society, in the first place, because it seems to be one of the most extreme cases of gastric contraction recorded; in fact, the contraction was so severe that no solid food could pass through the stomach even after mastication, so that the symptoms naturally resembled those of obstruction to the lower end of the œsophagus. Liquid food must have been partly retained above in the dilated œsophagus, and then have trickled slowly through the stomach. The whole of the digestive act must have taken place in the intestines. The only other examples of such extreme contraction that I can find recorded, except a few in the older writers, are both in the 'Transactions' of the Society. One shown by Dr. Shaw in 1891 was an old museum specimen, and the other a case of Dr. Hadden's exhibited in the same year. In both these cases the stomach was apparently about the same size as the present one.

The second and chief reason for showing the specimen is that the cancerous nature of the thickening is unusually evident in this case, so that I hoped that it might serve to raise the still unsettled question whether the thickening in these rare cases is due to a simple fibrosis or to malignant disease. Brinton, who was one of the first to describe this condition, expresses a doubt as to its true nature, although he gave it the name plastic linitis on the

ground that it was a simple chronic inflammatory process. The Germans, as a rule, consider these cases to be malignant, while the French writers usually ascribe the condition to a simple cirrhosis. The growing tendency here seems to be towards the malignant view, as the terms fibroid stomach and plastic linitis are now much less frequently used than formerly.

Dr. Martin, in his recent work on the stomach, considers the majority of these cases to be either diffuse carcinoma or sarcoma, and in two specimens, which have been for years in University College Museum as typical examples of simple fibroid stomach, microscopical sections made by him showed in both undoubted evidence of malignant disease.

Cases of marked gastric contraction, when not due to shrinking following corrosive poisons or large cicatrising ulcer, or to simple atrophy following obstruction to the cardiac or hour-glass contraction, I should urge are in the great majority of cases due to malignant disease, for the following reasons:

First, the clinical history is that of malignant disease, as the condition almost always occurs in elderly or middle-aged persons, and the total duration of the symptoms is short. In eight recorded cases in which the length of the illness is given, together with the present case, and another of which I have notes, the total duration of the symptoms varied from six months to fifteen months, the average of the ten cases being ten months. If it was a condition of chronic fibrosis, often, as has been suggested, due to alcohol, one would expect that gastric symptoms would be present for a long time before such a condition of extreme contraction as the present specimen shows could be produced.

One very striking point in favour of the malignant view which I have noticed on reading the accounts of the published cases is the great frequency with which these contracted stomachs were associated with growths in other organs. This association was found in eleven cases, or in rather more than half of the fully reported examples of this disease that I have met. In two cases there were cancerous nodules in the liver; in two large and hard retro-peritoneal and mesenteric glands; in two a hard mass in the retro-peritoneal tissue; in two others cancerous nodules in the ovary; in one case there was thickening of the peritoneum, on which were scattered a large number of nodules of the size of a pea; in one there was a hard nodular mass in the omentum, and in

one a rapidly growing tumour of the umbilicus. In none of these cases was there any naked-eye evidence of cancer in the thickened stomach, nor did the microscope reveal any in those which were examined, so that the majority of these cases were recorded as simple fibrosis of the stomach, complicated by independent growths in other organs. But the position of the growth in all these cases renders it little likely that they were independent primary deposits; and, in fact, the growths were in exactly those organs—viz. mesenteric glands, peritoneum, omentum, liver, and ovary—as would be secondarily affected in malignant disease of the stomach, and in the absence of any other primary growth they must have been secondary to an unrecognised malignant disease in the thickened stomach.

The thickening of the stomach in several cases involved by direct extension some other organ, especially the transverse colon. This again would be much more consistent with a malignant infiltration than a simple fibrosis.

The position of the thickening, chiefly in the submucous layer, and also the fact that in all cases the infiltration is most marked in the pyloric region, and gradually fades off towards the cardia, resembles the seat and mode of growth of the ordinary malignant affection of the stomach.

The frequency of these cases, as in the present instance, both of localised chronic and general acute peritonitis, is also the same as in the common malignant affections of the stomach.

In the last place, too much stress must not be laid on a negative microscopical examination of the stomach alone: for in some cases many sections may have to be examined before anything indicative of malignancy may be found; and in other cases which have been thoroughly examined nothing of the nature of a growth could be recognised in the stomach itself, although typical groups of epithelioid cells were found in the neighbouring lymphatic glands, as in a case well described by Bret and Paviot. It is only to be expected that, with such extreme contraction of the organ as may be met with, definite groups of cells may no longer be found, and no case can be pronounced to be one of simple fibrosis unless the glands are also examined microscopically. But in the earlier stage of the disease, in which the thickening is confined to the pylorus and before great contraction has taken place, it is much more easy to detect the malignant disease microscopically. Thus in a case in

which there was considerable thickening and contraction of the pylorus alone, which to the naked eye presented no obvious growth or ulceration, and might be described as a hypertrophic stenosis of the pylorus, I found microscopically well-marked evidence of infiltrating scirrhus; and this seems to be the usual result of microscopical examination of these local thickenings.

The conclusion that I have thus drawn from the reports of the recorded cases is that the majority of those described as simple cirrhosis ventriculi, or leather-bottle stomach, were really malignant for the reasons given above; and that great thickening of the stomach is usually, if not always, due to cancerous infiltration.

April 19*th*, 1898.

---

14. *Carcinoma of the pylorus.* (*Card specimen.*)

By Arthur Voelcker, M.D.

The specimen shows a carcinomatous infiltration of the pyloric end of the stomach extending slightly into the duodenum. During life secondary deposits were observed in the skin of the abdomen, the axillary and the left submaxillary glands.

The specimen shows a moderate amount of pyloric stenosis, ulceration of the new growth, and also extensive infiltration of the small omentum and the retro-peritoneal lymphatic glands, the supra-renal bodies, and some infiltration of the pancreas.

The specimen is shown as being the primary growth from which the extensive metastases in the heart were derived. From the same case as the extensive carcinomatous deposits in heart which I have described at p. 33.

October 19*th*, 1897.

---

15. *A case of ulcerative enteritis with perforation.*

By Charles Powell White.

This specimen was taken from a man aged 42, under the care of Dr. Rickards at the General Hospital, Birmingham.

He had suffered for some years with attacks of acute abdominal

pain, sometimes accompanied with diarrhœa. The first attack occurred after the administration of oil of male fern for the cure of tapeworms. The last attack was of five weeks' duration. After admission to the hospital he had three attacks of vomiting. The stools were loose, but nothing remarkable was noticed in them. There was great emaciation.

In the jejunum and upper part of the ileum are a large number of ulcers of different sizes, several of them extending completely round the bowel. The more recent ulcers are covered with a thick false membrane formed by necrosis of the mucous membrane. This membrane is deeply bile-stained. Five of the ulcers have perforated, giving rise to extravasation of the intestinal contents and septic peritonitis; several others are apparently on the point of perforation.

Peyer's patches and the solitary follicles are not enlarged. There are a few slate-coloured atrophic patches in the mucous membrane of the jejunum. The lower part of the ileum and the large intestine are healthy.

Under the microscope the false membrane is seen to be formed by necrosis of the mucous membrane. In it are found numerous bacilli which stain by Gram's method, notably some resembling very closely the diphtheria bacillus.

The mesentery is enormously thickened by enlargement of the mesenteric glands, which are white and firm. Under the microscope they show a large increase of the connective tissue, and an almost complete disappearance of lymphoid tissue.

The spleen and kidneys are normal.

Agar-agar plate cultures were made from the membrane and the mesenteric glands, but resulted only in a pure culture of *Bacillus coli-communis*. A culture from the spleen remained sterile.

March 1*st*, 1898.

16. *Intestinal obstruction following cicatricial contraction of tuberculous ulcers.*

By Charles Powell White, M.B.

These are the intestines of a man aged 52, who was admitted to the General Hospital, Birmingham, under Mr. Barling, in February, 1898.

The history was that of chronic intestinal obstruction. Acute obstruction supervened, and when admitted he was in a collapsed condition, and died shortly afterwards. There was slight emaciation, but the patient was otherwise a well-built man.

There are numerous ulcers throughout the whole length of the intestine; they are irregular in shape, most of them having a tendency to extend around the circumference of the bowel. The bases of the ulcers are slightly thickened.

In the small intestine there are four dense cicatricial strictures. The intestine above each stricture is dilated. The tightest of the strictures is in the jejunum, and will not admit a cedar pencil. Just above this are numerous small ulcers, one of which has perforated and given rise to extravasation of intestinal contents and general septic peritonitis.

The cæcum is extensively ulcerated, and its cavity will only admit a little finger. The ileo-cæcal valve is destroyed, and the appendix is also affected. Just above the cæcum is a cicatricial stricture of the ascending colon. There are a few ulcers in the large intestine. The serous coat of the intestines, except for recent acute septic peritonitis, is smooth throughout, except opposite the sites of one or two of the ulcers, where a few tubercles can be seen. There are no old adhesions in the abdomen, and there were no signs of past or present tuberculosis elsewhere.

April 19*th*, 1898.

17. *Meckel's diverticulum; obstruction of bowels and peritonitis by pressure of pedicle; torsion and strangulation of pedicle; perforation of pyriform extremity and death.*

By J. Tregelles Fox, of Strathpeffer.

This specimen was from a delicate boy of five. No previous illnesses except a nondescript catarrh thought to be in the throat, last summer; but he was habitually liable to pain after meals, for which he would often go and lie down, and he never had a hearty appetite. Family healthy but rather neurotic.

Besides the congenital abnormality of the alimentary canal revealed after death, he was the subject of another developmental defect, cleft palate (the velum only).

The fatal illness began with his usual stomach-ache on October 16th, but he seemed better next day. I saw him first on the 18th; he died early morning on the 22nd. Drs. W. Bruce and (my brother) R. Fortescue Fox were also in attendance.

Briefly to mention the order of the symptoms and the main items of treatment:—On 17th the pain returned much worse than ever, but was completely relieved by a warm bath, in which he played with great glee.

18th.—Vomiting green stuff and bile, and refusal of all food. Attacks of great restlessness, evidently due to colic, began, which were a marked feature. In his contortions he avoided the dorsal decubitus, and preferred to lie on right side throughout. Fever of a septicæmic type, abdominal pain, tenderness, and increased resistance, especially at upper half of left rectus, where dulness was also marked, were observed. Castor oil, given the day before, was supposed to have acted moderately. Rectal feeding, opium, and stimulants were commenced.

19th.—Some improvement in the pain, but the pulse continued to rise in frequency. Rather copious enemata were commenced at long intervals, on the idea that there was a block in the colon overlying small intestine; some grumous offensive mucus was passed as a result, but after one such action the patient appeared to be sinking from collapse.

20th.—Seemed better, slept, though opium was discontinued. Vomited bile once; a dose of calomel and castor oil enemata were administered. Getting worse, opium was recommenced, and brandy increased. One of his paroxysms of pain and restlessness was so violent that he had to be sent off to sleep by a few drops of A.C.E. mixture. Vomiting of bile and of brown mucus continued at long intervals, but *small* liquid normal fæcal stools were passed, in some of which were seeds of gooseberry or raspberry.

21st.—Seemed a good deal better, even the pulse had come down a little, and he began to take a little liquid food by mouth, but sometimes vomited it, especially when it contained brandy. Bowels continued to act slightly (fairly normal liquid fæces). The endeavour was made to feed up (he was greatly emaciated) by beef juice and jelly, peptonised milk, brandy and egg, by mouth if possible, or by rectum. Copious irrigation of the bowel with boric solution was continued about twice daily. In the night the attacks returned with increasing abdominal distension. Opium was resumed, and the abdomen rubbed round with warm camphorated oil, to his apparent relief. (Poppy fomentations had also been used for the pain throughout.)

22nd.—In the early morning hours thirst, clammy sweats, and other signs of collapse came on. He drank greedily small quantities of warm milk and water, with brandy, soda, and ammonia, seldom vomiting it. Holding his swollen epigastrium in his two hands, he tried to get out of bed; and talking a great deal, quite collectedly for the most part. "Who are you? do something to help me," was his last remark. He could swallow no more, and sank at 8.15 a.m.

At the *post-mortem*, in which Dr. Bruce of Dingwall assisted, two vertical coils of greatly distended transverse colon occupied the centre of the abdomen. Under these a tight twisted band was found, behind which some distended coils of small intestine firmly matted together by recent peritonitis, and all of a port wine colour, were compressed against the spine. The body of the diverticulum lay at the left side, near more distended colon, and behind it lay the stomach—very small, but otherwise normal.

One end of the loop of incarcerated bowel formed the attachment of the pedicle and was twisted with it, and also much narrowed, but not absolutely blocked. The other passed under the pedicle and shortly entered the ileo-cæcal valve, which was just

under the liver, near the foramen of Winslow, which was healthy. The remainder of the jejunum and ileum, and the duodenum, were apparently healthy.

The diverticulum was flaccid, nearly empty, its pedicle port wine coloured, but the body exsanguine, its peritoneal coat much destroyed, and a perforation a quarter of an inch in diameter occupying its apex, having been recently formed. Some few flakes of its grumous contents were free in the peritoneal cavity, which was moderately distended by about a pint of clear dark brownish evil-smelling liquid. The mesenteric glands were enlarged; in particular those in the portion of mesentery corresponding to the incarcerated loop were amazingly distended with dark venous blood.

The obstruction to the lumen of the incarcerated bowel seemed not absolute. Certainly it was not at the distal end, next the ileo-cæcal valve, and certainly there was no appearance of distension in the healthy bowel anatomically above it, that is at the point where the diverticulum branched off like the stem of a Y. It may probably have relieved itself into the diverticulum before the pedicle became so twisted. The torsion resembled a ligature in one place, and a little more might soon have twisted it off. Nothing else abnormal being observed, other organs were not examined.

In conclusion, such a case is of interest *pathologically* on account of the association of incompletely developed large intestine and cleft palate, with the permanence of a large pyriform diverticulum, and a practical stricture of the small intestine at its root.

Clinically the difficulty of diagnosis is forced upon one, and the absence of the cæcum from its usual place would make the results of physical examination more doubtful; but it is a lesson to look with suspicion on children with delicate digestion.

Therapeutically it seems to me to point to early surgical exploration in all doubtful abdominal cases. Possibly Hutchinson's "abdominal taxis" might have released the imprisoned bowel in the very early stage, but it is doubtful if this would have done more than put off a fatal issue. But it must be confessed that laparatomy in such a case as this is both difficult and doubtful. Two other recent cases I have heard of and seen, in which the operation was performed; and both the patients died.

January 18*th*, 1898.

18. *Pin perforating the vermiform appendix; periappendicular inflammation; hepatic abscess.* (*Card specimen.*)

By H. D. Rolleston, M.D.

The patient was a girl aged 7 years, who had complained of a stitch on her right side for a year or so. Five weeks before her death signs of right pleurisy developed, and she came under the care of Dr. G. H. Hames, to whose kindness I am indebted for the opportunity of doing the *post-mortem.*

The patient had high fever, and after a time the physical signs pointed rather to an abscess between the liver and diaphragm. She was operated upon several times by Mr. Charters Symonds, and pus was let out from the substance of the liver, which, when examined bacteriologically by Dr. Pakes, was found to be sterile. During her illness she was also seen by Drs. F. Taylor and Goodhart. Death took place from asthenia. After death there was some slight jaundice.

At the autopsy the vermiform appendix was found to be firmly united to the right broad ligament by old adhesions, and to be surrounded by recent fibrinous peritonitis. On opening the cæcum the proximal end of the appendix was patent and widely open. The appendix was cut up, and at the point where it was so firmly adherent to the broad ligament a pin was found with its head inside the tube, lying transversely to the long axis of the appendix. The shaft and tip of the pin after passing through the wall of the appendix were surrounded by old adhesions. The whole of the pin was irregularly encrusted with calcareous salts.

The appendix was pervious for about a quarter of an inch distal to the situation of the pin, and then became impervious. This part was so firmly buried in adhesions that the point of its termination could not be definitely made out.

Except for the perforation, the inside of the appendix was free from ulceration and did not present any manifest lesion. Besides the intense peritonitis in the pelvis there was some scattered lymph in the peritoneal cavity, and some yellow effusion.

The portal vein was quite healthy, and no sign of phlebitis or thrombosis could be found either in its tributaries or in its

divisions in the liver. The glands in the portal fissure were enlarged.

The liver was much enlarged; in the right lobe, in its upper and posterior part there was a loculated area of suppuration as large as one's fist, which had been partially opened during life. The loculi contained somewhat gelatinous pus. There were spreading foci of suppuration in the right lobe near the suppurating area, but none in the left lobe. The diaphragm was eroded over a limited area by the pus, and a cone-shaped depression in the right leaflet was found corresponding to the abscess. The diaphragm was pushed up as high as the third rib, and the lower lobe of the right lung had fibrinous exudation on its pleural surface and was collapsed.

The rest of the liver was of a bright yellow colour, suggesting acute atrophy or phosphorus poisoning. In places there were firm white areas, resembling the appearance seen in anæmic infarcts in the kidney. Microscopically thére was necrosis of the liver cells and evidence of coagulation necrosis.

The gall-bladder and bile-ducts were normal.

Remarks.—The occurrence of pins in the vermiform appendix has been noted before. Kelynack [1] refers to five examples recorded by Morrant Baker, Ashby, Boussi, W. Legg, and Mestivier. Dr. Payne [2] also published a case, and Dr. W. S. Colman has kindly told me of one that came under his notice. J. E. Graham [3] figures a pin in the vermiform appendix which gave rise to pylephlebitis, and to an hepatic abscess perforating into a large bronchus. Since this specimen was shown to the Society I have seen the record of a case of fatal appendicitis due to a pin in the appendix of a girl aged six years. [4]

In the present case the tip of the pin had probably ulcerated out of the appendix a considerable time before the onset of the acute symptoms, as shown by the firm adhesions uniting it to the right broad ligament. One is indeed inclined to associate their presence with the "stitch," from which the patient had suffered for a year previously.

[1] Kelynack, 'The Pathology of the Vermiform Appendix,' p. 66, 1893.

[2] F. J. Payne, 'Trans. Path. Soc.,' vol. xxi, p. 231.

[3] J. E. Graham, Loomis and Thompson's 'System of Practical Medicine,' vol. iii, p. 462.

[4] D. McM. Officer, 'Intercolonial Medical Journal of Australia.' April 20th, 1898, p. 229.

The acute infection which supervened probably gained an entrance through the damaged walls of the appendix, and thus gave rise to the suppuration in the liver.

That this sequence really took place is not, however, clear, for there was no pylephlebitis, and the appendix was not ulcerated except where it was perforated. Given, however, a lesion in the appendix, it is more rational to regard this as related causally to the suppuration in the liver than to believe that the two lesions are independent.

If, then, the suppuration in the liver was secondary to the appendix, how did the infection spread? Possibly a small embolus passed up from the appendix into the liver, although no evidence of phlebitis of the mesenteric or portal vein was evident. Another possibility is that infection passed through the lymphatic vessels accompanying the mesenteric vessels, and that while on the way to the thoracic duct the infection spread to the liver. Of this latter hypothesis there is no proof, for the enlarged glands near the portal fissure were probably due to infection brought by the efferent lymphatics leaving the liver there. The first hypothesis is, on the whole, more probable.

In the twenty-first volume of the Society's 'Transactions' Dr. Payne published an analogous case. There was a pin in the vermiform appendix, and one large and several small abscesses in the liver, and in addition an abscess in the upper lobe of the left lung. The portal vein and bile-ducts were quite healthy. This case resembles my own in the absence of any pylephlebitis.

May 3rd, 1898.

---

19. *A case of intussusception of the vermiform appendix.*

By Herbert F. Waterhouse.

This specimen was obtained from a little girl, Annie B—, 4 years of age, who was sent by Dr. C. J. Harrison into the Victoria Hospital for Children, under my care, on July 18th, 1895, with the diagnosis of intussusception. Five days before admission the child was examined by us both under chloroform, on account of an intus-

susception on the right side of the umbilicus. During the manipulation under the anæsthetic this tumour suddenly disappeared.

On the evening of the 17th all the symptoms, pain, vomiting, &c., reappeared in an aggravated form, and the intussusception on the right side of the abdomen was again clearly to be felt.

On the 18th the child was admitted into the Victoria Hospital, and attempts were made to reduce the intussusception by enemata. The second enema on its return was found markedly blood-stained. As the child's condition was rapidly becoming worse, I opened the abdomen, and immediately came upon an intussusception of the small intestine (ileum) four feet above the ileo-cæcal valve. This was reduced without much difficulty. As it was lying transversely it was obvious that it was not the intussusception previously felt, which was vertically placed on the right side. This latter was soon found. It was a large ileo-colic intussusception, which was reduced only with extreme difficulty, yielding bit by bit. When this intussusception was at last reduced it was observed that the cæcum contained a firm globular body about one inch in diameter. Only half an inch of the vermiform appendix was visible externally, and it was obviously in direct continuity with the globular mass in the cæcum.

Though I was unaware previously of the existence of the condition, there was no doubt in my mind that I had to do with an intussusception of the vermiform appendix. Its reduction was found to be impossible, and during vigorous attempts at expressing it the tumid wall of the cæcum gave way, and the partially gangrenous appendix was seen in its interior. The child's condition at this period was so precarious that it was necessary, if she were to leave the operating theatre alive, to finish the operation with the utmost expedition. The cæcum was therefore excised, and the ileum and ascending colon united rapidly by Murphy's button. The entire operation lasted just under one hour. The child, who was all but pulseless at the conclusion of the operation, lived only thirty hours, never recovering from her state of collapse.

Post-mortem examination showed that the junction of the large and small intestines was water-tight, and that there was no trace of peritonitis.

The specimen, which is now in the museum of Charing Cross Hospital, shows on the inner surface of the cæcum the invaginated

portion of the appendix as a globular mass three quarters of an inch in length, and 2⅛ inches in circumference at the widest part, with a somewhat constricted neck 1¾ inches in circumference. The portion of the appendix outside the cæcum is only five eighths of an inch in length. Dr. William Hunter, the curator of the museum, to whom I am indebted for these measurements, adds, "Neither by traction from without nor by pressure from within can the intussuscepted appendix be reduced."

Intussusception of the appendix must be a condition of considerable rarity.

The following are the cases of intussusception of the vermiform appendix previously noted:—Greig Smith, 'Abdominal Surgery,' vol. ii, p. 678; Bernard Pitts, 'Lancet,' 1897, vol. i, p. 1602; G. A. Wright and K. Renshaw, 'British Medical Journal,' 1897, vol. i, p. 1470; McGraw, 'British Medical Journal,' vol. ii, 1897, p. 956; J. McKidd, 'Edinburgh Medical Journal,' 1859, and W. Chaffey, 'Lancet,' 1888, quoted by McGraw.

February 1st, 1898.

---

20. *Cystic dilatation of vermiform appendix.* (*Card specimen.*)

By Alexander G. R. Foulerton.

The specimen was met with accidentally during the performance of a cœliotomy on a young woman for the relief of an extra-uterine gestation. The dilated appendix had not caused any symptoms, nor had its existence been recognised. The dilated portion of appendix was attached to the cæcum by a short narrow neck, the lumen of which was entirely obliterated. It formed a tense uniform sausage-shaped tumour, with a translucent wall measuring 8·2 cm. in length and 6·5 cm. in circumference. The cavity was filled with clear colourless mucoid fluid, and did not contain any solid bodies. The meso-appendix extends along the length of the organ to its tip, and is considerably thickened by the deposition of fat between its layers.

January 18th, 1898.

21. *A cyst removed from the inside of the cæcum.*

By C. A. Morton.

The cyst was removed from the interior of the cæcum of a man, aged 39, by operation. On opening the cæcum a fluctuating swelling the size of a hen's egg was found projecting into the bowel for one and a half inches. It was attached to the cæcal wall where the appendix was attached, only on the inside. Its surface was red and soft like velvet, and the mucous membrane of the cæcum terminated around it in the form of a ridge. The wall of the appendix was much thickened, and the whole tube was densely adherent to the under surface of the cæcum. Only its extremity was distended with fluid, beyond a point where the lumen was constricted. I removed the cyst (with as little of the surrounding cæcal wall as possible) together with the appendix.

On cutting open the cyst I found the wall about one eighth of an inch thick, and the interior was lined with a soft layer of tissue, on which were numerous white patches, some of which were distinctly calcareous. The contents consisted of an amber-coloured jelly, so thick that it had to be washed out with a forcible stream of water. A minute opening was found from the cyst into the lumen of the appendix. It was too small to admit an ordinary probe.

Microscopic examination of the cyst shows that the wall is composed simply of fibrous tissue, and that it is quite distinct from the wall of the cæcum.

That it was not formed by the occlusion of the lumen of the appendix, as it passed through the cæcal wall at two points with cystic dilatation between them, is shown by the absence of mucous membrane on the cæcal aspect of the cyst; for if the cæcal opening of the appendix had been simply occluded, and the lumen dilated, the cyst wall as it projected into the cæcum would have been covered with the mucous membrane of the cæcum. I do not lay stress on the absence of mucous membrane lining the cyst as evidence against the origin of the cyst in a dilatation of the cæcal end of the appendix, for it might atrophy and finally disappear as the cyst enlarged.

In the other end of the appendix there was some retained mucous fluid, but the condition did not in the least resemble the cystic formation at the cæcal extremity.

It seems to me that the cyst is not a retention cyst of the appendix, but its origin is, I think, uncertain. I can find no record of any similar cyst.

December 7th, 1897.

---

22. *Perforating ulcerative colitis in a lunatic.* (*Card specimen.*)

By Cecil F. Beadles.

Ulcerative colitis is so common a lesion in lunatics that little interest attaches to a single instance, although the mere frequency of this disease in the insane cannot, until an explanation is forthcoming, but be regarded as of some importance from a medical point of view.[1] Moreover perforation of such a bowel is common enough. The interest in the present case lies in the extensive destruction of the wall of the transverse colon, by which the anterior wall of the gut has almost disappeared for a length of about nine inches, and this without the existence of any marked peritonitis, and with no distinct evidence of such an occurrence during the life of the patient.

The patient was a female lunatic aged 66, who had been insane since fifty-two years of age, with recurrent attacks of mania with delusions.

In July, 1896, she was transferred to Colney Hatch from a provincial asylum. Her mental faculties were dull, and she was bordering on dementia, but she made herself useful with needlework. Her bodily health seemed good, although she was abnormally stout.

In the early part of 1897 she had an attack of diarrhœa, and again in July, when she was confined to bed for a few days. Her fatal attack commenced on October 22nd.

For nearly three weeks diarrhœa was almost continuous, and no drugs appeared to have the slightest effect in checking it. At first

[1] The 'Journ. Ment. Soc.,' July, 1898, by Dr. A. W. Campbell.

the motions were of the usual character of simple diarrhœa, but about October 29th they changed to a dark grey colour with an exceedingly offensive smell, continuing so until November 9th, when she died. During this time there was occasional vomiting, and the vomit during the last few days resembled liquid motions. The temperature was of an irregular hectic type, in the morning between 97° and 99°, and in the evening rising from 99° to 101° in a jerky manner. Her diet consisted solely of milk and rice. She seemed to suffer extremely little pain; there was no particular tenderness of the abdomen; her countenance portrayed no serious illness. Throughout the whole time she was usually in a drowsy state almost amounting to stupor. During the last three days she lay almost pulseless, her hands cold and clammy. Abdomen seemed somewhat swollen, but palpation revealed nothing.

At the *autopsy*, thirty hours after death, there was found slight chronic congestion of the peritoneal covering of the intestines, but no fluid or lymph in the abdomen, and no adhesions. There was a great excess of fat both on the parietes and within the abdominal cavity. The omentum and mesentery formed masses of adipose tissue, and the appendices epiploicæ were greatly enlarged. On raising the mesentery grey feculent matter escaped from the transverse colon, the wall of which for a considerable distance was almost absent, its contents apparently having been kept in solely by pressure exerted in front by the unusual amount of fat, for no peritonitic adhesions existed.

The intestine examined after removal was found filled with grey semi-liquid putty-like material throughout the large bowel and the lower half of the small bowel. The large intestine was ulcerated throughout from the cæcum to the rectum, including both these portions, the ulcers being of an irregular eroding character with sharp edges. A perforation existed through the ascending colon two inches above the ileo-cæcal valve, and, as above mentioned, there was most extensive perforation along the transverse colon, commencing eight inches above the valve and reaching for nine inches along the gut. Here almost the entire anterior wall had given way, there being only a few narrow bands of necrotic tissue stretching across.

Slight constriction of the gut existed at the commencement of the sigmoid flexure. There was no ulceration of the lining within the small intestine.

The stomach was dilated, and towards the pyloric end was an old circular ulcer the size of a sixpenny piece, with thickened edges. The liver, which was much enlarged, weighed 63½ oz. It was exceedingly soft, greasy, and dark on section. The gall-bladder small, and tightly contracted over a collection of minute calculi and pigmentary biliary deposit, which also completely filled and occluded the cystic duct. Spleen enlarged, weighing 7½ oz. Heart dilated, and covered by much fat.

November 16*th*, 1897.

---

23. *Ulcerative colitis.* (*Card specimen.*)

By Arthur Voelcker, M.D.

The specimen shows the lower part of the ileum, and the large intestine except its lowest three inches.

The whole of the mucous membrane of the large intestine is affected. In great part it is destroyed, the bare portions being especially evident along lines corresponding to the tæniæ. The surviving mucous membrane is much thickened and polypoid. There is no perforation, no excess of fat around the bowel, and no sloughs are seen on the mucous membrane.

The mucous membrane in the cæcum and at the lower end of the rectum was, in the fresh state, purple in colour.

The ileum presents four ulcers or groups of ulcers, the three lowest occurring in Peyer's patches.

One ulcer in the ileum shows a raised islet of purple mucous membrane with steep walls, around which the mucous membrane is quite destroyed, and presents the same appearance which the ulcerative process produces in the colon.

By the kindness of Prof. McFadyean, a portion of the ulcerated colon was given to a pig, which was subsequently killed, and presented none of the appearances resembling those found in swine fever.

From a woman aged 29, who was admitted for diarrhœa into the Middlesex Hospital under the care of Dr. Cayley.

October 19*th*, 1897.

24. *A "tumour" of the ascending colon.*

By Raymond Crawfurd, M.D.

This tumour seemed to me one that should be brought before the Society, both because of its singular configuration and its histological structure. The salient points of the clinical history throw some light on its morbid anatomy.

C. C—, a farrier aged 58, was admitted to the Royal Free Hospital on December 13th, under the care of Dr. West. He was quite well until the middle of October, when he was suddenly taken with severe pain in the lower part of the abdomen. The severity of the pain soon passed, so that he was able to remain at work till the beginning of December. Then a fresh attack of pain with exhausting vomiting set in, and persisted on and off up to his admission to hospital on December 13th. He was brought in in a state of collapse; every few minutes a spasm of abdominal pain set in, accompanied by persistent belching of wind. On the following day this note was entered on the case sheet:—"Abdomen: the muscles are tense. There is tenderness in the right iliac and lumbar regions. Dulness is present over an area about the size of an orange, situated in the umbilical region. Here an elastic, hard, pulsating but not expansile tumour can be felt, reaching about one inch to the right of the umbilicus and about the same distance below it; the boundary on the left side is not clearly defined. There is tenderness over the tumour on pressure." For the first few days in hospital he was fed on fluid food by the mouth, and though the eructation and vomiting persisted the pain became very much less; the bowels were open naturally about every other day, and an occasional enema was used.

Up to January 7th there was steady improvement; no vomiting, no flatulence; bowels open satisfactorily, but the tumour was still as before. On January 7th vomiting and pain returned, and gradually increased each day during the next week, so that very little food was kept on the stomach; the bowels acted naturally and regularly each day up to and including January 12th.

On January 13th and 14th he seemed better, but it was noted that the tumour was distinctly larger.

On January 15th, at about 9 a.m., he was suddenly seized with violent abdominal pain and collapse, and in spite of stimulants was dead in ten minutes.

At the *post-mortem* on January 16th I found the abdomen full of fluid food that had a feculent odour. The peritoneum was markedly injected, but there was no lymph. A rent was found in the small intestine about three inches from the ileo-cæcal valve; the rent was lying at the lower and inner part of the right lumbar region, and above this and a little internal to it on the border of the right lumbar and umbilical regions was an intussusception tumour. The cæcum, vermiform appendix, and about four inches of the ileum were drawn directly down into the ascending colon, so that the rent was just under cover of the colon. The ileum was very little, if at all, distended above the intussusception. The intussusception was tight, but readily reduced, as there were no adhesions between its layers; the intussusception, more particularly the cæcum, was deep red in colour, much thickened, and had a doughy feeling on pressure. A few inches below the intussusception was a tumour growing from the wall of the ascending colon, and projecting into its lumen. The tumour was much the shape of a hen's egg split in half from end to end, and with its flat surface attached to the gut; it was three inches in its greatest length, and two inches in its greatest width and depth. The surface of the tumour was chocolate-coloured and smooth, though divided up into six rounded ridges; its consistence was firm and very elastic. These ridges obviously corresponded to the normal folds of the mucous membrane. On section both of the tumour and of the cæcum, nearest to the surface was a broad band of deep brown colour; below this a thin bluish-white line, perfectly regular and unbroken; and below this another narrow band of deep brown colour up to the serous coat. The appearance, in fact, was very much like an onyx stone, or, to use a more homely simile, a striped brown bull's-eye. Subsequent examination has shown that the thin line was the muscular coat of the bowel, with the mucous and submucous coat on the one side, and the serous and subserous on the other. On the outer surface of the bowel there was no noticeable depression, such as has appeared since the specimen has been preserved by the formalin method. The rest of the intestines were healthy.

Taking the *post-mortem* findings along with the clinical evidence,

it is pretty certain that the tumour was the initial trouble; it clearly did not completely obstruct the bowel until January 12th; then seemingly occurred the intussusception, which accounts for the sudden enlargement of the tumour and the subsequent constipation. Finally on January 15th the small intestine gave way, and death followed immediately.

Microscopical sections were taken from the edge of the tumour, and were carried right through the wall of the bowel. Naked eye, the bundles of longitudinal muscle fibres can be seen to be widely separated from each other; the fibres themselves are in an advanced state of degeneration, as may be seen with the microscope. The whole submucous coat is replaced by fibrin entangling a greater or lesser number of blood-cells; there is, in fact, a hæmorrhage into the submucous coat. The mucous membrane at the site of these sections is also necrotic; in other portions the mucous membrane is apparently healthy. A noticeable feature is the size of the vessels in the submucous coat; this seems to be due to loss of their supporting tissue.

The question I would put to the Society is as to the origin of this effusion of blood: have we to deal with an unusual form of hæmorrhagic infarction, or how else can the condition be accounted for?

March 15th, 1898.

Report of the Morbid Growths Committee on Dr. Raymond Crawfurd's specimen of tumour of ascending colon.—To the author's description of the macroscopic appearances we have nothing to add; a longitudinal section of the entire "tumour" shows that this is due mainly to a swelling of the submucous tissue, which attains an extreme thickness of three-eighths of an inch.

We do not, however, regard this swelling as the result solely of extravasation of blood, as the author apparently infers, but we attribute it to œdema associated with rupture of vessels, the fibrinous network in the distended submucous tissue being chiefly a coagulum of transuded plasma. We agree with the statement that the swelling in question is identical in nature with that of the cæcum where it formed the head of the intussusception; but that it is independent of this intussusception appears from the fact that when the parts are fully reduced, an interval of nearly a foot intervenes between the swelling of the cæcum and that within the

colon. The two swellings are, however, so similar in all respects, and the latter is so remarkably localised, that we are of opinion it represents the head of a second (lower) intussusception.

This opinion is supported by the fact that the colon beyond the second swelling is obviously dilated for some inches and afterwards abruptly regains its proper dimensions,—a disposition which can only be explained by supposing a second intussusception has escaped observation in consequence of its reduction.

We do not consider the swelling in the colon to be a neoplasm, and it should not, therefore, be designated by the technical appellation of a tumour.

SAMUEL G. SHATTOCK, *Chairman.*
J. H. TARGETT.

---

25. *A case of intestinal obstruction due to induration of the great omentum.*

By T. A. BOWES, M.D. and CHARLES POWELL WHITE, M.B.

THIS specimen was taken from the body of a man aged 66, who was admitted to the Infirmary at Herne Bay in June, 1895, for tertiary syphilitic ulcers on the leg. He had also had ulceration of the forehead, and exfoliation of the outer table of the frontal bone. He had occasional vomiting during his stay in the infirmary, and for some months previous to death he was very constipated. Symptoms of chronic intestinal obstruction developed gradually at the end of 1897, and he died on January 12th, 1898. During life an ill-defined deep-seated resistance could be felt crossing the abdomen above the umbilicus.

Post-mortem.—There was some amount of recent peritonitis. The large intestine was empty. The omentum surrounding the transverse colon was extremely indurated and thickened, and its contraction had been such that the lumen of the colon for a length of six inches only just admitted an ordinary penholder. The stomach was closely adherent to the colon. There was no sign of malignant disease.

Microscopically the omentum shows great increase of fibrous

tissue, and here and there are small patches of granulation tissue. There is a very large increase of fibrous tissue in the walls of the colon, and some thickening of the muscular coat.

May 17th, 1898.

---

26. *Carcinomatous stricture of sigmoid flexure.* (*Card specimen.*)

By Cecil F. Beadles.

This specimen is a little unusual in that there is a malignant stricture of the sigmoid flexure as it passes over the brim of the pelvis, without the presence of any marked growth.

The patient was a female lunatic aged 81, with the usual signs of senile dementia of eighteen months' duration. She was feeble, childish, with loss of memory. For some months she was in bed with a greatly distended abdomen, and scarcely any action of the bowels for two months. Enemata had no effect. She retained, however, small quantities of liquid food. There was no tenderness and no pain. Nothing could be made out by palpation.

After death the whole of the colon was found enormously distended with gas, and the small intestine to a less degree. The stomach was normal. At the origin of the sigmoid flexure as it lay across the left side of the brim of the pelvis was a cicatricial-like contraction on the peritoneal surface, with a dragging in of an appendix epiploica. On opening up the bowel there was found at this site a hard band almost entirely encircling the gut for an inch in width, and causing great contraction of the lumen, so that only a fine probe could be passed through. Round this sinus the mucous membrane was slightly eroded.

Growth presenting a hard scirrhus-like appearance on section was situated beneath the mucous membrane, which it involved, although not ulcerated through, and spread in an invading manner into the deeper tissues of the gut wall; this histologically has the structure of columnar-celled carcinoma. There were no enlarged glands, and no growths elsewhere; the innominate bone

presented no irregularities, and there were no signs to suggest pressure or injury of the bowel from without.

March 1st, 1898.

---

27. *Congenital ventral hernia at the umbilicus.*

By W. G. Spencer.

A male child was first seen when five days old. The mother had been attended by a midwife, who noticed the condition at the umbilicus, and urged that the child should be taken to a hospital, but the parents delayed.

The meconium was passed, but after this only a little mucus stained with fæces. The abdomen began to swell, and vomiting occurred frequently.

On admission the child's abdomen was distended and tympanitic, but not to the extent met with in cases of imperforate anus. A pedunculated egg-shaped swelling protruded at the umbilicus, and on the most prominent part was the shrivelled umbilical cord, almost separated. The tumour was covered with skin, which had become gangrenous nearly to the pedicle. The skin of the pedicle was sound, and no definite impulse on crying could be detected.

The dried cord was picked off, and at its point of insertion a small incision was made through the gangrenous wall. Flatus and fæces escaped, the abdominal distension subsided, and the vomiting ceased. The gangrenous skin and front wall of the bowel gradually separated, leaving a complete artificial anus with a proximal and distal opening, between which was a broad spur. The proximal opening from which the fæces escaped was the lower in position. A little mucous slightly stained with fæces passed *per anum*.

The child lived for fifteen days, wasting somewhat in the meantime.

The specimen shows an artificial anus formed by the sloughing of the front wall of a ventral hernia. The hernia was a protrusion of the lower end of the ileum, the cæcum, and the commencement of the colon, in which the ileum was below and the colon above, accounting for the position of the proximal and distal openings

above mentioned. The spur was formed mainly by the cæcum, the appendix being drawn in so that only its tip was seen protruding from the peritoneal aspect of the spur. The small intestines were dilated, the colon contracted and empty.

Although the hernial tumour was pedunculated, there was no tightly constricting ring. Apparently the hernia was primarily reducible, and no complete strangulation occurred. The sloughing of the front wall seems to have been caused by septic gangrene extending from the umbilical cord.

February 1st, 1898.

---

28. *A case of post-mortem emphysema of the liver.*

By C. Hubert Bond, D.Sc., M.D.

The specimen—a liver—which I venture to show you to-night as one of considerable interest was obtained at an autopsy conducted twenty-two hours after death upon a man, S. W—, who died on October 2nd, 1896, at the London County Asylum, Banstead. He had been an inmate of that institution five and a half months, and was aged 73.

With the exception of characters suggestive of considerable fatty change, the external appearances of this liver did not at first sight appear to call for notice, but on closer scrutiny, here and there beneath the capsule minute cyst-like projections could be detected. very much like those seen so frequently in cirrhotic kidneys. The capsule did not look specially distended. The weight of the organ was 1100 grams, that is, about 400 grams less than normal, and on handling it it imparted a spongy crepitant sensation, much resembling that of a lung, and it was subsequently found to easily float in water.

On cutting into it a very remarkable appearance was manifested. The whole organ was practically throughout riddled with innumerable cavities, quite empty, and varying in size from microscopic ones to others the largest of which measured 6 mm. across. Their walls were ragged, and appeared to have no capsule or definite lining.

Although no division of the liver was free from them, still you will see, from an inspection of the organ, that on the whole these spaces gradually become less and less in size as they approach Glisson's capsule, and that in fact there is more or less a belt of about half to three quarters of an inch of liver tissue at the periphery in which they are few or absent, and when present only of minute size. The intervening tissue was obviously fatty. The gall-bladder contained dark, normal-looking bile which was free from any gas bubbles, and there were no gall-stones.

The heart was the only other organ that appeared to be at all similarly affected; and the indication of this consisted merely in an emphysematous appearance of the epicardium over the left ventricle, with crepitation to the touch; here there was an entire absence of fat, while the right ventricle was fairly well clothed with it. The aortic and pulmonary valves were competent to the water test, but the segments of the former were thickened and in parts calcareous, and between the auricle and ventricle of the left side a firm calcareous ring could be felt. Hypertrophy and commencing dilatation of the left ventricle were observed. The myocardium, while it had generally a dirty hue and looked distinctly in a state of fatty degeneration, was quite free from any trace of cavity formation. The blood in its chambers and everywhere else in the body showed no frothing or special feature, nor did the endocardium show any diffuse imbibition of blood-colouring matter, as has been noted in other recorded cases, in which also the blood has been noticed to be of a lake colour. Unfortunately the heart was replaced before being subjected to further examination. The aorta, from the point at which the left subclavian artery was given off down to its bifurcation, was atheromatous to a marked degree.

The remaining viscera can be dismissed in a few words. The brain, 1450 grams, was pale and wasted; its large vessels were atheromatous, while its central white matter, especially around the basal ganglia, exhibited several small old softenings; but there was no indication whatever of any emphysematous cavities, neither was there in the kidneys or spleen; the former were in a state of red granular contraction. The lungs were œdematous, especially at their bases, but there was no fluid in either pleural cavity; both organs were extensively adherent to the chest wall, and the left pleura was very thick. The pancreas and adrenals looked healthy,

and a careful inspection of the stomach and intestines showed no lesion or abnormality whatever.

The following are the details of further observations on the above liver. Having been freely sliced it was hardened in Müller's fluid, and subsequently small pieces were embedded, some in celloidin, and others in paraffin; sections from these were treated with a variety of stains, and as a result of a microscopical examination of these, it was evident that the organ universally showed fatty changes to a marked degree, limited, however, to the peripheral zone of the lobules. The liver cells themselves stained with a lack of clearness and definition; their nuclei also stained badly, but the normal pigmentary granules seemed greatly in excess, and everywhere very prominent. Glisson's capsule was not thickened, but here and there in the portal spaces there appeared to be a slight increase in the amount of fibrous tissue normally present. Sections stained with methylaniline violet yielded negative results. An examination of the air-cavities showed them to be very irregularly distributed, and, as before suspected from naked-eye observation, to be quite devoid of any lining; in fact, a mere inspection of them suggested that they had been formed by the bursting asunder of the liver parenchyma. The appearance of a lining was sometimes simulated by the liver cells bounding the larger cavities being compressed into layers. No actual necrosis could here be seen, nor was there any small-cell infiltration.

Prof. Kanthack was good enough to supply me with references to several other reported cases of *post-mortem* emphysema, in which the invasion of a gas-forming organism was found to be the cause. He himself describes several specimens and experiments based on these in the addenda to the St. Bartholomew's Hospital Museum, 1895–6. But the fullest account that I have been able to find is by Welch and Flexner in the 'Journal of Experimental Medicine,' vol. i, p. 6, 1896; there a summary of the findings of previous observers is given, with details of numerous fresh cases. A constant micro-organism, which they term the *Bacillus aerogenes capsulatus*, seems to have been found in all, sometimes alone and sometimes mixed with others, such as the *Bacillus coli communis* or various streptococci. They describe it as an anaërobic, non-motile, straight, sometimes slightly curved, sporeless bacillus, 3 to 6 μ in length, with adjacent ends slightly rounded or some-

times square cut; to occur singly, in pairs, clumps, or sometimes in chains, a capsule frequently to be seen but not always, and the organism capable of cultivation upon all ordinary media. They experimented upon animals by injecting these cultures, sometimes before and sometimes after death, with the result that the various organs became riddled with cavities in this typical "Gruyère-cheese" fashion; when introduced after death at one place in the vascular system they developed in the course of the vessels into which they had been introduced, and the time required for gas formation was much larger than when injected before death. In 1893 Fränkel had shown that emphysematous cellulitis was due to this same bacillus; he, however, termed it the *Bacillus phlegmones emphysematosæ*.

Another paper, full of details, by Göbel appeared in 1895 in the 'Centralbl. f. Allgemeine Pathologie u. Pathologische Anatomie,' vol. vi, p. 465; three cases are there described with subsequent experiments, and again an organism was found which he believed to be identical with those of Fränkel and Welch, but probably not the same as that of Ernst. I greatly regret that my acquaintance with these various observations came too late for me to make use of this specimen for their furtherance. However, numerous sections have been stained for micro-organisms, and with Kühne's methylene blue I have easily been able to observe large numbers of bacilli apparently morphologically identical with the one above described. These you will see demonstrated under two of the microscopes, but apology must be made for their somewhat hazy definition; this is due to the rapidity with which the stain seems to filter out of them, and, unfortunately, it was impracticable for me to stain a fresh number of sections to-day. I cannot, however, satisfy myself as to the presence of a capsule. The bacilli are situated, often in large numbers, in densely crowded masses among the compressed liver cells bounding the cavities; these masses gradually get less and less dense as they are traced outwards from the cavities into the less disintegrated parenchyma, until at last the bacilli are seen occurring singly between the rows of comparatively healthy liver cells. It is a question whether they are then to be considered as in the capillary bile-ducts, but at any rate, after carefully examining the portal spaces, I can find none which show bacilli in any of the larger bile-ducts or in the branches of the portal vein or hepatic artery; sometimes a few may be seen

in the loose connective tissue filling up the portal spaces. While considerable areas of liver tissue seem quite free from bacilli, it may frequently be observed that dense plugs of them may be seen in areas which as yet show no tendency to cavity formation, and they are apparently most frequently then situated in the interlobular spaces. An endeavour was made to trace the development of these cavities. From the position of the bacilli one would surmise that probably adjoining lobules were thrust asunder by the formation of gas, and that the disintegration of a lobule would take place from without inwards; but an examination of sections stained with osmic acid—which, owing to the pronounced fatty changes, very clearly and conveniently maps out the several lobules, —gives one unmistakably the impression that it occurs in the reverse direction, namely contrifugally; but here, again, it is right to say that I have nowhere been able to find any plugs or even isolated bacilli in the branches of the central hepatic vein.

The chief interest in this case appears to me to lie in the question of the point of invasion of this gas-forming bacillus, which seemingly is a pure culture and is not intermingled with any other species. Clinically the patient presented practically no points which might help in the solution of this question. He was transferred to Banstead Asylum in April, 1896, from Peckham House, where he had been since December, 1894, and was a very ordinary example of senile dementia. While the brain was extensively diseased, death rather resulted from pulmonary œdema consecutive to the heart lesion. No abrasion of the skin existed, and, bearing in mind Göbel's and other cases, it is worth while specifically stating that he had never been catheterised while at Banstead. The seat of the "Schaumorgane," as the Germans term the condition, strongly points to invasion from the intestinal tract; but, as above said, no lesion could be found along it, even after a most careful search. Previous observers say that it is probable that this bacillus is of much more frequent occurrence than suspected, and one of Welch and Flexner's cases point to its being possibly a not unusual inhabitant of the intestinal canal. If that be so, and granting that in the present case it invaded the blood-vessels of the gut after or immediately prior to death, and developed naturally first in the liver, there yet remains the question, why is this the first instance met with among the last 500 inspections in the mortuary at Banstead Asylum? Many cases exactly similar

mentally and physically to this one occur, and death takes place under the same very ordinary circumstances; it is certainly curious that this is the first occasion the condition has occurred there, at least during the last five years. Even if the bacillus is only very exceptionally present, there is yet room to speculate why it singled out only this patient, when several other deaths in the same ward occurred closely preceding or following this man's decease. Such questions are worth considering and attempting to solve in view of the possible connection this and other allied micro-organisms may have with deaths ascribed to the entrance of air into the circulation, as, for instance, into the uterine veins after abortion, or after uterine injections, or during the puerperal state. In all the other previously recorded cases with which I am acquainted, with the exception of two, there seems to have always been some very obvious lesion as a possible site of invasion for the bacillus. It ought to be mentioned that, in this present case, the weather, while not very cold, had been rather more wintry than summer-like.

I fear my case adds but few new facts to those observed by others; but the comparatively infrequent appearances presented by this liver made me think it of sufficient interest to bring for your inspection. It only remains for me to state that I am indebted to Dr. Claye Shaw for according me permission to show and describe the specimen.

February 15*th*, 1898.

---

29. *Cirrhosis of the liver in a child.* (*Card specimen.*)

By F. Parkes Weber, M.D.

The liver weighs 15 oz., and shows a coarse cirrhosis of "hob-nail" appearance. Large portions of it consist apparently merely of rather soft fibroid tissue. The microscope shows coarse strands of fibroid material with more or less recent inflammatory exudation, the distribution being chiefly of the ordinary multi-lobular type. Scattered areas of the hepatic cells have taken on

the logwood stain badly, and seem to have been necrotic or in process of necrosis. There is a moderate apparent increase in the number of small biliary canaliculi. At the necropsy the common bile-duct and cystic duct were found quite patent. The spleen weighed 10 oz.; microscopical examination of the spleen showed nothing special, and there was no lardaceous change. The kidneys together weighed about 10 oz., and seemed fairly healthy, though some albuminuria had been noted before death.

The liver was removed from a girl aged 6, who was admitted to the German Hospital in an unconscious, irritable condition (resembling that of meningitis), with high fever and jaundice. An empyema was discovered on the right side, but the child died soon after the pus was evacuated. She had been under observation after an attack of stomatitis and diarrhœa some months previously. Cirrhosis hepatis had then been suspected on account of persistent slight jaundice, considerable enlargement and hardness of the spleen, and a rather abnormally small area of hepatic dulness. Some enlargement of the superficial abdominal veins had also been noted. No certain history of congenital syphilis or alcohol could be obtained, though the mother drank gin when suckling the child. (Compare the case in 'Trans. Path. Soc.,' vol. xlvi, p. 71.)

I would draw attention to the enlargement of the spleen in this case, a sign which I believe to be of the greatest importance in the clinical diagnosis of cirrhosis of the liver in children. The kidneys also were relatively enlarged, and I suspect that if statistics were to be collected, it would be found that in cases of grave hepatic affections of long duration the kidneys, if themselves not specially diseased, are always enlarged; and *vice versâ*, in cases of chronic renal disease some enlargement of the liver would, I suspect, always be found, when this organ itself is not specially diseased. A certain degree of mutual compensatory action between the liver and the kidneys probably exists, and the relative enlargement of the kidneys in the present case can be explained on this supposition as a partly compensatory hypertrophy.

April 5th, 1898.

30. *Liver showing an early interlobular type of cirrhosis, from a case of suppurative pylephlebitis.*

By F. Parkes Weber, M.D.

The liver in this case (weight about 46 oz.) shows no macroscopic evidence of cirrhosis. The large branches of the portal vein were found at the necropsy to be full of pus, and they constituted, in fact, a branched abscess cavity, which communicated with a thrombus at the junction of the splenic and portal veins, and with an abscess cavity behind the pancreas. No separate abscesses were found in the liver.

Microscopically sections of the liver show a considerable increase of the fibrous tissue in the angular spaces between the hepatic lobules, apparently the result of a chronic inflammatory process. This fibrous change is almost completely limited to the interlobular spaces, and constitutes a unilobular (or monolobular) form of cirrhosis, as typical in its arrangement as that named biliary cirrhosis by Charcot and Gombault in their original papers of 1876. In the present specimen there is also, as in Charcot's cases, a decided increase in the apparent number of bile capillaries.

The *post-mortem* examination had to be limited to the abdomen. The gall-bladder and large biliary passages were normal. No gall-stones were found. The spleen was moderately enlarged. The kidneys macroscopically and microscopically appeared practically normal. There were numerous petechiæ in the mucous membrane of the stomach. No focus of suppuration, other than that mentioned, was found.

In regard to the history of the case there is little to be said. The patient was an unmarried woman aged 21, admitted to the hospital with intense jaundice, and in an extremely exhausted condition. The liver and spleen were both felt enlarged, and there was also some abdominal dulness, probably due to slight peritoneal exudation. The past history was very imperfect. She had apparently been ill six or seven weeks, but according to the account given us she had only become jaundiced recently. In

spite of the absence of fever at this time, some suppurative process, such as suppurative cholangitis, or pylephlebitis, or a subdiaphragmatic abscess was thought of. The extreme tenderness and some swelling over the liver suggested the possibility of a subdiaphragmatic abscess, and an exploratory laparotomy was decided on. It was performed by Mr. Parker, who found a swelling behind the liver, to get at which an opening was made in the lesser omentum above the stomach. As no pus could be detected in the swelling by the exploring syringe, the wound was closed up again. The patient died soon afterwards from exhaustion.

Pathological questions arising in connection with this case are the following. What was the cause of the sharply defined interlobular type of commencing hepatic cirrhosis? Is the case an example of biliary cirrhosis, due to obstruction to the bile-flow by pressure at the hilum of the liver, similar to the cases described by Charcot and Gombault? I think that it is impossible to answer these questions with certainty. Certain it is only that at the necropsy an abscess was found pressing on the hilum of the liver. This abscess during life doubtless obstructed the flow of bile, and gave rise to the intense jaundice, which existed at all events during the last period of the illness. From experiments in animals, moreover, it is said that two or three days' obstruction (by ligature of the duct) to the bile-flow may be sufficient to bring about commencing microscopic changes in the liver, of a type analogous to those found in the present case, namely, apparent increase in the number of bile capillaries and increase in the amount of interlobular connective tissue.[1]

The fibrosis is almost completely limited to the interlobular spaces, in which the small portal vessels and bile-ducts run. In fact, so decided is the type of distribution of the abnormal tissue that the present case reminds one of the appearances seen in certain cases of so-called "cystic disease" of the liver, such as the case shown by Dr. G. F. Still at the Pathological Society on December 21st, 1897. In both instances the fibrosis of the liver is hardly macroscopic, and in both cases the fibrous tissue is practically only interlobular in distribution; but whereas in the present case the abnormality is probably due to a tolerably recent in-

[1] See D. Nasse, "Ueber Experimente an der Leber und den Gellenwegen," in 'Arch. für klin. Chirurgie,' vol. xlviii.

flammatory process, in "cystic disease" it is more probably, as Dr. Still has pointed out, of congenital origin.

The cause of the suppuration behind the liver and in the portal veins must remain uncertain.

April 19th, 1898.

---

31. *Pendulous hydatid cyst of liver.*

By THOMAS CARWARDINE, M.S.

THE patient was a married woman aged 48, admitted to the Bristol Royal Infirmary on December 10th, 1897, with an abdominal tumour as large as a child's head, having its greatest prominence above and to the right of the umbilicus. It moved slightly with respiration, was subglobular in form, and had a well-defined outline with a marked notch near the umbilicus. When the patient was on her right side the tumour passed into the right loin, and could be felt there bimanually. When she turned to the left the tumour passed obliquely downwards towards the left lumbar region, and well-defined bands of adhesion could be felt passing from the tumour to the right iliac fossa.

There was dulness over the liver, impaired resonance over the tumour, and more resonance between the two. Between liver and tumour there were two tympanitic angles (see Fig. 5). The uterus was depressed and deflected to the left.

The patient first noticed a painless swelling four years ago. A few months afterwards she had an attack of very severe pain in the right lower abdomen, the tumour became larger and harder, and she was in bed three weeks. After several slight attacks she had another severe one two months ago, with rigors and a "hectic" temperature; the cold shivers and perspirations lasting half an hour at a time, and the temperature ranging from 100° to 103°.

The urine was at times copious and pale, especially when lying on the back. She never vomited until the last attack, when she was taking olive oil.

Two years ago she says she had a lump in the left side also, which gradually went away.

On admission her temperature and pulse were normal, and

FIG. 6.

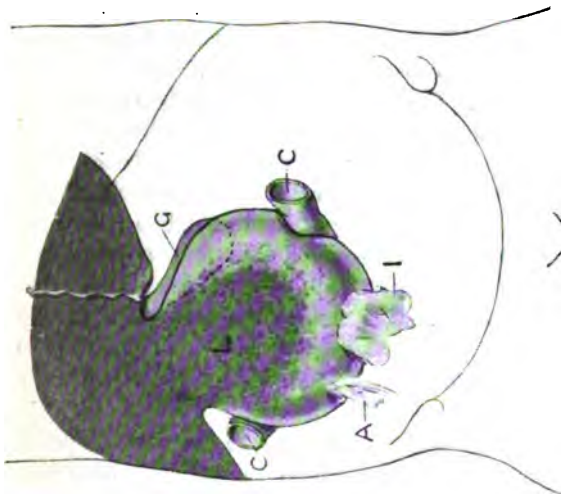

Hydatid of liver. Pathological aspects.
L. Linguiform process of expanded liver.
G. Gall-bladder.
C. Colon (explaining the presence of a notch).
I. Ileum.
A. Some adhesions.

FIG. 5.

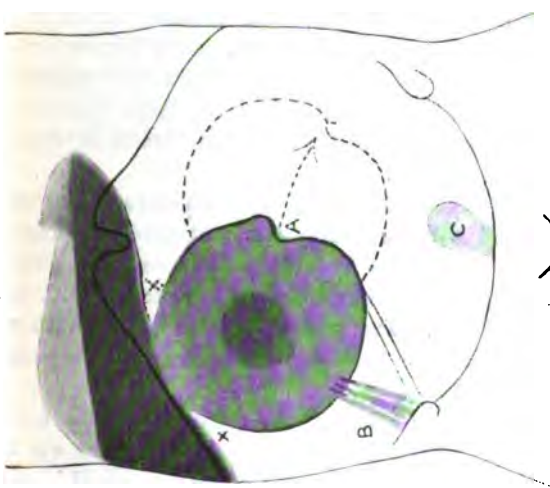

Hydatid of liver. Clinical aspects showing outline, dulness, &c.
X Angles of tympanitic resonance.
A. Well-defined notch.
B. Adhesions which could be felt.
C. Deflected uterus.

respirations rather increased; she passed some 30 ounces of non-albuminous urine daily, containing 2 to 3 per cent. of urea.

On December 16th, the diagnosis being uncertain, I performed median cœliotomy. The uterus and appendages and the right kidney were quite normal. The tumour was felt to be cystic, with its upper surface continuous with the dorsum of the liver, but on either side the edges of the liver were distinct. There were numerous adhesions, and the gall-bladder could not be felt.

An opening was now made in the right semilunar line, where the large cystic tumour could be seen covered with liver tissue. The parietal peritoneum was inverted, no sutures were used, but excellent union was obtained. The history of rigors, the difficulty of shutting off the general peritoneal cavity with sponges owing to the numerous adhesions, and the fact of the anæsthetic being badly borne, rendered a two-stage operation the safer.

Six days afterwards (December 22nd) the liver was opened without an anæsthetic, and, as one expected, the patient stated that the incision of the liver tissue an eighth of an inch thick gave no pain. Thirty-four ounces of a stringy, viscid, deeply bile-stained fluid came away,—not in the least like ordinary hydatid fluid. Two drainage-tubes were inserted, and the cavity was freely irrigated. The fluid was found by Dr. Edgeworth to give spectroscopic reactions characteristic of bile pigment, and by Dr. Symes to be sterile. Analysis gave the following results:—Alkaline; sp. gr. 1015; albumen in considerable amount, nearly 50 per cent. by volume (picric acid test); urea 0·6 per cent.; bile pigment present; bile acids absent; chlorides present in large quantity; mucin not detected; centrifugalised fluid yielded tyrosin crystals, but no hooklets on this occasion.

Three days after opening the cyst the temperature became slightly subnormal, and with one exception continued so. Nine days afterwards small pieces of hydatid membrane came away for the first time. A few days later hooklets were found both in the fluid and on membrane. The patient at this time (January 3rd) showed signs of restlessness and depression, and was sleepless at night.

Fifteen days after opening the cyst the mother-cyst wall came away freely with several attached daughter-cysts, and there was a temporary rise of temperature. Two days later albumen and blood appeared in the urine, with a considerable deposit of epithelium

having the characters of that lining the renal pelvis. The urine, which had been somewhat scanty, diminished still more, she only passed 21 ounces in forty-eight hours, and œdema of the skin presented itself.

During the next two days the signs of uræmia increased, whilst the condition of the wound remained perfectly satisfactory, and she died comatose on January 10th, 1898, a month after admission.

Post mortem the following were observed:—The peritoneum was perfectly healthy everywhere, and the operation area in good condition. The lungs, pleuræ, and viscera generally were healthy. The gall-bladder contained pus. This probably explains the rigors before admission, and perhaps also the temporary presence of a left-sided tumour two years previously. There was no cystitis, but the pelvis of the right kidney contained some thin purulent fluid, and its mucous membrane showed congestion with petechial spots. The signs of inflammation ceased a few inches down the ureter. There were no abscesses in the kidney substance.

The points of pathological interest in this case are—

1. The presence of pus in the gall-bladder, explaining the rigors in her last attack.
2. The pendulous nature and peculiar site of the cyst, leading to impossibility of certain diagnosis.
3. The linguiform expansion of liver covering the front of the cyst (see Fig. 6).
4. The exceptional character of the contents—bile-stained and highly albuminous.
5. The firm, solid union of liver to parietes without using sutures.
6. The painless incision of the liver without an anæsthetic.

March 2nd, 1898.

---

32. *Large intra-hepatic calculi in diabetes.*

By H. D. Rolleston, M.D.

The hepatic ducts just inside the liver contained a large mass of crumbling blackish material which dilated them to the size of a sixpence.

The common hepatic duct contained a loose black calculus; the

gall-bladder, cystic and common bile-ducts did not contain any calculi, and were not dilated. The crumbling mass, which it is perhaps rather a stretch of the legitimate use of the term to call a calculus, contained bilirubin-calcium and traces of cholesterin.

The patient was a man aged 38, who died with rapid pulmonary tuberculosis supervening on pancreatic diabetes. He was jaundiced. The liver weighed 59 oz., and was affected by early lardaceous disease; there was a mixed and multilobular cirrhosis, with some old thickening around the bile-ducts, which were dilated in parts. In some areas intercellular fibrosis was present. There was a cyst containing bile on the surface of the liver, surrounded by some perihepatic adhesions. There was no pigmentation of the cirrhotic liver such as has been met with in "bronzed diabetes."

He had syphilis twenty years ago, and had been addicted to alcoholic excess. It appeared possible that both the chronic pancreatitis (*vide* p. 150) which accompanied and gave rise to the diabetes, and the intra-hepatic calculi were due to the extension of duodenal catarrh set up by alcoholic excess.

The pancreatic duct was dilated, and contained small concretions of calcium carbonate.

The kidneys showed arterio-sclerosis and subsequent atrophy with early lardaceous change.

Remarks.—Large intra-hepatic calculi are rare. Murchison ('Diseases of Liver,' second edition, p. 545) refers to a plate of Cruveilhier's (livraison xii, pl. v) showing large branched intra-hepatic calculi like coral.

Small ones are by no means rare. Large ones in the hepatic duct are usually derived from the gall-bladder, but the absence of any dilatation of the cystic duct renders this highly improbable in this instance. Intra-hepatic calculi rarely give rise to definite symptoms; in this case, however, there was well-marked jaundice.

This case is remarkable not only for the large size of the intra-hepatic calculi, but also for the fact that they occurred in a case of diabetes.

It might have been surmised that owing to profuse diuresis the bile would be concentrated, and that this would dispose to cholangitis, the ducts not being so perfectly flushed, and ascending infection from the intestine thus being rendered easier, and so to cholelithiasis. Hunter[1] quotes Bouchard to the effect that diabetes

[1] Hunter, 'British Medical Journal,' 1897, vol. ii.

was present in sixteen out of 165 cases of cholelithiasis; and Naunyn[1] refers to Ord, Loeb, and Gans' view that biliary colic may give rise to diabetes, but does not find that his own experience bears this out.

It has, however, been thought that gall-stones are very rare in diabetes. Brockbank[2] quotes 220 cases of diabetes mellitus recorded by Windle, with only one calculus, or ·45 per cent., and is inclined to explain this by the nitrogenous diet in diabetes providing plenty of bile acids which keep the cholesterin in solution. In eighteen other cases of diabetes examined within recent years at St. George's Hospital there was one with calculi.

Another point of interest is the presence of cirrhosis of the liver. It may have been antecedent to the production of the masses of bile pigment in the hepatic ducts, and have been due to alcoholic excess. It might, on the other hand, conceivably have been due to the presence of the calculi. There was no definite appearance of biliary cirrhosis except some old-standing fibrosis around the smaller bile-ducts and some dilatation of the ducts. But that calculous obstruction may give rise to cirrhosis of the ordinary alcoholic multilobular type appears probable from a case described by Dr. Parkes Weber.[3] Perhaps the cirrhotic changes in this case were partly antecedent to the formation of the soft calculus, and partly due to it.

The existence of chronic inflammatory changes and the formation of calculi in both the liver and pancreas are also noteworthy.

January 4th, 1898.

---

33. *Spontaneous fracture of a gall-stone in the gall-bladder.*

By H. D. Rolleston, M.D.

The patient was a woman aged 46, who died with spheroidal-celled carcinoma of the gall-bladder. There were numerous growths in the peritoneum and in the liver, which weighed 11 lbs.

[1] Naunyn, 'Treatise on Cholelithiasis,' translated for the New Sydenham Society by A. E. Garrod, p. 169.

[2] Brockbank, 'Cholelithiasis.'

[3] F. P. Weber, 'Brit. Med. Journ.,' 1896, vol. i, p. 1027.

3 oz. There was intense jaundice due to compression of both the common and the hepatic bile-ducts.

The gall-bladder formed a large tumour; this was partly due to the growth and partly to its being distended with clear unstained mucus, in which there were a large number of minute pearl-like calculi, chiefly composed of cholesterin. In addition there were three large calculi: the largest was roughly cylindrical, in size and shape resembling the amputated terminal phalanx of the thumb, and covered laterally by a whitish layer, probably cholesterin; while at its ends, which gave the impression of having been fractured, a laminated section could be seen. Of the two other larger calculi, the smaller had a similar somewhat sharply cut surface, which might have fitted into one of the ends of the cylindrical calculus. It did not accurately fit, however, and this suggested that the fracture of the original gall-stone had occurred some considerable time before death, and that in the interval the calculi had become worn down by attrition. The other larger calculus was like a pebble, and did not show any surface which could be regarded as corresponding to the broken ends of the parent calculus.

Remarks.—In connection with the spontaneous fracture of biliary calculi it is interesting to refer to the same occurrence in urinary calculi.

Dr. W. M. Ord has written a series of papers on the spontaneous fracture of calculi in the urinary bladder; in some cases[1] it was thought to be due to expansion of the nucleus of the calculus, which bursts open the calculus in the same way that the charge explodes a shell. In another case it seemed that a mycelial growth passed into the calculus through small cracks in the outer crust, and split off the external laminæ.[2]

Dr. C. B. Plowright[3] has described the process of spontaneous fracture of uric acid calculi encysted in sacculi of the bladder. The disintegration was brought about by pressure from without, by a process of wedging out of the segments of the uric acid calculus. The active agent was acid urate of ammonium, which by settling in small cracks radiating from the nucleus gradually opened them out by increased deposition. By a similar deposit between the zonal layers of the calculus the superficial layers were

[1] Ord, W. M., 'Trans. Path. Soc.,' vol. xxviii, p. 170.

[2] Ibid., vol. xxxii, p. 304.

[3] Plowright, 'Trans. Path. Soc.,' vol. xlvii, p. 132.

levered off. Dr. Plowright lays stress on the presence of purulent urine as an important factor in this process.

Other cases of spontaneous fracture of vesical calculi have been recorded by Dr. W. W. Smith and Mr. Hurry Fenwick,[1] who explained the disruption as being due to swelling not of the nucleus of the calculus but of a layer lying around it (perinuclear layer) which contained more phosphates than the other layers, and which the authors considered might expand and therefore burst off the outer layers; and by Mr. Buckston Browne,[2] in whose case the fragments reunited. In the same volume as the last two cases Mr. Bruce Clarke described spontaneous fracture of a renal calculus. With regard to the possible causes of spontaneous fracture of gall-stones, the following may be mentioned.

(1) Traumatism either during life or after death. In making the autopsies the routine practice of pressing on the gall-bladder in order to see whether bile will run into the duodenum is sufficient to fracture brittle or friable calculi, especially those containing much bilirubin-calcium. This fallacy is apparent to every one, and hardly requires to be mentioned.

(2) Vigorous contraction of the gall-bladder might fracture a friable calculus. The spasmodic contractions might be due either to irritation of contained calculi, to impaction of a calculus in the ducts, or possibly to a new growth invading the gall-bladder.

(3) The penetration through small channels in the outer coat or crust of the calculus of salts, colloid matter, or bacteria derived from the mucus or bile in the gall-bladder, which under certain conditions may, as described by Dr. Ord in the case of vesical calculi, give rise rise to cleavage.

Naunyn[3] points out that under ordinary conditions cholesterin passes into the interior of gall-stones in the gall-bladder, and that bilirubin-calcium may pass out. Micro-organisms have been found in the interior of calculi; and Chauffard,[4] while contending against the view that the formation of gall-stones necessarily depends on microbic activity, has shown that micro-organisms can readily penetrate calculi from without.

[1] W. W. Smith and E. H. Fenwick, 'Trans. Path. Soc.,' vol. xli, p. 183.

[2] Buckston Browne, 'Trans. Path. Soc.,' vol. xli, p. 186.

[3] Naunyn, 'A Treatise on Cholelithiasis,' translated for the New Sydenham Society, 1896, p. 32.

[4] Chauffard, 'Revue de Médecine,' Feb., 1897.

In the present instance traumatism during life could be excluded fairly well, and since from the worn appearance of the calculi the fracture had taken place some considerable time before death, the question of the disruption having occurred while laying out the body, lifting it out of the coffin, or during the *post-mortem* examination did not arise.

The possibility of a large and not very coherent calculus having been broken by vigorous contractions of the gall-bladder, set up either by the irritation of the calculi or by the complete obstruction resulting from the new growth, or even from the direct stimulus of the carcinoma of the gall-bladder, receives no support from the history of the case. During life the patient was several times questioned with special reference to the occurrence of past attacks of biliary colic, but she had no recollection of anything of the kind.

It appears probable that the spontaneous fracture was due to some invasion of the calculus, resembling that described by Dr. Ord in the case of vesical calculi; but the difficulty is to say why an invasion which is probably extremely frequent in the case of biliary calculi should in exceptional cases induce spontaneous fracture. It is of course possible that spontaneous disintegration is by no means rare in the gall-bladder, and that attention has not been sufficiently directed to this point.

I have not made sections of the calculi, as it appeared better to present them intact to the Society. One fractured end of the larger calculus showed lamination with brown and white layers. The mechanism of cleavage can only be guessed at, but the preceding explanation, or one on much the same lines, seems the most reasonable.

In connection with the fact that this case was one of carcinoma of the gall-bladder, the possibility of the growth playing an active part in the fracture might be considered, but only in a most tentative spirit. When malignant disease invades bone it freely decalcifies it. The calculus was not adherent to the growth, but it is just conceivable that some fluid or internal secretion emanating from the growth might have exerted some dissolving influence on the calculus. Against this it can be argued that the process is not one of solution, as shown by the large number of small calculi, so much as of disruption of a large calculus.

The late Dr. W. B. Hadden[1] described spontaneous fracture of a calculus in the gall-bladder into seven fragments, which could be fitted together fairly well. There was no traumatic or other sufficient cause forthcoming. The patient was a woman aged sixty-six years, who died with carcinoma of the breast; there were no growths in the gall-bladder or liver.

November 16th, 1897.

---

34. *Spontaneous fracture of gall-stones.*

By James Calvert, M.D.

On July 10th, 1896, a seaman aged 67 was admitted into St. Bartholomew's Hospital, under the care of Dr. Church. He died on March 1st, 1897.

Neither in his past history nor during his prolonged stay in the hospital was there anything to suggest gall-stones. The jaundice which came on slowly three weeks before death was not accompanied by any particular pain; it was held to be due to obstruction of the common bile-duct by new growth, a view which the *post-mortem* verified.

Post-mortem examination (thirty hours after death).—Carcinoma of the prostate, secondary growths in the abdominal glands and in the liver, chronic interstitial nephritis.

The *gall-bladder* was not enlarged; its walls were thickened, but not by new growth; on section it was found to be completely filled with gall-stones. A stone about the size of a pea plugged the cystic duct, so that the gall-bladder contained practically no bile, nor was there any mucus. The cystic duct beyond the stone and the common duct near its commencement were narrowed by new growth pressing from without.

The *gall-stones*, with two or three exceptions, were broken up into innumerable fragments. They were of the common kind, a

[1] Hadden, 'Trans. Path. Soc.,' vol. xli, p. 160.

yellow external crust of cholesterin and pigmented internally (greenish). The external crust was rather hard, the interior was drier than usual and somewhat cavernous. Each fragment was faceted on its outer surface, and evidently had been part of one stone among many others; and some of the fractured edges were sharp and rough and recent, but others were rounded and smooth and older; and two or three of the stones were not yet in pieces, though the process had begun, the external crusts being cracked along the edges of the facets.

Remarks.—It is conceivable that a blow or a heavy fall may fracture a gall-bladder calculus, but such an explanation cannot apply to this case, because the process of fracture was gradual and affected different stones at different times. It is conceivable also that the *Bacterium coli commune* or some other mysterious influence may be a cause, but in this particular case I think the explanation of fracture may be simple enough: on the one hand we have a gall-bladder with thickened walls contracting firmly down upon its contents; and on the other hand we have a gall-bladder into which no bile can enter, and in which there is now no bile, so that the enclosed stones have become much drier than usual, and therefore more liable to break up, just as they often do break up without any external pressure when they become dry outside the body.

Although I can find only one case recorded in the 'Pathological Society's Transactions" (by Dr. Hadden, 1889), still I suspect that spontaneous fracture is commoner than we think, and I hope that by drawing attention to the subject we will soon get together sufficient evidence to determine its cause or causes.

November 16*th*, 1897.

---

35. *Congenital round-celled sarcoma of the liver.*

By George Heaton.

A uniformly enlarged liver from the body of a child aged eight weeks.

The patient, a girl aged 8 weeks, was admitted into the Chil-

dren's Hospital, Birmingham, in December last with a history of rapid abdominal enlargement with general wasting.

The abdomen was noticed at birth to be unduly prominent, and this prominence increased rapidly up till admission a few days before death. There was a history of repeated attacks of convulsions coming on when the child was a fortnight old. During a week while the child was under observation the abdomen increased in circumference one and a half inches. It was distended by a tumour occupying the epigastric, the right and left hypochondriac regions, descending downwards below the umbilicus. The tumour had the characteristic signs of an enlarged liver.

There was no jaundice and no ascites.

The mother and father were in every way healthy. There are two other children alive and well. There was no evidence whatever of any syphilitic taint. A long, fine aspirating syringe drew off a little blood.

The child rapidly sank, and died on December 21st, 1897.

A *post-mortem* examination was made twenty-four hours after death. There was much general wasting of the body. The abdomen was distended by a uniform swelling occupying the position of the liver, and extending considerably below the level of the umbilicus.

On opening the abdomen there was no excess of fluid in the peritoneal cavity. The spleen was of average size, and showed no lesion. The kidneys were anæmic. There was no enlargement of any of the abdominal lymphatic glands, nor any evidence of old or recent peritonitis.

The right supra-renal capsule was enlarged by a nodule about the size of a child's marble occupying its posterior half. On section it was dark red. The left supra-renal capsule showed no abnormality.

The liver, which I show you here to-night, was greatly enlarged, and weighed forty-nine ounces. The enlargement is uniform, all its lobes being equally affected. The surface is smooth and glistening, the peritoneal coat being normal in appearance, and there is no thickening of the capsule. In the fresh state the surface of the organ had a most peculiar mottled or marbled appearance, being covered with numerous red patches separated from one another by pale dull areas. A fresh section of the liver presented exactly the same appearance, and it does to a less degree

now. There were numerous patches of a dark red colour surrounded by zones of a lighter colour.

The gall-bladder is contracted and empty. The sulcus in which it lies does not nearly reach the free margin of the organ, indicating a rapid enlargement of the organ in a downward direction.

Dr. Douglas Stanley has made a careful microscopic examination of the enlarged liver for me. It shows—

(1) Areas in which there is considerable vascular engorgement corresponding to the dark red patches seen with the naked eye.

(2) Liver cells showing apparently no change.

(3) Areas of small-cell growth, corresponding to the pale patches seen by the naked eye. These areas contain large numbers of round cells fairly uniform in size, and rather densely packed together.

At the margins of these areas the cells may be seen infiltrating between the liver cells, even extending some distance away from the main collection. Where this infiltration is taking place the liver cells show a considerable amount of alteration, being atrophied, and in many instances so changed that their distinctive characters are lost, and they appear as irregular atrophied cells.

The organ would therefore appear to be the seat of a diffuse round-celled sarcoma which has begun primarily within its substance during intra-uterine life, and caused a rapid uniform enlargement with partial disappearance and destruction of the liver cells.

An examination of numerous sections leads to the view that the sarcomatous infiltration is taking place along the connective-tissue septa containing the blood-vessels.

The diagnosis of sarcoma is supported by the great and rapid enlargement of the organ, the absence of any enlargement of the spleen or lymphatic glands, and the presence of a secondary nodule of an exactly similar character in the right supra-renal body.

Primary sarcoma of the liver is a rare form of tumour at any age. I have been unable to find any record of such a growth commencing, as this apparently did, during intra-uterine life.

The case most closely resembling it which I have been able to find is one shown by Dr. Howard Tooth[1] before this Society in November, 1884.

[1] 'Trans. Path. Soc.,' vol. xxxvi, p. 236.

The liver was removed in his case from a girl aged five years, in whom it had caused symptoms for six months. The organ weighed 48 oz., and was diagnosed as a primary lympho-sarcoma.

March 1st, 1898.

---

36. *Sarcoma of the liver and supra-renal in a baby.*

By G. Newton Pitt, M.D.

The specimen was taken from a boy ten months old, who was admitted under my care on September 1st, 1897, with an abdominal tumour. For six weeks there had been wasting, vomiting, and diarrhœa. The mass was supposed to consist of matted tuberculous material among the abdominal glands and intestines. The tumour steadily increased in size, the child became jaundiced and drowsy on September 21st, when it was for the first time thought that the tumour was in the liver, and of a malignant nature. The child died on the 11th of October.

At the inspection there was found two pints of bile-stained fluid in the abdomen. There was one large mass of growth in the greatly enlarged right lobe of the liver, with numerous secondary nodules scattered about. The mass had been found during life to be somewhat moveable, and this was found to be due to the thin central portion of the liver, which allowed the lower mass with the growth to be bent backwards and forwards.

The right supra-renal was occupied by a mass of growth the size of a hen's egg, and there were growths in the adjacent glands, whence the growth had extended into the pancreas at its head.

From the contraction which had taken place in the growth in the liver and the large size of one of the masses, Dr. Perry thought it probable that the growth had started in the liver. Histologically the growth was a very vascular small round celled sarcoma.

February 1st, 1898.

---

37. *Primary carcinoma of the liver associated with gall-stone.* (*Card specimen.*)

By Cecil F. Beadles.

Female, 9865, aged 62, an inmate of Colney Hatch Asylum with mania of ten years' duration, wild, talkative, confused in her ideas, abusive, and threatening, gradually getting worse as years passed by. During the last year or two she had a constant delusion that there were sticks inside her body "to keep the devils out." Throughout she was in fair bodily health, and seemed so to within the day of her death, when she suddenly had a seizure which was believed to be of uræmic origin. She was put to bed and died within a few hours. At no time were there any symptoms pointing to liver disease.

Post mortem the kidneys were found reduced in size, and were in a disintegrated condition. The heart was small. All serous cavities contained excess of fluid.

The liver was found to be the seat of primary malignant disease, there being no other cancerous disease in the body and no enlargement of the abdominal or other lymphatic glands. The organ weighed 54½ ounces, and was somewhat increased in size, measuring seven inches antero-posteriorly and eight inches transversely. The anterior two inches of the right lobe was flattened and constricted, hard and nodular on the surface, and on section presented a uniformly hard, pale, scirrhus-like structure of primary carcinoma spreading backwards into the liver substance. The hinder part of the left lobe was flattened out, and extended some distance back. The rest of the organ was pale, and studded on the surface and internally with round secondary deposits. The portal vein, as it entered the liver substance, was entirely occluded by a pale, laminated clot, which projected as a round, finger-like mass with a free extremity backwards along the vein for nearly two inches. The larger branches of this vein within the organ were filled partly by black and partly by colourless clot.

The gall-bladder was enlarged, and contained bile somewhat altered in appearance, and over the orifice of the cystic duct was a small round calculus of cholesterin, half an inch in diameter and

weighing eleven grains, which was held in position by a little fold of mucous membrane so as to act as a valve over the orifice of the duct. The cystic duct and larger hepatic ducts were pervious.

The minute structure of the scirrhus-like growth at the anterior edge of the liver resembles, too, very closely a hard scirrhus of the breast. The whole is pervaded by a coarse fibro-granular stroma, studded all over by minute groups of cancer cells. There are no large alveolar masses, but numerous small groups of half a dozen or less spheroidal-shaped cells. Hepatic tissue at this part is entirely absent. The secondary deposits that lie scattered about the organ differ from the above, as is usual, in the fact that there is more distinct alveolar arrangement of somewhat larger groups of epithelial cells; many of the latter are also of considerable size, and a number of these appear to contain intra-cellular bodies.

During the time that has elapsed since I brought the subject of "the relation of biliary calculi to malignant disease of the liver and gall-bladder" before this Society (vol. xlvii, p. 69), about 400 livers have been examined in the *post-mortem* room. The above is the only instance of primary carcinoma of the liver that has occurred, and there have been but three instances in which the organ was the seat of secondary growths. The primary neoplasms in the latter cases were carcinoma of the kidney and malignant disease of the mediastinum in the male, and scirrhus of the left breast in the female. In neither of these were gall-stones present.

December 7th, 1897.

---

38. *Localised effusion in the lesser sac of the peritoneum due to pancreatitis, imitating a pancreatic cyst; fat necrosis. (Card specimen.)*

By H. D. Rolleston, M.D.

Clinical History.—The patient was a man of weak intellect, aged 25 years, who had been the subject of right-sided infantile paralysis since the age of one year.

Until two weeks before his death he had been in good health he was then seized with vomiting, which persisted for the rest of his life. There was pain, never very acute, in the lower part of the abdomen, which came on before vomiting and was sometimes relieved thereby. He had always suffered from constipation, and this had been more marked since the onset of this illness. There had been no jaundice, hæmatemesis, or melæna. He had wasted considerably since the vomiting began. No history of a blow on the abdomen was obtained. He was admitted to St. George's Hospital under the care of Dr. Ewart, to whose kindness I am indebted for permission to bring the case forward, three days before his death.

An indistinct tumour was felt below the left hypochondrium, with the stomach resonance above it, the heart's apex being in the fourth interspace.

The diagnosis lay between carcinoma of the stomach and pancreatic cyst.

At the autopsy there was no general peritonitis, but the lesser sac of the peritoneum ("omental bursa" of American authors) was found distended with grumous fluid, yellowish brown in colour and turbid.

The foramen of Winslow was obliterated, so that there was a localised peritoneal effusion; the stomach was pushed forwards and flattened on the front of the distended lesser sac. The transverse colon formed the lower limit of the cyst, which bulged the transverse mesocolon downwards, but the effusion did not pass between the layers of the great omentum depending from the transverse colon. The peritoneal walls of the lesser sac were thickened from inflammation, and showed scattered areas of fat necrosis. Microscopic examination confirmed these naked-eye appearances. This inflammatory effusion was limited to the left by the spleen and above by the left leaflet of the diaphragm, which was so nearly eroded at one spot that it gave way during the *post-mortem* examination. The eroded area of the diaphragm was the size of a florin, and projected into the pleural cavity like a blind funnel; at this point the base of the left lung was adherent to the diaphragm by recent lymph.

The localised effusion had also nearly perforated the under surface of the transverse mesocolon on the left side, and on slight preliminary manipulation of the abdominal viscera it gave way, and discharged its contents into the peritoneal cavity.

I am greatly indebted to my colleague, Dr. Buckmaster, lecturer on physiology at St. George's Hospital, for the following analysis of the fluid contained in the lesser sac of the peritoneum.

"About 8 c.c. of the liquid was available for examination. The fluid was opaque, of a dark brown colour, with a distinct putrefactive odour. Reaction alkaline, and equivalent to a solution containing ·06 per cent. NaHO. Under the microscope nothing could be recognised beyond amorphous matter and micro-organisms.

"The liquid contained a small amount of proteid which appeared to be serum-albumen; no evidence of albumen or peptone could be obtained. Absence of any reducing body or sugar. Chlorides and phosphates were present, and reactions confirmatory of the presence of tyrosin and indol were easily obtained.

"On allowing the liquid to stand for twenty-four hours it separated into two layers, an upper semi-turbid light brown liquid and a thick dark-coloured deposit. This latter showed abundance of tyrosin crystals and a few large transparent crystals, somewhat resenbling those of triple phosphate. The exact nature of these could not be ascertained. Evaporation of the deposit showed abundant crystals of sodium chloride.

"No evidence was obtained of the presence of urea or cholesterin.

"The fluid yielded no absorption bands in the spectrum, and by no tests could evidence of the colouring matter of the bile or blood be obtained.

"Two ferments were easy to recognise. The fluid had strong diastatic power, converting starch solution into maltose even more quickly than saliva. There was no proteolytic ferment. A perfectly neutral fat was prepared by Kuckenberg's method of treating olive oil with baryta water, heating and subsequently obtaining a solution of the neutral fat in ether. This process was repeated several times until the reaction was neutral, and no emulsion formed on shaking with weak NaHO. It was easy to show that a fat-splitting ferment of considerable activity was present. Acidity developed in almost six hours, and continued to increase for forty-eight hours. Control tubes with neutral fat alone, neutral fat and alkali, and a tube of the original liquid showed no acid reaction at the end of two days."

There were scattered foci of fat necrosis on the lesser and greater omenta, and in the retro-peritoneal tissue around the kidneys,—in fact, in the entire neighbourhood of the effusion. In addition there

was a localised area of fat necrosis on the subperitoneal fat just above the pubes on the left side, where the great omentum was adherent.

The stomach was adherent to the diaphragm, but was normal internally, as was the duodenum.

The gall-bladder contained fifty-nine small calculi composed of a pigmented nucleus surrounded by cholesterin; the cystic duct was long, joining the common hepatic duct three quarters of an inch above the papilla; it contained a single calculus like those in the gall-bladder; its walls were covered by mucus, and were therefore probably inflamed. It was possible that the inflammation had spread from the cystic duct to the pancreas.

The right lobe of the liver contained a triangular hæmorrhagic area like an infarct. There was no thrombosis of the portal vein or its branches.

The cavity of the lesser sac of the peritoneum was emptied, and then stuffed and hardened. A transverse section made later showed that its cavity was as large as a man's head. As already stated, this cavity did not pass into the great omentum below the level of the transverse colon. The interior of the cavity was lined by ragged-looking peritoneum with adherent lymph and areas of fat necrosis. The pancreas lay at the back of the sac. Careful examination did not reveal any rupture of any of the lobules of the pancreas through the peritoneum covering it; this process has been described as occurring in acute pancreatitis by Körte.[1]

Microscopic examination of the pancreas showed acute interstitial inflammation of the organ; there were a few microscopic but no manifest naked-eye hæmorrhages. This inflammation of the pancreas would probably allow some soaking through of the pancreatic secretion into the lesser sac of the peritoneum.

Remarks.—This case was one of acute pancreatitis, which began two weeks before death and gave rise to a localised peritonitis with effusion occupying the lesser sac of the peritoneum. It is noteworthy that this peripancreatic cyst resembled closely a true pancreatic cyst, both in its position and relations and in the chemical and digestive properties of its contained fluid. It is impossible to be certain whether a cyst in this situation is pancreatic or peripancreatic merely from clinical examination, and difficult even if the case is operated upon unless a piece of the wall is

[1] Körte, quoted by Doran, 'Brit. Med. Journ.,' 1897, vol. ii.

removed and examined microscopically for the presence or absence of pancreatic tissue.

A point which might be useful is the presence or absence of fat necrosis. Its presence would be strongly in favour of a peripancreatic cyst secondary to pancreatitis, since it does not seem to occur in true pancreatic cysts.

What the relative frequency of peripancreatic effusions secondary to pancreatitis and of the pancreatic cysts really is it is difficult to determine. Clinically the term pancreatic cyst is employed to cover them both. My own impression is that the true pancreatic cysts are not so common, and the peripancreatic cystic accumulations less rare than would appear from the records of cases.

The mechanism by which the effusion becomes limited to the lesser sac depends on the sealing up of the foramen of Winslow. This may be one of the first effects of the pancreatic inflammation, or be due to pre-existing inflammation spreading from the common bile-duct, or, as in this case, the abnormally long cystic duct, and due to cholelithiasis.

As an example of other lesions of the biliary system causing obliteration of the foramen of Winslow, Rabé and Rey's[1] case of carcinoma of the gall-bladder may be referred to. The gall-bladder was adherent to the duodenum and colon by cholecystic adhesions, and the foramen of Winslow was obliterated.

The causes of pancreatitis are probably numerous. Among them are extension of inflammation to the pancreatic duct from the duodenum, or directly through the thin walls of the duodenal pouches, impaction of a calculus in Wirsung's duct, injury, and the occurrence of a specific infection analogous to mumps. The association of pancreatitis or pancreatic hæmorrhage with gall-stones is one which perhaps merits more attention than it has received, since the presence of calculi in the ducts may, by setting up cholangitis, render the walls of the ducts permeable to micro-organisms. Cholangitis may, by spreading to the biliary papilla, lead to an extension of the inflammation to the pancreatic duct and so to an ascending inflammation of Wirsung's duct.

Dr. Norman Moore[2] fifteen years ago drew attention to suppuration in the pancreas depending on the presence of gall-stones in the common duct. Some isolated cases have been recorded since, and

[1] Rabé and Rey, 'Bull. Soc. Anat.,' Paris, 1897, p. 841.

[2] Moore, 'Trans. Path. Soc.,' vol. xxxiii, p. 186.

the present is the third example of this association that I have seen; but it does not appear to be generally recognised that cholelithiasis is a cause of pancreatitis.

The distribution of the fat necrosis in this case was quite compatible with the view that it was due to the action of the fat-splitting ferment contained in this effusion occupying the lesser sac of the peritoneum, for the fat necrosis was found around the effusion, and the only distant spot where it was seen was one to which the fluid, by leaking through and along the adherent great omentum, could quite conceivably have gained access.

In this connection it is interesting to note that Flexner's[1] experimental researches have shown that it is highly probable that the steapsin in the pancreatic secretion sets up fat necrosis, that the escape of the pancreatic secretion into the peri- and para-pancreatic tissues is the origin of the fat necrosis, and that this escape is facilitated chiefly by lesions of the pancreas itself, and also by disturbances in its circulation.

April 5th, 1898.

---

39. *Chronic pancreatitis in diabetes.* (*Card specimen.*)

By H. D. Rolleston, M.D.

The pancreas was extremely atrophied and fibrotic, weighing 1½ oz. when fresh, and showed dilatation of the whole extent of Wirsung's duct, which became more marked at the splenic end. The duct was filled with clear fluid, and contained a number of small white calculi; many of them were embedded in loculi arising from the duct. Chemically they were composed almost entirely of carbonate of lime with a small percentage of carbonate of magnesium; there was only a trace of organic matter, and no sulphates, phosphates, or oxalates. This analysis was most kindly undertaken by Mr. Gardner, Lecturer on Chemistry at St. George's Hospital.

Microscopically the pancreas showed undoubted inflammation of

[1] Flexner, 'Trans. Assoc. American Physicians,' vol. xii, p. 203.

an advancing character, and, in addition, marked fibrous increase of old standing, with atrophy and disappearance of the glandular portion; some of the alveoli contained crystalline masses.

Of the 100 cases of pancreatic diabetes collected by Williamson ('Medical Chronicle,' vol. xv, p. 376, 1892), fibrosis was present in fourteen, and in one of them the pancreas was cystic in addition. He also describes at length the case of a man aged forty-five, with diabetes, in whom the pancreas weighed $4\frac{1}{2}$ oz., and showed marked fibrosis with cystic dilatations of its duct containing small calculi. The patient was alcoholic, and in this as in some other features resembled my case.

In the present instance the patient was a man aged 38, who had had syphilis and had been much addicted to alcohol. When admitted under my colleague, Dr. Ewart, he had jaundice and diabetes; he died with advancing pulmonary tuberculosis. The jaundice was due to intra-hepatic calculi (see p. 133).

The interest of the case is in the probable sequence of events, viz. alcoholic excess, gastro-duodenal catarrh spreading to the pancreatic duct and setting up chronic pancreatitis and so diabetes. There was definite evidence of advancing inflammation, so the change is not one of arterio-sclerotic atrophy comparable to granular kidney.

The kidneys showed arterio-sclerotic changes, the liver a mixed and multilobular cirrhosis, and both of them showed early lardaceous change.

January 4th, 1898.

V. DISEASES, ETC., OF THE GENITO-URINARY ORGANS.

1. *Speckled kidneys; irregular fatty degeneration of the renal cortex, possibly caused by plugging of small blood-vessels shortly before death.*

By F. Parkes Weber, M.D.

I consider this case should be noted on account of the very peculiar appearance presented by the kidneys at the necropsy. On removing the capsules the surfaces of both kidneys were found to be covered with small, irregularly shaped, but sharply defined streaks and blotches of an opaque yellowish-white colour. These spots extended a little into the substance of the cortex. Some of them had a wedge-like shape similar to that of minute anæmic infarcts. Some of them were not unlike the spots in the renal cortex which I observed in a case of general lymphadenomatosis of bones, and which were due to the deposition of microscopic phosphatic calculi.[1] In the present case, however, there was no grating in cutting through the blotches, as there was in cutting through the phosphatic deposit; and Mr. Shattock has shown the appearance to be due not to any mineral deposit, but to a localised fatty change in the renal epithelium of the areas in question.

Mr. Shattock, whom I must thank for his kind help, found that the white spots, when watched under the microscope and treated with dilute acetic acid, hydrochloric acid, nitric acid, or solution of potash, remained unaffected; whereas when sections in which the white spots had previously been recognised were soaked in absolute alcohol followed by ether, clove oil, and mounted in Canada balsam, the spots could no longer be observed. When sections are treated

[1] The microscopic calculi in the kidney of the case referred to are pictured in 'Trans. Path. Soc.,' vol. xlviii, plate vi, fig. 3.

and examined in glycerine, the white areas are resolvable into groups of droplets having all the characters of oil, and an osmic acid solution stains the droplets deep brown.

The kidneys were from a girl thirteen years old, who died September, 1896, from chronic heart failure in cardiac disease (mitral reflux and pericarditis), the result of rheumatic fever. The question arises, what was the cause of the very irregular fatty change in the kidneys? A possible explanation is that they were due to plugging of minute blood-vessels supplying the renal cortex; in other words, that the fatty degeneration of the renal epithelium in the pale white areas was due to the cutting off of the proper blood-supply to the areas in question. The wedge-like form of some of these areas, resembling that of anæmic infarcts, strongly supports this view. Some of the blood-vessels are full of short plump bacilli, doubtless *Bacillus coli communis*, and on the whole it seems very likely that the peculiar appearance noted at the necropsy is due to the blocking of minute blood-vessels of the kidneys by *Bacillus coli communis*, or to thrombosis resulting from the presence of these bacilli.[1] If this be the correct explanation the condition must be regarded as one occurring shortly before death.

It is no more surprising to find *Bacillus coli* present in the kidneys from cases of chronic non-infectious diseases than to find it associated with other microbes in kidneys from cases of prolonged infectious diseases.[2] In fact, in chronic cardiac cases like this the intestinal microbes are particularly likely to be disseminated by the blood-stream before death, because in such cases death usually takes place slowly.[3] R. Wurtz and M. Herman[4] in 1891 found that in about half of all bodies examined twenty-four to thirty-six hours after death, the *Bacillus coli* could be

[1] This explanation appears to me far more probable than that the vessels were blocked by minute emboli from the diseased cardiac valves.

[2] *Vide* "Certain Forms of Infection in Typhoid Fever," by Dr. Simon Flexner, in the 'Johns Hopkins Hospital Reports,' 1895, vol. v, p. 371.

[3] *Vide* S. Flexner, "A Statistical and Experimental Study of Terminal Infections," 'Journ. of Exp. Med.,' 1896, vol. i, p. 559. At the Johns Hopkins Hospital, out of 255 necropsies on cases of chronic heart or kidney disease, or both combined, bacteriological examination furnished evidence of a terminal infection by microbes having taken place in 213 cases, a negative result being obtained in the remaining 42 cases.

[4] "De la Présence fréquente du *Bacterium coli commune* dans les Cadavres," 'Archives de Médecine Expérimentale,' 1891, vol. iii, p. 734.

found in the liver, the spleen, or the kidneys, not rarely in all these organs. Many observers have confirmed these results, and Dr. L. Beco[1] has proved that in such cases the microbes must be disseminated during life by the blood-stream. He found that in necropsies on rabbits killed suddenly no microbes could be found in the spleen, &c., whereas in necropsies on animals which died comparatively slowly—especially if they had much gastro-intestinal catarrh—intestinal microbes could easily be found, which must therefore have gained an entrance into the blood-vessels during life, and have been disseminated by the circulation to the organs in which they were detected after death.

There is, therefore, abundant proof that when death takes place slowly, microbes (chiefly from the alimentary canal) are able to gain an entry into the circulation during life and are carried by the blood-stream to the various organs (as the spleen, liver, and kidneys), where they are ready to commence active growth directly death takes place. It is thus that the *Bacillus aërogenes capsulatus* may be disseminated during life, and produce early "*post-mortem* emphysema of the liver." I think that a peculiar appearance of the cardiac substance which I have once noted,[2] could only be explained on the supposition that microbes had been disseminated in the heart substance by the circulating blood shortly before death took place. In the present instance the microbes probably found their way to the kidneys rather earlier than usual before death, for the patchy, fatty change in the renal cortex is a phenomenon which—unlike the hepatic emphysema and change noted in the cardiac walls—could only have been produced during life. The importance of the *post-mortem* appearance in the present case lies in the fact that other interpretations of it, such as multiple minute emboli from endocardial disease, are likely to be suggested, but the

[1] Étude sur la Pénétration des Microbes Intestinaux dans la Circulation Générale pendant la Vie," 'Annales de l'Institut Pasteur,' 1895, vol. ix, p. 199.

[2] "Note on a Peculiar Post-mortem Appearance of the Cardiac Walls," 'Brit. Med. Journ.,' 1897, vol. i, p. 1474. The heart was that of a man aged fifty-six, who had gall-stones and carcinoma of the gall-bladder and cardiac valvular disease. The heart substance was studded with small globular pale areas, which seemed to be caused by the rapid post-mortem growth of microbes in the centre of these areas. Doubtless the microbes had already been disseminated during life by the blood-stream, and commencing to grow actively shortly after death, gave rise to the pale areas around them as an effect of the products of their metabolism on the muscle substance around them.

most satisfactory explanation is, I believe, the one given above. A similar explanation may perhaps be the correct one for the miliary fatty spots in the liver, which I have noticed at certain necropsies,[1] and to which I had previously been inclined to give a different interpretation.

March 1st, 1898.

---

2. *Congenital cystic liver with cystic kidney.*

By George F. Still, M.D.

[With Plate IV, fig. 1.]

The association of cystic liver with cystic kidney has been recorded many times in adults, but I have only been able to find one case on record in infancy, a case reported by Dr. Rolleston and Professor Kanthack. The pathology of this cystic condition is somewhat obscure; it seems possible, however, that its occurrence in infants may throw some light on the condition in adults. A consideration, therefore, of some further cases where a cystic liver has been found associated with cystic kidneys in infancy may be of value.

A female infant, aged 7 weeks, was admitted under the care of Dr. Lees at the Hospital for Sick Children. It was an eight months child. The abdomen was noticed to be enlarged when the child was fourteen days old. Wasting had been noticed soon after birth.

On admission.—Fairly healthy-looking child, good colour, no jaundice. Heart dulness increased, extending from mid-sternum to three-quarters of an inch outside the left nipple line; maximum impulse in fifth space just outside the nipple line. At the apex the heart-sounds were short and alike, *i. e.* "tick-tack" in quality; there was no bruit. Pulse 160 per minute. Lungs were normal.

The abdomen was very full; liver not noticed to be abnormal; no ascites. A mass was felt in each flank, vaguely reniform in outline, and extending forwards to within two inches of the mid-

[1] The second case in "Circumscribed Fatty Patches in the Liver," 'Trans. Path. Soc.,' 1896, vol. xlvii, p. 66.

line; the colon seemed to be situated in front of the mass on the left side, but was not defined on the right side. The masses were firm, with slightly irregular surface; there was no fluctuation and no tenderness. *Per rectum* the lower rounded edge of each mass could be distinctly felt, leaving just sufficient room for the rectum to pass down between them. The urine was noticed to be passed very frequently, and contained a large amount of albumen. A diagnosis of congenital cystic kidney was made.

A week later the infant became very dyspnœic, there was diarrhœa and vomiting, the face was grey, and there were slight convulsive movements, probably uræmic. Death occurred nine days after admission.

Post-mortem.—Weight 6½ lbs. Brain, examined carefully, but not microscopically, showed no trace of cystic change. The lungs and heart were normal. On opening the abdomen it was seen that the cavity was almost filled by the much enlarged kidneys, which weighed 15 oz. together (right 7¼ oz., left 7¾ oz.), the normal weight being about ⅝ oz. and ¾ oz. for right and left kidney respectively. The length of each was about 4¼ inches; the width was 2½ inches. Fœtal lobulation was present, as usual at this age. The colour was pale yellowish brown. The capsule stripped easily. The stellate veins were not unduly conspicuous. The surface presented a translucent appearance, which was due to innumerable closely packed cysts, none of which, however, projected on the surface.

On section the whole kidney had a honeycomb appearance, caused by the presence of numerous small, more or less tubular cavities, separated from one another only by fine septa; these cavities seemed to be larger and more numerous in the cortex than in the pyramids. The pyramids and the calices were easily recognised; the pelves and ureters were normal.

On slight pressure much yellowish, slightly viscid fluid, like serum, exuded from every part of the kidney substance, but unfortunately it was not collected, so that nothing can be said of its character except that its appearance certainly did not suggest urine.

The liver was about the normal size; its weight was 5 oz.; it was pale, and its surface was not quite so uniform as normal, having a finely stippled appearance, as if there were minute depressions scattered over the surface, but there was no "hob-nailing," and no gross irregularity of any kind. The surface

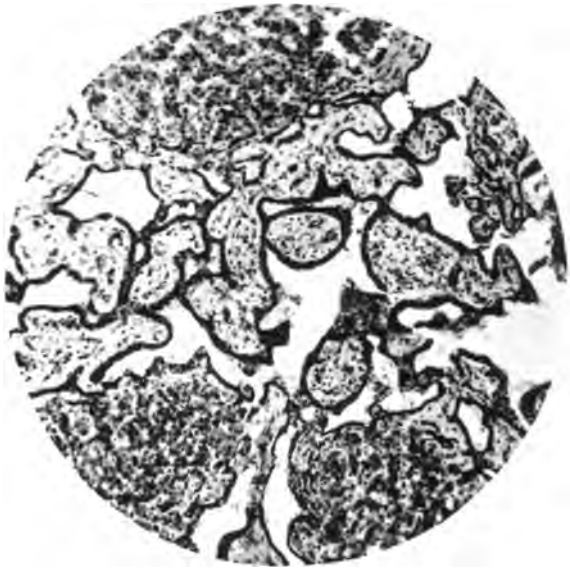

Fig. 1.

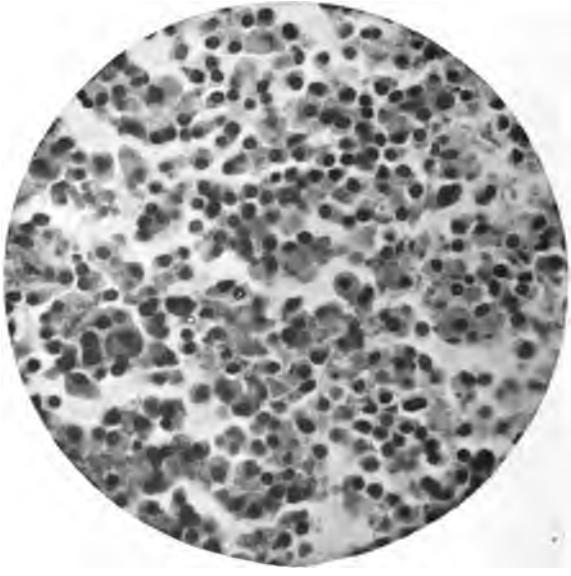

Fig. 2.

[illegible]

Fig. 1 [illegible]

[illegible]

[illegible]

Fig. 2 illustrates [illegible] (Page [illegible])

Section of the anterior lobe [illegible] of the central zone.



DESCRIPTION OF PLATE IV.

Fig. 1 illustrates Dr. G. F. Still's paper on a case of "Congenital Cystic Liver associated with Cystic Kidney in an infant seven weeks old." (Page 155.)

Section of a congenital cystic liver (under a high power).
(*a*) False ducts lined with cubical epithelium.

Fig. 2 illustrates Mr. Percy Furnivall's report on a case of Acromegaly. (Page 204.)

Section of the anterior lobe of the pituitary body, showing the degenerating cells of the central zone.

fibrosis, and no round-cell infiltration. There was some excess of connective tissue beneath the capsule.

Embedded in the connective tissue were the remarkable cavities mentioned. They varied in size from the normal bile-duct up to a cavity quite easily seen with the naked eye. Their shape was quite irregular; some of them branched in almost every direction (*vide* Plate IV, fig. 1). All of them were lined with epithelium, which varied from columnar down to subcubical. These cavities were by no means limited to the portal area; they occurred sometimes inside a lobule amid the normal liver cells, and they were numerous on the surface of the liver in the connective tissue beneath the capsule. I wish particularly to draw attention to the occurrence of these spaces on the surface of the liver, for it seems to me to have some bearing on the question of their nature. The parenchyma of the liver appeared to be quite normal, except that, as already stated, here and there groups of liver cells were found embedded in the connective tissue; the liver cells, however, showed no degeneration and no vacuolation. There was no definite dilatation of the bile capillaries; the minute round spaces seen in some parts between the liver cells were not larger or more numerous than are often seen in healthy livers at this age.

A second case, in which cystic liver was associated with cystic kidneys, occurred in a stillborn infant. For the notes of this case I am indebted to Dr. Rolleston, who has very kindly allowed me to make use of it.

The child was born apparently at full term. Both kidneys were found to be cystic throughout; the liver was very similar to that in the previous case. Microscopic examination showed both in kidneys and liver appearances similar to those described above. Associated with this cystic condition in this case there were webbed toes, also six fingers on one hand and an occipital meningocele. The importance of this association will be seen hereafter.

I have been able to collect altogether thirty-five cases of cystic liver associated with cystic kidney, including the two cases recorded here. Seven of these cases were recorded in the 'Transactions' of the Pathological Society,[1] twenty-three were collected from the literature of the subject, three were from museum catalogues

[1] Pye-Smith, 'Path. Soc. Trans.,' xxxii, 112; Bristowe, ibid., vii, 229, and x, 174; Wilks, ibid., vii, 235; Savage and Hale White, ibid., xxxiv, 1; Mahomed, ibid., xxxiv, 182.

(London and University College Hospitals, and the Royal College of Surgeons), and the remaining two are those recorded here.

The condition is much more frequent in women than in men; out of twenty-eight cases in which the sex is recorded, twenty-one were females, seven were males; making the proportion of females to males three to one. Only three cases occurred in infancy; the first case recorded here at eight weeks old, the second case still-born, and the case recorded by Dr. Rolleston and Prof. Kanthack ('Virchow's Archiv,' Bd. cxxx, p. 488) at four weeks old. All the remaining cases occurred in adults.

In seventeen out of twenty-six cases in which the age at death is recorded, the patient was over fifty years of age, in four cases the patient was seventy to seventy-six years old. The earliest age, excepting the infants, was thirty-nine years.

Death occurred in almost every case from uræmia, and in none of the cases were there any symptoms referable to the liver, except some palpable enlargement in some cases.

I do not propose to discuss the pathology of the cystic kidney here. It is, however, important to observe that in almost all cases where cystic kidneys are associated with cystic liver in adults, the kidneys show the same changes in the adult as in the infant, with a difference only of degree, the dilated tubes having become more dilated, and the kidneys consequently larger and more deformed, in some cases than in others.

It seems, therefore, only reasonable to attribute the condition to the same cause at all ages, and the most satisfactory explanation which has yet been suggested is, I think, that of Mr. Shattock ('Path. Soc. Trans.,' vol. xxxvii, p. 287), that the cystic condition is the result of a congenital malformation, the mesonephros having blended with the metanephros in the development of the kidney.

The first case recorded here certainly seems to support this view rather than any theory of inflammation, or of obstruction of normal tubules. The absence of any adhesion of the capsule, the curiously uniform character of the fibrosis, the entire absence of any round-cell infiltration, the healthy condition of the glomeruli, the absence of any distension of Bowman's capsule, and particularly the presence of perfectly healthy tubules embedded in the thick fibrous stroma, all seem to point to a congenital malformation rather than an inflammatory or obstructive lesion.

This last fact, the presence of normal tubules together with the

normal glomeruli, may explain why in many cases the subjects of this malformation survive to adult life and even old age; the number of normal tubules may be sufficient to carry on the necessary excretion until degeneration of arteries or increasing pressure by neighbouring cysts, or some inflammatory process to which such kidneys may be specially liable, hinders excretion and so produces the fatal result.

It has been assumed by almost every writer on the subject that the excess of fibrous tissue is necessarily the result of inflammation. Starting from this premiss they have almost invariably arrived at the conclusion that the order of events was primary interstitial nephritis, and secondary cyst formation by obstruction of tubules.

I venture to suggest that an entirely different theory is possible. Assuming the developmental origin of the cystic kidney, the excess of fibrous tissue may be most naturally explained by a survival of the fœtal condition in which great excess of mesoblastic stroma is the normal appearance. On this view the large amount of fibrous tissue in the kidney is not to be regarded as an increase due to intra-uterine inflammation, but as an irregularity of development accompanying the abnormal blending of the mesonephros with the metanephros.

This view seems to me to agree better with the facts than the inflammatory view, which would make us suppose in the first case recorded here, that in a kidney which only acquired its full development seven months before the child died, a nephritis could produce a fibrosis as extensive as that seen in an adult who has suffered for years with nephritis, and that the glomeruli and numerous tubules embedded in the fibrous tissue should yet remain healthy.

Moreover, assuming the adult cystic kidney to be also congenital, one would expect the fibrosis, if it be due to inflammation, to increase progressively, and it would be scarcely conceivable that life could be prolonged to fifty or seventy years of age; whereas if the fibrous tissue be merely a part of the malformation, one would not expect it to increase, and therefore the normal tubules and glomeruli embedded in it might remain normal indefinitely.

One fact also seems to have escaped all those who have regarded the cystic kidney in these cases as the result of interstitial nephritis, namely, that whereas interstitial nephritis is far commoner in men than in women, the proportion of males to females

according to Fagge being five to one, the cystic kidney associated with cystic liver is far commoner in women than men, as I have already shown, the proportion of males to females being one to three.

It is to the pathology of the liver in these cases that I wish particularly to direct attention.

First, it will be seen from the microscopic examination of the cases recorded here, that the changes in the liver in a child who died at the age of eight weeks (one might almost say four weeks, for it was an eight months' child) and in a stillborn child are, in their essential features, identical with those found in the cystic livers of almost all the adult cases mentioned. (The exceptions are the four cases in which so-called "vacuolation" has been described.) Some of the illustrations of the microscopic appearance of the cystic liver in adults are the exact facsimile of those shown here from the infant, and in others the only difference is in the size of some of the irregular spaces, which have become more dilated, forming large cysts visible to the naked eye.

One can hardly imagine that so extraordinary a change could be due to different causes at different ages, and one is driven to the conclusion that whatever explanation be adopted for its occurrence in adults must also be adopted for the cases in infancy and fœtal life. The causes that have been suggested for its occurrence in adults are—

(1) Cirrhosis, similar to that supposed to occur in the kidney, causing dilatation of bile-ducts and formation of new bile-ducts. This view is adopted by most writers on the subject.

(2) Vacuolation of the liver-cells, possibly by some degenerative process within them (Pye-Smith, Waring,[1] Savage, and Hale White).

(3) A spontaneous proliferation of the walls of the bile-ducts, occurring in adult life, and giving rise to a "cavernous biliary angeioma" (Sabourin[2]).

(4) New growth (Wilks, Rindfleisch,[3] Malassez[4]).

None of these theories seem to me to explain satisfactorily the cases in infants.

[1] Waring, 'Diseases of the Liver,' Edin. and Lond., 1897.

[2] Sabourin, 'Archiv. de Physiol.,' vol. xiv.

[3] Rindfleisch, 'Lehrbuch der pathol. Gewebelehre,' 402.

[4] Malassez, quoted by Claude, loc. cit. infra.

The cysts cannot be merely dilated bile-ducts; they are far too numerous, and occur, as I have shown, just under the capsule at parts of the liver where there are normally no spaces lined with cubical epithelium. Further, there is no jaundice, and I wish to lay stress upon the fact that *in not a single case, so far as recorded, has there been any jaundice*, a fact which must throw grave doubt on any obstruction theory.

Moreover, the cases of most complete obstruction, those of congenital absence or atresia of the larger bile-ducts, show no such proliferation of ducts. A still stronger argument is the fact that it has actually been proved, apart from the constant absence of bile from these spaces, that the injection of coloured fluid into the bile-ducts fails to inject these cysts, *i. e.* there is no connection with the bile-ducts. I may add here that on careful examination it is, I think, possible to find a perfectly normal bile-duct in each portal area.

Proliferation of bile-ducts as part of a cirrhosis, if it ever occur, does not give rise to the appearances seen here, even in the most marked cases of "biliary cirrhosis." The cystic dilatation of the duct-like spaces, the presence of spaces lined with cubical epithelium all over the surface of the liver under the capsule, are changes not found even in the most advanced cases of acquired "biliary cirrhosis."

There is nothing whatever to suggest vacuolation in the cases recorded here, nor in the majority of the cases described, so that it hardly needs to be discussed. The four cases which it has been suggested may belong to a different category, or these so-called vacuoles, which it is admitted are partly extra-cellular, may be part of a developmental peculiarity, and so be simply a part of the malformation suggested below. It is curious that in one of them at least (Dr. Rolleston's and Prof. Kanthack's case) the vacuoles were mainly outside the cells, and the appearances otherwise were identical with those I have described.

"Cavernous biliary angeioma" seems an excellent descriptive term, but Sabourin considered that this extraordinary angeioma was a complication of chronic nephritis in adult life, and began as a fibro-epithelial outgrowth in the biliary passages; in these fibro-epithelial nodules numerous alveoli developed, and so the appearance of an angeioma was produced. But apart from the fact that no such complication is known to occur in the liver in cases of

interstitial nephritis without cystic kidney, this view does not explain the spaces under the capsule, nor the presence of normal bile-ducts in the portal areas; besides which it is difficult to imagine the occurrence of an intra-uterine nephritis, which within seven months is complicated by a neoplastic development of duct-like spaces lined with perfect epithelium throughout the liver, and it has already been shown that there is good reason for believing that the cystic kidney is not part of an inflammatory change.

New growth seems equally unlikely; the only growth suggested by the appearance is a cystic adenoma, which probably never forms so diffuse and uniform an infiltration; moreover, it utterly fails to explain the association with the cystic kidney, in which there can hardly be any such growth.

I venture to suggest a theory which seems to be less open to objection than those hitherto advanced.

It has already been mentioned that the cystic liver found in adults shows exactly the same changes as that found in infants, except that, as in the kidney, there is often a variation in degree.

In view of this fact it seems reasonable to suggest that the cystic liver associated with cystic kidney in adults is, as in the infant, a congenital condition, and further, that as the cystic kidney is almost certainly a malformation, so the cystic liver also is simply a malformation, and not the result of disease.

The formation of the bile-ducts is unfortunately not clearly understood, but we may accept the common view that some of the hypoblastic cells of the original diverticulum from which the liver is formed, are differentiated to form bile-ducts, and it is known from recent work (Toldt and Zuckerkandl, 'Wien. Sitzb.,' Bd. lxxii, p. 31) that the columns of hypoblastic cells which are formed from the duodenal diverticulum have a definite lumen at an early stage. It is thus easy to understand how a very slight irregularity of development, leaving some of the columns with their original lumen, would produce tubes lined with an epithelium which, as fluid accumulated within them, would become the spaces we see lined with columnar, cubical, or subcubical epithelium. If at the same time the bile-ducts proper are normally developed, as appears from the microscopic sections, one can understand the entire absence of symptoms from the liver in these cases.

The excess of connective tissue may be explained, as in the case of the kidneys, by a persistence of the fœtal mesoblastic stroma,

i. e. as a malformation, not a product of inflammation, and it is to be remembered that there is normally a persistence of the mesoblastic stroma wherever the bile-ducts run, and it may be that each of these false ducts in the same way determines the persistence of a certain amount of mesoblastic stroma around itself.

That there may be a formation during the development of the liver of such false ducts, is proved by the occurrence of the "vasa aberrantia," the isolated duct-like spaces which are found on the surface of the liver in certain parts, and perhaps also by the existence of cæcal protrusions from the normal bile-ducts.

If this view be correct the liver condition is not a progressive one, and therefore the subjects of this malformation may live to old age with no symptoms referable to the liver, unless the distension of some of the false ducts increases so as to produce mechanical effects, which apparently very rarely happens.

The entire absence of jaundice which is so striking in the clinical history of these cases, seems to be more satisfactorily explained by this theory than by any of the other views mentioned.

A very strong argument in favour of the view which I have suggested is found in the tendency to association of the cystic liver with congenital malformations, the tendency for two or more congenital malformations to occur together being a well-known fact.

Apart from the association with cystic kidney, which, as has been shown above, is probably a congenital malformation, other deformities were found in the cases which I have collected. In one case there was an undescended testis, in another there was a misplaced kidney. The most striking example is the second case recorded here (Dr. Rolleston's), in which polydactylism, a meningocele, and webbed toes were associated with cystic liver and cystic kidney.

The relation of the cystic conditions of brain and pancreas which have been occasionally recorded in these cases, to the cystic liver and cystic kidney, is certainly not less intelligible on the view I have suggested, than on the other views mentioned; a congenital malformation seems to be the most likely explanation of the associated cystic condition of the pancreas, and congenital cystic conditions are known to occur in the brain.

Other references to the cases here collected are:—(1) Kennedy, 'Lab. Rep. Coll. Phys. Edinb.,' vol. iii, p. 177; (2) Paterson, 'Brit. Med. Journ.,' 1890, vol. ii, p. 735; (3) Frerichs, 'Diseases of the Liver' (transl. Murchison), ii, 223; (4) Michalowics, 'Dégénérescence kystique des reins et du foie,' Paris, 1876; (5) Courbis, 'Kystes du foie et des reins,' Paris, 1877; (6) Nauwerck u. Hufschmid, 'Beitr. z. path. Anat.,' Jena, xii, 9; (7) Dmochowski u. Janowski, ibid., xi; (8) Caresme, 'Bull. de la Soc. anat. de Paris,' xl, 133; (9) Jeffroy, ibid., xliii, 231; (10) Leboucher, ibid., xliv, 243; (11) Chantreuil, ibid., xlii, 439; (12) Nicolle, ibid., lxiv, 112; (13) Demantké, ibid., lxix, 323; (14) Demantké et Fournier, ibid., lxx, 116; (15) Claude, ibid., lxxi, 109; (16) Komorowski, ibid., li, 12.

December 21st, 1897.

---

3. *Cystic disease of the kidneys and liver.*

By Raymond Johnson, M.B.

A. C—, a married woman 53 years of age, was under the care of the late Mr. Marcus Beck in University College Hospital. With the exception of habitual constipation her previous health had been good. There was a history of bright blood being passed in the urine twelve years ago, and again during a period of about a week four years ago. For five months there had been occasional sickness after food, which increased in frequency so that during the last month the patient had vomited six times or oftener every day. No swelling of the abdomen had been noticed.

On admission to the hospital the patient was very weak and emaciated, and complained of abdominal pain; the skin generally was of a dark brownish tinge, but there was no jaundice.

The abdomen, especially below the umbilicus, was retracted, and the contracted coils of intestine were easily seen. Each lumbar region was occupied by a large tumour having the characters of an enlarged kidney. The tumour on the left side was much the larger of the two, and each was distinctly lobulated, some of the

most prominent projections feeling like tense cysts. There was no apparent enlargement of the liver and spleen. The temperature was normal or subnormal. The quantity of urine measured during two periods of twenty-four hours was 34½ and 25 oz., and the total amount of urea 135½ and 120½ grains; reaction acid, sp. gr. 1010, trace of albumen, slight deposit of pus and epithelial cells, no blood. Whilst in hospital there was no sickness, but the patient became weaker. Death occurred quite suddenly on the sixth day after admission; ten minutes previously the patient was quite conscious, and had listened with interest to a letter from her husband.

Post-mortem examination.—The *thoracic viscera* were healthy; there was no hypertrophy of the left ventricle.

Kidneys: the right weighed 24 oz., the left 62½ oz.; the right measured 7 by 4½ inches, the left 9 by 5½ inches. With the exception of the difference in size the two organs presented similar appearances. Each was completely converted into a mass of cysts, of which the most superficial were the largest, some attaining the size of a Tangerine orange, and were very thin walled. Here and there between the larger cysts were areas of indurated kidney substance riddled with minute cysts, many of which contained cheesy material. The fluid in the largest cysts was in some clear and straw coloured, and in others turbid and slightly opalescent; acid reaction; nearly solid with albumen on boiling; trace of peptone; 0·7 per cent. urea; cholesterin crystals. Both ureters normal.

Adrenals normal.

Liver: weight 44½ oz., not enlarged. On section it was studded with cysts varying in size from a hazel-nut to such as were only just visible to the naked eye. The larger cysts were subdivided by incomplete septa, indicating that they had been formed by the coalescence of smaller spaces; some contained clear fluid and others an opaque gelatinous material. The liver substance appeared healthy; the capsule was not thickened.

Spleen 3½ oz., contained a soft cheesy mass as large as a hazel-nut; otherwise normal. One *ovary* was cystic. No examination of the *brain* could be made.

Microscopic examination.—Kidney: the cysts lie in an abundant fibrous tissue containing numerous small oval and spindle cells, and in some areas showing a more dense infiltration with round

cells. Lying in the stroma between the cysts are large numbers of renal tubules, which for the most part are small and atrophied, and often represented merely by a narrow tract of small spheroidal cells. In some parts the glomeruli show a normal appearance. The smaller cysts are lined with a regular layer of cubical epithelium, and the coagulated contents appear as a finely granular material. In the larger cysts the epithelium is flattened.

Liver: except for the changes concerned with the formation of cysts in its substance the liver appears normal; there is no intercellular cirrhosis, and the capsule is not thickened. The cysts lie chiefly in the portal canals, and are surrounded by an abundant dense fibrous tissue containing very few cell-elements. In many parts the closely packed spaces are separated merely by narrow bridges of fibrous tissue, which by absorption lead to the formation of large cysts by the coalescence of the smaller ones. Many of the cystic spaces have lost their epithelium, but, especially in the smaller ones, the lining remains, the cells being either cubical or columnar in shape. In some parts of the sections examined the epithelium-lined spaces, surrounded by fibrous tissue, extend irregularly from the portal canals into the surrounding lobules.

Spleen: the small caseous nodule in this organ above described presents microscopic appearances very suggestive of a softened gumma. The central part is structureless and granular, whilst the periphery is formed by a zone of cellular connective tissue.

Remarks.—As the interesting subject of associated cystic disease of the kidneys and liver has recently been discussed by Dr. Still before this Society (see pp. 155—165), I have brought forward this additional example of the disease in the adult.

The appearances seen in the liver seem clearly to indicate that the cysts have arisen from dilatation of certain biliary ducts, and the forcible arguments which Dr. Still (who has included this specimen in his series) adduced to show that in his specimen, obtained from an infant, the changes were to be regarded rather as a congenital malformation than as a result of inflammation, might almost equally well be applied to this example of the disease in the adult.

In the kidney almost all remains of normal structure are lost, and in the present condition of the organ it seems impossible to form any conclusion as to the original cause of the cystic change. Assuming, however, the latter to have been congenital in origin,

there can be little doubt that a certain degree of interstitial inflammation has supervened, for, unlike the fibrous tissue surrounding the cysts in the liver, the connective-tissue stroma of the kidney is in parts richly cellular.

The presence of the softened nodule in the spleen, presumably a gumma, is of interest. There were no other evidences of syphilis, and I cannot believe that the association with the cystic changes in the kidneys and liver was more than accidental. The only way in which any connection could be traced between them would be the very doubtful assumption that the cystic changes in the liver and kidneys resulted from an inflammatory connective-tissue overgrowth in the organs, and the still more improbable assumption that this overgrowth was syphilitic.

The specimens are preserved in the museum of University College, Nos. 3424 and 3425.

January 4th, 1898.

---

4. *Chronic interstitial nephritis with cysts in the renal pelvis, double ureter and malformation* (?) *of the bladder.* (*Card specimen.*)

By Arthur Voelcker, M.D.

The left kidney shows chronic interstitial nephritis with the formation of numerous cysts.

In addition to the cysts in the kidney substance, several cysts are seen in the renal pelvis and in the left ureter. The left ureter is double in its upper five inches. The bladder shows a bridge of bladder tissue covered with mucous membrane lying behind the median lobe of the prostate, but considerably in front of the line joining the vesical ends of the ureters.

There was no history of the use of a catheter. The right kidney was very small, weighing only 2 oz., and showed chronic interstitial nephritis with cysts.

From a man aged 73, who died from uræmia.

November 16th, 1897.

5. *Preliminary note on atrophy of the kidney produced experimentally.*

By JOHN ROSE BRADFORD, M.D., F.R.S.

(From the Laboratory of the Brown Institution.)

THE following observations were made in order to determine whether obstruction of the ureter could produce atrophy of the kidney. It has long been known that atrophy of the kidney has been found associated with the presence of calculi, and some observers have thought that complete and sudden blocking of the ureter might cause atrophy of the kidney, whereas incomplete and gradual obstruction of the ureter would cause hydronephrosis or some other form of dilatation of the kidney. All the experiments hitherto performed have been carried out on dogs. One ureter is exposed in an anæsthetised animal, ligatured with silk and divided; usually the ureter has been tied and divided as close to the bladder as possible. After a variable period (eleven to forty days) an incision parallel to but slightly above the previous incision in the anterior abdominal wall was made, the free end of the ureter found, and brought up to the surface of the abdomen. The wound was then sutured in such a manner as to leave the extremity of the ureter protruding from the lower angle of the wound, and it was secured in this position by two horsehair sutures passing through the ureter and the edges of the skin. The ureter was then incised and the retained urine allowed to escape, and its amount measured if possible. The animal was then kept for periods varying from seven to fifty-one days.

Some difficulty was experienced in maintaining the patency of the urinary fistula, and the best method was to leave about one quarter of an inch of the ureter protruding from the wound.

In all cases the ligature of the ureter was followed by distension of the kidney, and a quantity of altered urine varying from 40 c.c. to 70 c.c. was let out at the moment of incising the ureter at the second operation. In the great majority of cases the fluid was clear and contained abundant urea, but in three out of twelve cases the fluid was grumous and puriform. These cases, however, are not

further considered here, and it is to be understood that the atrophy to be described ensues in the cases where the obstruction of the ureter has led to a simple hydronephrosis. In no case was ligature of the ureter followed by suppression of urine as has been described in the human subject after obstruction of the ureter.

After the second operation, which really consists in draining the distended and dilated kidney, a remarkable result is seen. The kidney resumes its normal shape very closely, but the organ becomes very much smaller than it was previously. It does not become a shrivelled sac, as might perhaps be expected, but to the naked eye it assumes the form of a normal but very small kidney. During the stage of distension the medulla has, as is well known, become flattened out, and forms a layer of kidney substance bounding the greatly dilated renal pelvis. After draining, the medulla reassumes its normal arrangement, and on inspection of such a kidney it is difficult to believe that it has ever been distended to an extent sufficient for it to contain some 50 c.c. of urine. Although the kidney not only returns to a normal shape, but also undergoes this great diminution in size, so that it may be but one third to one quarter of the size of its fellow, the ureter remains thickened and dilated, and thus affords a great contrast to the kidney. This atrophy is produced very rapidly, and some of the specimens now shown were obtained after a period of draining lasting two to three weeks.

The microscopical appearances of these small atrophied kidneys have been investigated by Mr. T. W. P. Lawrence and myself, and the following results have been observed. There is no general overgrowth of the interstitial fibrous tissue, and hence the diminution in the size of the organ is not due to any form of cirrhosis. There is a slight increase of fibrous tissue along the course of the larger vessels. The glomerular vessels show some signs of compression, such as shrinking and irregularity, and the glomerular chamber is distended, and its walls show signs of shrinking. The renal tubules are crowded together, and many of them, especially in the medulla, have disappeared. Some tubules have lost their lining cells, but in many they are retained; the cells are, however, much smaller than the normal kidney cells. The most important and interesting change, however, is that the renal cells lose all their granules, and their protoplasm becomes quite clear and glass-like, the nucleus remaining clearly visible and staining well. The changes in the medulla are most marked towards the pelvis,

whereas the cortical changes are most obvious near the surface of the kidney, and all changes are least marked in the boundary zone.

The atrophy is accounted for by (i) the diminution in the size of the renal cells, (ii) the disappearance of many tubules, and (iii) the crowding together of the remaining tubules.

December 7th, 1897.

---

6. *Hæmatocele of a hydronephrotic kidney.*

By JOHN ROSE BRADFORD, M.D., F.R.S.

JAMES F—, aged 44, was admitted into University College Hospital on October 1st, 1897, suffering from an attack of delirium tremens, and also on account of severe hæmaturia.

On the morning of September 30th he found that he was unable to pass water; a doctor was called in, and on passing a catheter a quantity of blood-stained urine and some blood-clots were drawn off. Since this he has had some pain and difficulty in micturition, but there has been no further retention. Six months ago the patient passed blood in the urine for a week, but he had no pain, and the hæmaturia ceased and did not return until the present attack. He complains at the present time of an aching pain across the loins, but he states that he has had no previous illness, and there is no history of any attack suggestive of renal colic.

On admission the patient was a sallow, unhealthy-looking man; he was very nervous, excited, and trembling. The pulse was 90, the respirations 20, and the temperature 100·6° F.

On examining the abdomen a large tumour was felt in the left hypochondrium extending down to below the umbilicus. Its surface was rounded, and the lower border convex. The tumour filled up the loin and did not fluctuate, and was resonant to percussion anteriorly. The tumour was not tender.

No other abnormal signs were detected in the chest or abdomen, with the exception that there were a few râles at both bases.

The urine contained a large quantity of blood, and was bright

red in colour. Microscopic examination revealed the presence of large numbers of blood-corpuscles, but no casts were found.

On October 3rd the patient suddenly refused all food, he became very violent, and had visual hallucinations. The general weakness increased, the tongue became dry and brown, and the patient died on October 5th.

Post-mortem examination.—A small calcareous mass was found at the right apex. The left lung was adherent, and both lungs were congested. The heart was fatty; the liver was also fatty; the brain, stomach, intestines, and spleen were normal.

The bladder was normal, but contained blood-stained urine, and the orifice of the left ureter into the bladder was normal, but the left ureter was slightly dilated and contained blood-clot, especially at its upper part.

The right kidney weighed 6½ oz., but showed no signs of disease.

The tumour felt during life proved to be the left kidney.

The following description of the tumour refers to it after it had been hardened by the formalin method.

The left kidney forms a solid tumour that measures, after hardening in formalin, 6½ × 4¼ × 3½ inches. The surface was smooth and not unduly adherent to the surrounding tissues; the capsule is not thickened. On section the tumour is seen to consist of a mass of blood-clot, which, however, varies in colour and appearance in different parts. The blood-clot is surrounded by a thin layer of indurated renal tissue, measuring on an average ⅛ to ¼ inch in thickness, and it is evident that the clot is filling the spaces of a dilated kidney. Septa of indurated renal tissue can be seen passing in from the periphery towards the hilum.

On partially removing the blood-clot the organ presents the usual appearances of a greatly dilated kidney. The section shows the clot within each dilated calyx to be decolourised and laminated in the greater part of its extent, and in the remainder dark red and homogeneous.

A large irregular stone 1¾ inches long is embedded in the middle of that portion of the clot that occupies the pelvis of the kidney; the clot in this situation presents a spongy appearance, and is partly broken down into a thick greyish fluid. The clot lying immediately in contact with the walls of the renal pelvis is bright red in colour and apparently recent. On removing this the surface of the mucous membrane of the pelvis is seen to be thickly

covered with papillary growths. These extend down into the ureter for 1½ inches. The extent of the area occupied by these growths on each side is about 2½ × 1½ inches. In the lower part of this area the papillary growths reach a maximum of about ½ inch in height; in the upper part of the surface they appear as low rounded elevations, and these are also found encroaching on the walls of the dilated calyces.

A microscopic section of the upper part of the ureter and pelvis shows great thickening of the wall of the ureter with branching fibrous processes springing from its inner surface, and these are covered with proliferated epithelium except at their tips, where the epithelium has been shed. There is no epithelial ingrowth into the wall of the ureter or pelvis. The papillæ contained large vessels. The indurated kidney tissue showed on section that little real kidney tissue remained, being almost entirely replaced by dense fibrous tissue with scattered tubules through it; the glomeruli, however, are still quite distinct.

There was no thrombosis of the renal veins.

In this case the sequence of events was probably as follows:—The stone caused the hydronephrosis, and then hæmorrhage occurred from the highly vascular and villous surface of the pelvis of the kidney. The main interest of the case lies in the fact that the blood-clot caused the hydronephrotic kidney to become quite solid; the cavities contained no urine. The presence of this large solid tumour with hæmaturia led to a diagnosis of malignant disease of the kidney, but, as the examination showed, there were no signs of a growth in any part of the mass.

May 3rd, 1898.

---

7. *A case of double pyonephrosis caused by impaction of renal calculi.*

By L. Freyberger, M.D.

Mrs. A. T—, aged 37, housewife, died at the Great Northern Central Hospital on January 9th, 1898, from pyonephrosis. At the *post-mortem* examination, twenty-six hours after death, the

following conditions were found. Body pale, emaciated; extensive livid *post-mortem* stains on the back of the trunk and extremities. Rigor still present. Head not opened. Mouth, throat, larynx, pharynx, œsophagus, and trachea natural. Both lungs adherent at their apices, congested and œdematous. Heart small; right ventricle flabby, left contracted; wall of left ventricle half an inch thick, its cavity small; all valves and ostia natural. Heart muscle rather firm. No pericardial effusion. Liver large, pale, cloudy; consistence diminished. Gall-bladder natural. Spleen not enlarged, soft. Intestinal tract natural; cæcum and ascending colon have a long mesocolon, and are perfectly unattached as far as the hepatic flexure, which is firmly attached to the anterior aspect of the right kidney.

The right and left kidneys are converted into large flabby bags, measuring 5 × 3 × 2½ inches; on being opened the bags are found to be sacculated. The left contains pus and urine; the pelvic end of the ureter is wide enough to admit of the introduction of one's thumb; it contains no stones. The bag of the right kidney contains eight compartments, in seven of which there are stones of irregular shape, varying in size from a plum stone to a large walnut; the stones are dark reddish brown, and consist of uric acid and urates; one large stone forms a complete cast of the pelvis. There is very little secretory substance left, but what remains shows chronic parenchymatous and interstitial nephritis. Both ureters are dilated, the left more than the right. A small elongated stone, the size of the stone of a date, is impacted in the left ureter near its insertion in the bladder.

Both kidneys, the ureters, and bladder contained purulent urine.

The patient had had no illness previous to admission, and had never passed any stone or gravel.

She was admitted on December 31st on account of a violent pain in the left side, and died on January 9th with the symptoms of collapse.

February 15*th*, 1898.

8. *Adenoma (?) of kidney.* (*Card specimen.*)

By Stanley Boyd.

Removed from a lady aged 36, who had suffered from three rather severe and many slight attacks of pain in the left loin and left leg during the five months previous to the removal of the kidney. The pain, though severe, was never very severe; it was not accompanied by vomiting nor by any disturbance of micturition or alteration of the urine. In the left loin there was a large and very moveable tumour, almost certainly renal; it was not at all tender.

The tumour was spheroidal in form, and occupied the kidney below the hilum, the upper half being quite normal. The surface showed a few rounded bosses, softer than the rest of the mass, though the whole tumour was elastic. On section the growth was strictly circumscribed by a fairly thick capsule. The growth was divided into somewhat rounded masses by septa. It tore with a markedly granular surface.

Under the microscope the growth consisted of spaces lined by large epithelial cells, like renal epithelium, and filled by papillary processes of the most complex form.

March 15th, 1898.

Note.—August, 1898. A tumour, much larger than the original mass, now occupies the position of the left kidney; so, in spite of its apparent encapsulation, it is probably incorrect to call the original tumour an adenoma.

---

9. *Tumour of left kidney; cystic adenoma?* (*Card specimen.*)

By H. Littlewood.

Patient a woman aged 55. I was asked to remove the kidney by Dr. Barrs, under whose care the patient had been admitted into the infirmary. Left lumbar nephrectomy performed on December 7th, 1897. Patient made a good recovery.

History.—Pain in left lumbar region for two years; six months

before the operation patient commenced to pass blood in the urine, and did so at interval for four months. For the last two months patient has not passed any blood, but has suffered great pain, and the tumour has increased in size.

The tumour forms a prominence on the outer surface of the kidney. It is about the size of an orange. On section it appears to be quite encapsuled, and processes from the capsule extend across the tumour in various places. There are several cysts. In places the growth is very friable, and there are many hæmorrhages.

Microscopical examination.—In some parts of the tumour are spaces lined with cubical epithelium. In other parts there are masses of cells of the same type.

February 15th, 1898.

---

10. *Papillary adenoma of the kidney.* (*Card specimen.*)

By F. Parkes Weber, M.D.

Description and Remarks.—A man, aged about 72, was suddenly attacked with severe hæmaturia, and died a day or two afterwards in spite of treatment by ergot, &c. I am indebted to my colleague, Dr. Michels, for kindly allowing me to examine and describe the condition of the kidneys. At the necropsy a fairly large blood-cyst was found in one kidney, and there was some extravasation of blood into the perinephritic connective tissue. There were likewise a few subcutaneous petechiæ on the body. In each kidney there were two or three little whitish tumours of a more or less globular form. Most of them must have measured about 3 mm. in diameter, but one, the largest, situated just beneath the capsule, was, I should say, 6 or 7 mm. in diameter; this was the one selected for microscopic examination. The prostate gland was moderately enlarged.

Microscopical examination shows that the renal tumour consists of tubes lined by small epithelial cells of more or less cubical form. The tubes are filled with delicate, branching papillary outgrowths covered with the same kind of cubical epithelium. The fibrous

tissue forming the framework of the tumour is very scanty, the greater portion of the growth consisting of the epithelium lining the tubes and covering the intra-tubular papilliform growths. Most of the tumour is surrounded by a fairly thick fibrous capsule, formed apparently from the surrounding renal tissue, which has been compressed by the growth. The kidney in other respects shows the characteristic changes of slight interstitial fibrosis. In the compressed tissue close to the tumour are some minute concentrically marked "corpora amylacea," staining deeply with hæmatoxylin.

Part of the prostate was likewise examined. The sections show a thick fibrous framework containing irregularly shaped cysts lined with epithelium, and some of them containing corpora amylacea. There is a tendency in some of these cysts to papillary outgrowths, as in the kidney tumour, and the idea suggests itself that the renal growths might possibly be secondary to a growth in the prostate. Of this, however, there is no sufficient evidence, and on referring to the literature of renal adenomata it appears to me improbable that the growths in the kidneys were metastatic from growths in other organs.

Dr. Rolleston has kindly told me of a number of articles on renal adenomata, of which that by Dr. Kelynack [1] gives a very considerable bibliography of the subject. The structure of the growth described by Dr. Kelynack appears to be very similar to that of the present case. In a section kindly lent me by Dr. Rolleston the growth likewise appears to be similar. In another class of renal adenomata (as shown in the illustration accompanying an article by Rolleston and Kanthack [2]) the epithelial cells are perhaps larger, and contain much fat. It is possible that the adenomata with larger epithelial cells have their origin in the convoluted tubules, whilst the adenomata with very small cells are connected with renal tubules lined with smaller cells, such as the collecting tubules. The renal tumours of adrenal origin form, of course, an independent class by themselves.

Charles Sabourin, [3] who made an especially careful study of

[1] T. N. Kelynack, "Malignant Papilliferous Cyst-adenoma of the Kidney," 'Journal of Pathology,' 1897, vol. iv, p. 236.

[2] Rolleston and Kanthack, "A Peculiar Hæmorrhagic Tumour of the Kidney," 'Journal of Pathology,' 1894, vol. ii, p. 80.

[3] *Vide* Sabourin, "Sur quelques cas de cirrhose rénale avec adénomes multi-

renal adenomata, pointed out that they are especially liable to occur in kidneys affected with interstitial nephritis. Hæmaturia is the symptom which such tumours are most likely to give rise to during life, but the majority of the small ones seem to have been found by chance at *post-mortem* examinations, without any symptoms during life being recorded.

In the present case the fatal renal hæmorrhage was, I think, most probably connected with an adenomatous tumour, which became broken up by the extravasated blood, and so escaped notice at the *post-mortem* examination. The petechiæ below the skin indicated that some general hæmorrhagic tendency likewise existed at the time of death.

May 17th, 1898.

---

11. *A case of lympho-sarcoma of the pelvis of the kidney.*

By Charles Powell White.

This is the kidney of a child aged 6, who was in the General Hospital, Birmingham, under Dr. Saundby. The child had been suffering from ascites for six months. There were at no time any symptoms pointing to the kidney being affected.

The kidney shows, situated between the mucous membrane of the pelvis and the pyramids, a firm red mass of growth which does not invade the kidney substance. The kidney itself is not enlarged, and externally there are no signs of growth. The lining membrane of the pelvis is smooth. The growth passes out at the hilum of the kidney, and down along the course of the ureter. It also passes upwards behind the supra-renal body, and across the middle line to the other kidney. The tissues round the kidney are much thickened from chronic inflammation.

There are secondary deposits in the submucous and subserous coats of the intestines throughout their whole length; these deposits are about the size of a pea, and are firm. They are especially

ples," and "Les adénomes hémorrhagiques du rein," in the 'Revue de Médecine,' 1884, pp. 441 and 874.

numerous in the transverse colon, which is much thickened and hypertrophied.

There are deposits in the mesentery and the lesser omentum. There are none pressing on the portal vein. There are also deposits in the pancreas.

Microscopically the growth consists of round cells with large nuclei contained in a delicate intercellular network of interlacing fibrils. The growth does not penetrate the kidney substance itself. In a section of the pancreas the growth is seen passing along the interlobular septa.

In the intestine the growth involves the submucous, muscular, and subserous coats.

May 17th, 1898.

---

12. *Primary carcinoma of kidney.* (*Card specimen.*)

By Cecil F. Beadles.

The kidney retains more or less its natural size and appearance, but is more globular in outline, measures about 4 inches in length, and weighs 9 oz. It presents no irregularity on its exterior, but contains a considerable amount of fat in the capsule.

On section there is seen a central cavity, representing the pelvis, with smooth walls and ragged growth protruding in places, and in the recent state this was filled with pus-like fluid, but there were no calculi present. Entirely surrounding the cavity, and extending from it to the capsule, is a uniformly tough, pale, fibrous-like tissue, in which no demarcation of cortical or pyramidal portions of renal structure are distinguishable, although parts are of a more yellowish tint.

Sections reveal the presence of a glandular carcinoma. Areas of kidney tissue exist in which the renal epithelium is almost entirely in a necrotic state, the cells of both tubules and glomeruli being swollen and glandular, with but few nuclei discernible. The stroma is increased in amount, and the connective-tissue nuclei are also indistinct. It is not easy to distinguish between necrotic renal tissue and new growth in a similar condition, for there are many

alveolar spaces entirely occupied by degenerated cells; however, there exist places where irregular slit-like spaces are filled with spheroidal-shaped cells with round or oval nuclei which stain deeply with logwood and vary much in size, some being very considerable. The presence of these abnormal cells is especially noticeable in clefts amongst a thick band of dense fibrous tissue which borders on the cavity of the pelvis. The innermost portion of this dense tissue is occupied by a layer of loosely formed connective tissue of spindle and irregularly shaped cells closely resembling the structure of granulation tissue, and this projects into the cavity in the form of small polypoidal outgrowths. The adventitious growth in the kidney seems to be of a general infiltrating character that pervades the whole organ.

The liver, of which a portion only is shown, was of great size, and weighed 90½ oz. It was studded throughout and over both upper and lower surfaces by deposits of malignant growth, these being of a pale yellowish tint, round, in size from a pea to a small chestnut, mostly small. The gall-bladder was distended with bile, but contained no calculus. The appearance of the organ was typically that of secondary infection, and is undoubtedly secondary to that in the right kidney. The minute structure of the liver growths was of the same glandular nature, but the epithelial elements were much more fully represented, with a corresponding diminution in the amount of the fibrous stroma. Here necrosis was absent, and the new tissue cells stained uniformly and deeply. The liver-cells were pigmented and much atrophied; the intervening capillaries dilated.

There were no growths elsewhere in the body. The left kidney was enlarged, weighed 6 oz., but had a normal appearance. The remaining organs were healthy.

From a male lunatic 2690, aged 71, who had been an inmate of Colney Hatch Asylum for thirty-six years with chronic melancholia. He was in bed only a few weeks, although in feeble health for some years. The conditions referred to above were not suspected during life. No injury is known to have occurred.

Beyond the above and the two cases previously brought before this Society,[1] I have been able to find reference to but four other instances of primary malignant disease of the kidney in the *post-mortem* records of Colney Hatch Asylum, where over 26,000

[1] 'Path. Trans.,' 1893, p. 98, and 1897, p. 241.

patients have passed through the building since it was opened forty-six years ago. Three of these were males, making in all six out of seven cases as occurring in the male sex. The four unpublished cases were—

Male 1650, aged 51, chronic mania of twenty-four years' duration. Cancer of kidney with no secondary growths.

Male 8437, aged 27, mania with epilepsy of four months' duration. Right kidney occupied by mass of soft carcinomatous growth size of an orange, which extended from the pelvis outwards, forming a large projecting tumour. Secondary growths in liver, omentum, lumbar and mediastinal glands.

Male 9584, aged 53, mania of rather more than one month's duration. Extremity of left kidney infiltrated with soft sarcomatous growth; no secondary growths.

Female 7300, aged 44, recurrent mania of over six years' duration. Tumour of left kidney resembling carcinoma; no secondary growths.

March 1st, 1898.

---

13. *Undescended left testicle with complete twisting of the cord.* (*Card specimen.*)

By H. Littlewood.

Removed November, 1897, from a patient aged 27.

History.—The testicle has never descended into the scrotum, and was lying outside the canal, just above the middle of Poupart's ligament. For three months before the operation patient had suffered a great deal from pain, and had had two or three attacks of acute inflammation.

At the operation the testicle was found lying in the aponeurosis of the external oblique, the cord was completely twisted, and the organ covered by a semi-purulent inflammatory exudation.

February 15th, 1898.

---

14. *Multiple fibromata of right tunica vaginalis.* (*Card specimen.*)

By H. Littlewood.

Patient aged 37. He has noticed some enlargement for twenty years. It has gradually increased in size, but the increase has been more rapid during the past six months. He has a strong tuberculous family history, and the enlargement of the testicle was thought to be of a tuberculous nature by three medical men who examined him for life insurance. The insurance companies refused to consider his proposal; one company agreed to do so if he would have the testicle removed. Testicle removed on December 19th, 1897.

Description of specimen.—The tunica vaginalis has been laid open and stitched back. On opening it a small quantity of clear fluid escaped. The testicle, epididymis, and cord are healthy. The specimen shows several growths projecting into the cavity of the tunica vaginalis, all growing from the parietal layer, the larger masses springing from the lower part. There are also several small hard plates which form slight projections.

Microscopical examination. — Hard fibroma with calcifying points.

February 15*th*, 1898.

---

15. *A retro-peritoneal cyst, supposed to have originated in remains of the Wolffian body.*

By C. B. Lockwood.

The following case of retro-peritoneal cyst occurred in a healthy young woman aged 20, a domestic servant. Its presence had been noticed for two years; at first it was said to be as large as an orange, but it radually grew until at the time of its removal it might be compared to an ostrich egg or a small cocoa-nut. It was quite painless, and seemed to cause no trouble whatever; the urine

was normal. The nature of the tumour was not diagnosed, but speculations were in favour of some form of hydronephrosis of the left kidney. The tumour lay beneath the left linea semilunaris, with its lower limits about on a level with the umbilicus. It was freely moveable and could almost be pushed into the right side of the abdomen, and quite painless. No connection could be discovered between it and any of the pelvic organs. It moved slightly with the respiration, it felt very hard and tense, and did not fluctuate; the left colon could be felt on its outer side. An incision four and a half inches long through the left linea semilunaris determined that the tumour was a cyst, and that it lay behind that part of the peritoneum which goes by the name of descending mesocolon; the left colon lay to its outer side but had no connection with it, the transverse mesocolon was above, and the end of the duodenum or the beginning of the jejunum was adherent to its inner side. The left colic artery and vein coursed over its surface, whilst the inferior mesenteric vessels and the ovarian vessels lay behind to the inner side. After it had been removed the ureter which lay behind it also came into view. The cyst itself lay amongst the loose connective tissue behind the peritoneum; some of this had apparently become condensed upon its surface so as to form a capsule over it. The process of removal was comparatively easy. Care was required to avoid the large and important blood-vessels in its vicinity; these, however, were easily stripped off with the capsule. The cyst was removed entire, and was very dark coloured, probably owing to the nature of its contents; it had a single cavity filled with a chocolate-coloured semi-fluid mass, this consisted of fluid, a quantity of fibrin, altered blood pigments, and cholesterin.

The histological section shows that it is simply an altered blood-clot of some considerable standing; careful microscopical examination does not reveal the presence of either hooklets or daughter-cysts. It is important to note that during the removal of the cyst the pancreas was never seen, and although the lower part of the left kidney came into view it is clear that the cyst had no connection with it.

The histological examination of the cyst does not seem to throw much light upon its origin. Its walls were rather more than an eighth of an inch thick, and consisted of well-developed connective tissue and many small blood-vessels; its structure was densest

towards its interior and loosest towards its exterior; the connective-tissue fibres were interlaced in all directions; some of the cells were elongated and looked very like unstriped muscle; in places there was a good deal of small-cell infiltration, affording evidence of the existence of a chronic inflammatory process. Most of the small blood-vessels had thin walls, and some of them had burst and allowed blood to escape into the tissues of the cyst wall, likewise into its interior, which, it may be remembered, was full of old blood-clot. No glandular structure of any kind could be discovered. Inasmuch as there seems to be no evidence whatever to suppose that this cyst originated either from the pancreas, the intestines, or the kidney, it only remains to surmise whence it could have originated.

So far as can be ascertained from our works on anatomy and histology, there are no other structures behind this part of peritoneum at all likely to give rise to a cyst like that which I have just described. Nevertheless I wish to call attention to a point which offers at least a possible point of origin. In my Hunterian Lectures on "The Development and Transition of the Testes," delivered before the Royal College of Surgeons in 1887,[1] I printed a photograph of part of one of a series of sections of a human embryo of about the seventh week of intra-uterine life. My friend Mr. Cosens very kindly made a lantern slide of this microphotograph; on the right-hand side of the section the developing kidney with its glomeruli and tubules is clearly seen, and running down from it a considerable length of the ureter; on the left of the section is the pancreas, together with a large mesenteric vein. But the chief interest of the specimen rests in the supra-renal body, which at this period of intra-uterine life is of enormous size and lies above the kidney; its lower end, however, extends downwards in front of and to the inner side of the kidney, and is continuous along the course of the ureter with the upper end of the Wolffian body. There is no doubt whatever about this continuity, because, as is evident in the microphotograph, the glomeruli of the Wolffian body are continued some distance into the lower end of the supra-renal body. In the lectures to which I have just referred another human embryo was described which illustrated the same point.

[1] These lectures appeared in the 'Journal of Anatomy and Physiology,' and were published in a separate volume in London and Edinburgh in 1888. (See fig. 47, p. 78.)

These facts, taken in connection with the observations of Weldon, Janosik, and others, prove conclusively that whether the supra-renal body is developed from the front part of the Wolffian body or not, it is at all events, even to rather a late period of intra-uterine life, continuous with it. These observations also throw light upon the fact demonstrated by Dr. Rolleston, who has shown that even in an adult the supra-renal body is often prolonged into the hilum of the kidney, and that additamentary supra-renal bodies may even extend lower down.[1]

At this period of intra-uterine life the lower end of the Wolffian body is already becoming converted in the epididymis and other structures about the testis; in the female it is becoming the epi- or parovarium. Thus it is evident that betwixt the supra-renal body and the ovary or testicle there is, along the course of the ureter, a part of the Wolffian body which has hitherto been unaccounted for. How long this persists, or what may be its ultimate fate, is unknown; but these are points which seem to me to be well worthy of further investigation. Now it is so notorious that the part of the Wolffian body which is in relation with the ovary or testis is prone to give rise to various kinds of cysts, that it does not seem unreasonable to assume that the remaining part, viz. that which lies along the course of the ureter, may do likewise; and I venture to suggest this as the origin of the cyst which I have just described.

It is probable that retro-peritoneal cysts are of some rarity, but I cannot help thinking that many of the so-called pancreatic cysts may not have originated in the pancreas itself, but in the upper part of the Wolffian body, and in this connection it is not without significance to observe that in the microphotograph the upper part of the Wolffian body lies behind the developing pancreas and betwixt it and the kidney, and that it has an intimate relation with both these structures. I myself have only seen one other retro-peritoneal cyst like that which has just been described. Curiously enough it also occurred in a female, and was situated on the left side of the abdomen, and almost in exactly the same position. It differed, however, in a very important particular, instead of being unilocular it consisted of a series of thin-walled cysts surrounded by a common capsule; each of these cysts was

[1] My colleague Dr. Andrewes has recently found that some fatty tumours of the spermatic cord which I had removed were small adrenals.

filled with a rather thin, transparent fluid, slightly tinged with yellow. The whole of this compound cyst was rather larger than that which I removed myself, but its relations were almost identical. The operation was performed by my friend and colleague Mr. Bowlby; and as I assisted him at the operation, a clear idea of the relations of the cyst was acquired. The left kidney lay above and behind, the left colon lay to the outer side of the cyst, which as it grew forward had pushed its way through the great omentum, so that it came into view as soon as the abdomen was opened. The veins in the great omentum were exceedingly large, a circumstance which seems rather inexplicable. Some of the veins which ran over the capsule of the cyst were also of enormous size; the colic vessels, and I believe the inferior mesenteric vessels, ran upon the capsule of the cyst. The removal of the cyst was by no means difficult, and both Mr. Bowlby and myself were clearly of opinion that it had not originated in either the kidney or the pancreas; indeed, my note made immediately after the operation says that it lay below that organ. In this case the patient was a middle-aged female, and the tumour had been growing for three years. It was freely moveable.

March 1st, 1898.

---

16. *Ovarian cyst successfully removed from a child aged four months.*

By D'Arcy Power.

The cyst which I show you this evening, sir, was recently removed from a child aged 4 months, whose abdomen had been increasing in size for three weeks before she came under my care. I removed the cyst, the patient made an uneventful recovery and left the Victoria Hospital for Children within a fortnight of the ovariotomy. The clinical details of the case are published in the 'British Medical Journal,' 1898, vol. i, p. 617, and the cyst is preserved in the museum of St. Bartholomew's Hospital, No. 2904*i*.

The cyst contained 60 oz. of a clear serous fluid without any viscosity, and throwing down no deposit on standing. It appeared to be a thick-walled fibrous sac which had formed no adhesions, whose pedicle was formed by the broad ligament. Thirty-five millimetres of the left Fallopian tube with the fimbriated end remain attached to the lowest part of the cyst at the point where the pedicle was divided.

The cyst appears at first sight to be perfectly simple and unilocular, but a closer examination shows two or three small nodules in its substance situated in the middle of the cyst wall, and projecting equally inwards and outwards, and when the cyst is held up to the light innumerable small dots are seen studding it. The dots vary from a size which requires a lens to see them to the breadth of a very small pin's head. They are imperceptible to the touch, and appear to be grouped, for they are more numerous on the sides and in front than behind.

Microscopic sections made through one of the larger nodules show that the cyst wall is composed of ovarian stroma containing many minute Graafian vesicles. Each vesicle is itself undergoing a cystic change. The nodule is situated in the very centre of the cyst wall. It is oval and hollow, the lumen measuring three millimetres in its long diameter. It contains the remains of an albuminous fluid which has coagulated during the preparation of the specimen. This small cyst is lined by a layer of epithelium from three to five cells deep, the external layer being columnar and situated upon a basement membrane formed by a single layer of cells of the ovarian stroma which have arranged themselves end to end, being spindles. The intermediate layer of epithelial cells is round, the innermost layer is flattened. The cells of the intermediate and innermost layer are undergoing karyomitosis. The structure of the main cyst wall is externally a layer of young fibrous tissue, and internally condensed ovarian stroma. It has no epithelial lining.

The cyst is therefore truly ovarian, and is probably congenital. It is in reality multiple, though the huge size of the main cyst has masked the smaller ones. Like many ovarian cysts it is only the smaller cysts which present an epithelial lining, the larger ones being quite devoid of epithelial cells; nor is this to be wondered at, for the sides of the larger cyst have been soaking for some months in fluid, though the absence of epithelium may also be brought

forward as an argument in favour of its interfollicular origin. The epithelium lining the smaller cyst so closely resembles that found in the mature Graafian vesicle as to suggest irresistibly the idea that the cyst has developed from such a structure. The fact that the small Graafian vesicles found elsewhere in the specimen only show a single layer of epithelium is no objection to this supposition, for the cells lining the cyst are multiplying actively, and they would tend to assume the adult type.

Mr. Alban Doran showed a very similar specimen obtained from a child born at the seventh month. The record is published in the 'Transactions' of our Society,[1] and the figures there reproduced show that the structure of the tumour resembles very closely that which I now exhibit.

Dr. Aldibert[2] and Mr. Bland Sutton[3] have tabulated the cases of ovarian tumours in childhood. Of the sixty cases collected by Mr. Bland Sutton of oöphoritic tumours in infants and girls under fifteen, twenty-eight were dermoids, sixteen were sarcomata, and sixteen were cysts. The youngest child operated upon was a girl aged twenty months. The operation was performed with success by Dr. Kuester for the removal of a dermoid tumour. It is reported by Dr. Roemer.[4] Dr. C. S. Hoffman[5] removed an ovary from a child aged thirty-three months for a cystic sarcoma, but unfortunately death occurred.

The tender age of the patient, the ease of the operation, and the successful result are, I venture to think, noteworthy points in the case I have brought before you this evening.

March 15*th*, 1898.

[1] 'Trans. Path. Soc.,' vol. xl, 1889, p. 200.
[2] 'Ann. de Gynécologie,' vol. xxxix, p. 197.
[3] 'Surgical Diseases of the Ovaries and Fallopian Tubes,' p. 87.
[4] 'Deut. med. Woch.,' 1883, p. 762.
[5] 'American Journ. of Obstetrics,' vol. xxxvi, 1897, p. 331.

17. *Pyosalpinx and cystic condition of left ovary.* (*Card specimen.*)

By G. Brooksbank James.

Crissie D—, aged 37, admitted into Westminster Hospital with symptoms of acute general peritonitis. Laparotomy a few hours after. General peritonitis present at operation, and an abscess cavity bounded imperfectly by uterus, omentum, intestine, &c. Right tube found ruptured. Patient too bad to admit of removal of appendages, so washed out and tube inserted. Cavity of uterus 2¾ inches. Fallopian tubes much distended at extremities. Left tube is lost on the wall of a cyst filled with thin fluid containing cholesterin scales and representing the left ovary. Right tube fixed to right ovary, which appears fairly normal.

April 5th, 1898.

---

18. *Uterus bicornis.* (*Card specimen.*)

By Arthur Voelcker, M.D.

Both ovaries and Fallopian tubes are normal in size. The tubes are patent. The ovaries contain corpora lutea and fibrosa. The uterus is imperfectly developed; it is double, but the lower portions are undeveloped. A transverse section through the body of each, half an inch from the fundus, shows no central cavity. A fine bristle will not pass from the Fallopian tube to the uterus on either side. The vagina is absent.

The labia minora were small. There was a complete hymen with a small depression half an inch below the urethral orifice, into which a probe passed for one eighth of an inch. There were very few hairs in the pubic region, a few around both nipples.

From a single woman aged 29, who was admitted into Middlesex

Hospital under the care of Dr. Cayley, and who died from ulcerative colitis (see p. 114).

No menstrual history was obtained during life.

October 19*th*, 1897.

---

19. *Uterus unicorporeus et vagina duplex.*

By H. Morley Fletcher, M.D.

The vagina and uterus were obtained at the *post-mortem* examination of the body of a married woman aged 22, who died of septicæmia at St. Bartholomew's Hospital.

She had been married six months and had never borne children. The body of the uterus is single and normal. There are two complete cervical canals, uniting above at the internal os. There are two complete vaginæ, each with its external os. The septum separating the vaginæ is remarkably perfect. The two canals are equal in size, and the rugæ of both are equally well marked. They are separated by the septum throughout their entire length. The external genital organs were normal. The chief points of interest are that the uterus is single, with two cervical canals, and that the vaginæ are of equal size and quite laterally placed, with a well-formed septum extending their full length.

March 15*th*, 1898.

---

20. *Tumours of the uterus and appendages.*

By H. Morley Fletcher, M.D.

The specimen was taken from the body of a woman aged 71, who died suddenly from spontaneous rupture of the left ventricle. It was presented to the museum of St. Bartholomew's Hospital by Dr. H. B. Maingay.

The uterus is small, and has a small fibroid at the fundus. Attached to the anterior surface of the right broad ligament by a long slender peduncle is a large nodulated tumour. It is almost

entirely calcified. Calcareous degeneration is so far advanced that no microscopical determination of its character is possible. It is, however, probably a calcified fibroma which has become detached from the uterus, remaining attached by the peritoneal stalk alone, which has become elongated by dragging. There is another smaller tumour attached by a short thick pedicle to the upper and anterior surface of the left ovary. It is smooth and hard, and is partially calcified. Microscopical examination shows it to be a pure fibroma.

March 15*th*, 1898.

VI. DISEASES, ETC., OF THE ORGANS OF LOCOMOTION.

1. *A case of multiple spontaneous fractures.*

By Charles Spurrell.

Clara C—, aged 37, female, was admitted into the Poplar and Stepney Sick Asylum, March 6th, 1896, for a fracture of the right thigh.

Family history.—Two brothers and four sisters alive. One sister suffers from rheumatism and another from phthisis. Father and mother alive, both over seventy years old. All brothers and sisters have children.

Personal history.—Has always been unhealthy. Her menstruation has always been irregular, and there has been no period for last five months. Has been married eight years; no children; no miscarriages.

Present illness.—For last three or four years legs have swelled and ached. In December, 1894, walked about a ¾mile, and on returning she had great difficulty in walking, as her legs gave under her. She was confined to her bed off and on until August, 1895, since which date she has been bedridden. In February, 1896, she was shifting in bed and felt her right thigh snap. She was taken to a general hospital, where she was treated with a long Liston splint, and sent on to me on March 6th.

On admission.—A thin, sallow-looking woman, with a decidedly neurotic temperament. Light hair, long eyelashes, moderately dilated pupils, and pearly sclerotics.

Alimentary system. — Teeth carious. Tongue clean. Slight granular pharyngitis. Abdomen flatulent. Liver slightly enlarged. Bowels normal.

Respiratory system.—Normal.

Circulatory system.—Normal.

Nervous system.—Knee-jerks not examined. No sign of gross nervous lesion.

Osseous system.—Skull: depression over anterior fontanelle. Forehead rather prominent and bossy. Clavicles greatly curved

FIG. 7.

Photograph of a woman who had multiple spontaneous fractures. View of patient on May 8th, 1898.

Sternum slightly depressed. Xiphoid slightly bifid. Ribs beaded. Epiphyses slightly enlarged. Radii slightly curved. Pelvis not deformed. On pressing the ilia towards the middle line a considerable amount of elasticity is observed.

There is a transverse fracture at the junction of the upper and middle thirds of the right femur. There is some œdema and tenderness over the lower half of the right tibia.

The urine is alkaline, and contains a little pus.

From this date the patient continued to get more and more asthenic, and several further fractures occurred simply from moving her limbs.

On May 8th, 1897, the following was her condition :—Fractures: one of right femur, three of left femur, fifth metatarsal of left foot, both tibiæ and fibulæ, right radius and ulna. These had resulted in so much shortening that the measurement from the internal malleolus to the glabellum on the left side was 36¼ inches, and on the right 33¼ inches.

The head is decidedly bullet-shaped. Frontal eminences well marked. Anterior part of the temporal ridges exaggerated. Jaw is broad, angle obtuse, some difficulty in opening the mouth. Clavicles very curved. Sternum, a well-marked receding angle between the manubrium and gladiolus. Costo-chondral joints project considerably, and the angles of the ribs are also very prominent. Ribs are extremely flexible. Humeri curved outwards. Radius and ulna curved so as to follow the curve of the ribs, as in their habitual attitude of rest. Temperature has been normal all through.

No further fractures were noticed during life, but the asthenia increased, and the patient died on July 14th, 1897.

Post-mortem examination.—Osseous system : the bones were all extremely soft, and fractured as above. In addition six ribs on the right side were fractured near the angles (she never complained of any symptoms to point to this during life). The upper parts of the femora are practically composed of a pulpy mass, and the fibulæ being so soft and attenuated were with difficulty dissected out.

The skull was soft and thin. There was a marked thickening over the coronal suture. There were numerous small bosses on the vault of the cranium, especially on frontal bones, but there were no corresponding depressions on the inner surface.

The thyroid cartilage was somewhat flattened.

With the exception of the bladder and kidneys, which were inflamed, the viscera were normal.

Microscopic examination.—The bone appears to be absorbed by giant-cells, and its place taken by decalcified bone matrix and fibrous tissue. The medullary canal is slightly smaller than natural.

October 19th, 1897.

2. *A case of multiple spontaneous fractures.*

By Edgar Willett, M.B.

Mr. Edgar Willett showed specimens from a case of multiple spontaneous fractures. The history of the case had been already recorded in the 'Clinical Society's Transactions,' vol. xxix, p. 36, by Mr. Langton. By his kind permission the specimens were now shown for the first time; they consisted of portions of the right femur, of the lower half of the left femur, and of the left humerus. The bones had been sawn through longitudinally, and all of them showed old fractures. In neither of the femora were the bones united except by fibrous tissue. In the left femur the fracture took place at about the junction of the lower with the middle third of the bone; the fragments were in bad apposition, the posterior surface of the upper fragment being in a line with the anterior surface of the lower; they were, however, firmly held together. In the right femur the fracture took place in the middle third, and the fragments were in a similar but rather worse position than in the left leg, *i. e.* the upper was in front of and overlapped the lower fragment. In the left humerus the fracture took place at the junction of the upper and middle thirds, and the bone united in fairly good position; the cavity of the medullary canal had been restored.

The patient was a gentleman who at the time of his death in June, 1890, was 30 years of age. The following is his remarkable history.

In 1872, when eleven years of age, he fractured the upper part of his right humerus while throwing a cricket-ball: the bone united.

In 1874 he slipped and fell and fractured the left humerus: the bone united.

In November, 1878, whilst playing football, he fell and again fractured his right humerus, this time just above the condyles: the bone united.

FIG. 8.

Fig. 8.—Longitudinal section through right femur, showing considerable shortening from overlapping of the fragments which are united by fibrous tissue only.

In October, 1879, he severely sprained his right wrist, but broke no bones.

FIG. 9.

FIG. 10.

Fig. 9.—Longitudinal section through the lower half of the left femur, showing a similar condition of the fragments.

Fig. 10.—Longitudinal section through the left humerus: the fracture, which took place at about the junction of the upper and middle thirds, has been fairly well repaired, but the situation of the injury can still be seen.

From photographs by M. C. Coleman, Esq.

In June, 1880, he broke his right femur by a twist owing to his left leg slipping under him; the bone was broken as he stood; he

was treated for two months on a long splint which went up to his waist, but not up to the axilla, and subsequently for two months by a gutta-percha splint: the bone united partially but not firmly, and there was much eversion.

In January, 1881, he consulted a "bone-setter," who said "the knee was out," although the eversion was from the seat of fracture, and not from the knee; the limb was "manipulated" and the eversion corrected, but the patient was much worse afterwards. Shortly after this, slight movement was noticed at the seat of fracture, where there was much callus; the mobility increased, and with it the shortening increased also.

In June, 1883, he was treated by a surgeon; at that time there was extreme mobility between the fragments when the limb was at rest, but when the muscles were put into action the ununited fracture became fixed, and the patient stated that he could walk sixteen miles in a day at the rate of 3½ miles an hour; at this time there were three inches of shortening.

In February, 1884, while coming downstairs, his right heel slipped; he swung himself round, and grasping the banisters with both hands, the left femur broke above the condyles as he was standing; he did not fall. This united satisfactorily. Bending at the seat of this fracture was first noticed two years afterwards, and movement began three and a half years after the fracture.

In September, 1888, he noticed mobility at the seats of fracture of the right humerus, owing, he said, to excessive use. In April, 1889, enlargement in this region was first noticed, and gradually increased until November, 1889, when the right arm was removed at the shoulder-joint (see Specimen No. 447a, described below and shown at the same time). He recovered well from the operation, and was up in three weeks.

In February, 1890, an operation was performed for removal of some recurrent growth from the scar.

He died in June, 1890, from secondary deposits in the internal organs.

Microscopical examination of the material uniting the ends of the left femur showed it to be fibrous tissue only, and that it contained no sarcomatous elements.

The specimens are preserved in the museum of St. Bartholomew's Hospital, No. 759a.

The right arm, which was removed by Mr. Langton, is also a re-

markable specimen, consisting of the upper and lower ends of the humerus, in which an extensive spindle-celled sarcoma has entirely replaced both the shaft of the bone and the greater part of the muscles. When the limb was examined it was found that the whole of the bone, with the exception of its two articular surfaces covered with cartilage, had disappeared, and that the soft fibrous mass now seen had replaced it. Under the microscope this is seen to be a spindle-celled sarcoma. It is also preserved in the same museum (No. 447a).

October 19*th*, 1897.

---

3. *Fragilitas ossium.* (*Card specimen.*)

By Leonard G. Guthrie, M.D.

The left femur of a child aged between 2½ and 3 years. The walls of the bone shaft are thin, in some places they can easily be indented by finger-pressure. The medullary cavity is enlarged. Immediately below the lesser trochanter is a complete transverse fracture surrounded by a quantity of callus. There is little displacement of the fragments owing to the interlacing of the serrated ends of the fractured bone. Four similar fractures of other long bones were found after death. The fractures are believed to have been spontaneous.

The child was a congenital imbecile, and suffered from partial paralysis.

December 21*st*, 1897.

---

4. *Ununited fracture of the scapula.* (*Card specimen.*)

By Charles Powell White.

This is the scapula of a man who met with a railway accident which necessitated amputation at the shoulder-joint. Twelve months later, the stump being painful, the scapula was removed.

There is a fracture extending through the neck of the scapula, downwards just behind the axillary border and then across the lower angle. The piece of bone thus separated moves on the lower end of the fracture as on a hinge, and at the upper end is a well-marked false joint between the body and the part of the bone containing the glenoid cavity. This false joint is lined with firm, smooth fibrous tissue and had a fairly well-marked capsule. The glenoid cavity is quite obliterated.

May 17th, 1898.

---

5. *Empyema of the antrum in a child aged eight weeks.*

By D'Arcy Power.

The specimen I exhibit this evening is interesting on account of its rarity, rather than for any unusual pathological changes which it presents. It is the right superior maxilla of a child aged 8 weeks. The bone has undergone very extensive necrosis. Its malar surface is represented by two sequestra, which, being removed, expose the deciduous molars, themselves eroded. The orbital plate is almost completely destroyed, leaving only the more dense ring of bone forming the margin of the orbit. The whole of the facial surface is also destroyed, but both on the facial and malar surfaces the necrosis terminates abruptly at the junction of the superior maxilla with the premaxillary bone.

The child, miserably wasted, was admitted under my care into the Victoria Hospital for Children on July 29th, 1897, with an abscess discharging at the lower part of the right eyelid. The right side of the face was a little fuller than the left. The skin of the lower eyelid was red and hot, and a considerable quantity of pus could be expressed by pressure upon the cheek. Examination with a probe showed that there was an area of bare bone at the upper surface of the superior maxilla. A small quantity of pus was also exuding into the mouth from the alveolar border, but no definite opening in the gum could be found by probing; so that no dead bone was detected. The mother had been delivered by forceps, and immediately after birth both sides of the child's face

were seen to be greatly bruised, the injury being greater upon the right than upon the left side. In course of time the contusion almost subsided on the right side, and completely disappeared on the left.

When the child was about a month old he seemed to have some difficulty in closing his mouth, and he refused the bottle. The right cheek became red and inflamed, and a swelling appeared immediately below the right eye. The swelling became an abscess, and it was then opened by the medical man in attendance. The discharge of pus continued until the child was brought to the hospital four weeks later. I enlarged the opening in the lower eyelid, and after scraping away some granulation tissue I passed a probe into the superior maxilla. About half a drachm of very thick pus escaped, and some carious bone was felt. The dead bone was removed with a small scoop, and it was then found that a free passage had been established between the orbital plate and the alveolar border of the bone. A piece of fine india-rubber tubing was passed along this track, and for a few days the child appeared to be doing well. It lived thirteen days after the operation, and at the *post-mortem* examination a small abscess was found in the right lung with commencing adhesion of the pleura.

Cases of antral empyema in young children are extremely rare; indeed, I can only find one similar case recorded in detail. It occurred in the practice of Dr. Rees.[1] The patient was a child aged two weeks, in whom the abscess pointed upwards immediately below the eye, and downwards on the left side of the palate. In this case, as well as in another of which Dr. Rees gives no further account, the child was born with the face towards the pubes, and he attributes the abscess to the pressure exercised by the arch of the pubes on the face during parturition. Mr. Spencer Watson[2] in his work on 'Diseases of the Nose' also says that he has seen two cases of abscess of the antrum in very young children, in whom he had reason to suppose that the mischief was connected with injuries received during parturition.

A preliminary note of this specimen was published in the 'British Medical Journal,' 1897, vol. ii, p. 808, and after its appearance Dr. Douglas recorded a similar case[3] occurring in a child aged

[1] 'London Medical Gazette,' 1847, vol. iv, N.S., p. 860.

[2] 'Diseases of the Nose,' 1890, p. 164.

[3] 'Brit. Med. Journ.,' vol. i, 1898, p. 368.

three weeks which seems to have been unconnected with any injury at birth.

The specimen is preserved in the Museum of St. Bartholomew's Hospital, No. 1774 (*c*).

November 2nd, 1897.

---

6. *Sarcoma of clavicle (left).* (*Card specimen.*)

By H. Littlewood.

The whole clavicle was removed on October 25th, 1897. Patient left the infirmary on November 13th, wound having quite healed.

History.—Man aged 33. In April, 1897, he sprained his left shoulder, and after that had great pain about the left collar-bone. A swelling was first noticed at the beginning of August, 1897. Seven weeks before the operation the growth appeared about the same size as at the time of removal. During this time patient was taking large doses of iodide of potassium.

The growth involves the outer half of the clavicle, and consists mainly of round cells.

February 15th, 1898.

---

7. *Tumour of scapula—squamous epithelioma.* (*Card specimen.*)

By H. Littlewood.

Scapula removed on August 16th, 1897. Recurrent growth in middle of flap removed December 13th, 1897. No return since then. The growth involves the greater part of the bone and many of the attached muscles.

Microscopical examination.—Squamous epithelioma.

Patient dates the commencement of the growth to a strain of the shoulder twelve months before admission to the infirmary. There is no evidence anywhere of a primary growth.

February 15th, 1898.

[illegible]

DESCRIPTION OF PLATE V.

Illustrating Mr. Robert Jones' case of "Macrodactyly due to Diffuse Lipoma." (Page 203.)

The skiagraph shows the hypertrophy of the first and second toes.

8. *Macrodactyly due to diffuse lipoma.*

By Robert Jones (per D'Arcy Power). [With Plate V.]

The specimen was taken from a boy aged 13, who was born with an enlargement of the first and second toes. The length of the foot was 12 inches, the circumference of the instep 11½ inches; the length of the right big toe 4¼ inches, its circumference 6¾ inches. The second toe measured 3 inches in length and 5 inches in circumference. There was a little movement in the toes, but latterly a good deal of pain when he attempted to walk.

The macrodactyly occurred sporadically in the family. It was unilateral, and did not affect all the digits. The deformity was congenital.

The X-ray photograph (Plate V) shows the bones of the first and second toes to be very much hypertrophied, their enlargement being in direct proportion to the thickening of the soft structures covering them. There was a certain degree of hallux valgus, and all the toes are pushed outwards.

A microscopical examination of the hypertrophied tissue shows that it has the characters of a diffuse lipoma.

Mr. Robert Jones showed a similar specimen before the Society in 1895 (see 'Path. Soc. Trans.,' vol. xlvii, p. 252).

The specimen and cast are preserved in the Museum of St. Bartholomew's Hospital.

	Right. inches.		Left. inches.
Circumference of—			
Thigh, below groin	19½	...	18½
„ above knee	15	...	14½
Leg, below knee	13	...	12¾
„ above ankle	8¾	...	8¼
Instep	10¾	...	9½
Great toe	6¾	...	—
Length of—			
Ant. sup. sp. to int. mall.	35	...	34
Femur	19½	...	19
Tibia	15½	...	15
Great toe, outside	2¾	...	1¾
„ inside from met.-phal. joint	5½	...	3
Foot	12	...	10

Small toes larger on sound than on affected foot.

March 1st, 1898.

VII. DISEASES, ETC., OF THE DUCTLESS GLANDS.

1. *Pathological report on a case of acromegaly, with an analysis of the results of forty-nine post-mortem examinations on cases of acromegaly.*

By Percy Furnivall.

[With Plates IV, fig. 2; VII, figs. 1 and 2; IX, fig. 1.]

There have been so few *post-mortem* examinations made on cases of acromegaly that it does not require any excuse for bringing the following case to your notice.

The man was an in-patient at St. Bartholomew's Hospital from October 24th until November 6th, 1894, under the care of Mr. Harrison Cripps. One month after the patient's discharge from the hospital, *i. e.* on December 4th, 1894, he was knocked down and killed by a railway engine. Assisted by Dr. Meacher, I made the *post-mortem* examination two days later.

Mr. Harrison Cripps has most kindly allowed me to make the following abstract of the notes taken while the patient was under his care at St. Bartholomew's Hospital.[1]

W. P—, aged 58, a commissionaire, admitted complaining of weakness, nervousness, and enlargement of feet, hands, and lower jaw. Patient dates the commencement of his symptoms from October, 1893. He says that since that time his hands, feet, and lower jaw have got markedly bigger, that he has suffered from numbness, weakness, and trembling of his hands, also that he has great difficulty in writing and in buttoning his clothes. A

[1] See 'St. Bartholomew's Hospital Male Surgical Register,' vol. ii (1894), No. 2998.

photograph taken in 1875, nineteen years before, shows that at that time his lower jaw was large and massive, though not so markedly as it is at the present time.

Previous history.—He served in the Rifles for twenty-seven years, joining the army when eighteen years of age. He has never served out of England, except for a short time in Canada. He has never been exposed to any hardship, has always had plenty of good food, has always been healthy, and has never suffered from rheumatism or any serious illness.

Family history.—No relations have had any complaint of this kind, so far as he knows. His wife confirms this statement. No tumours; no slowness of movement; no phthisis, gout, or rheumatism.

Present condition (October 24th, 1894).—Patient is a pallid, melancholy-looking man, about 5 feet 9 or 10 inches in height; stooping slightly; moving slowly and deliberately. His speech is rather "thick" and hesitating, probably due to the large size of his tongue for the most part. The most striking things about him are the great length of his face, especially the large, massive, and protruding lower jaw, and the size of his hands and feet. He has short, scanty, coarse, grey hair; his skin is thick, and somewhat coarse and dry to the touch. His appetite is good. He suffers from a chronic cough and constipation, and has had some little prolapse of the mucous membrane of the rectum for a long time. The eyes are deep set, the frontal bone just above the orbits being prominent. The eyelids are not thickened; the lower lid and tissues around are a little relaxed; the conjunctivæ rather watery. Vision is good; he has used spectacles for reading for the last three years. Fields of vision were not taken, but there was no marked hemianopia. Pupils small, equal, reacting well to light and accommodation.

The forehead is natural, but prominent above the orbits. The enlargement of the face is chiefly from below the eyes. The nose is somewhat long and thick. The ears rather large. The palate is very highly arched. The tongue is very large, rough, and covered with a whitish fur. The lower lip is large, thick, and bulging. The lower jaw is greatly enlarged both in length and depth; it protrudes beyond the upper jaw so much that it causes some difficulty in masticating food.

Measurements.—Circumference of the head at the level of the

external occipital tuberosity and the superciliary ridges $23\frac{3}{4}$ inches. Distance from the root of the nose to the external occipital tuberosity, over the vertex, $14\frac{1}{2}$ inches. Distance from the upper portion of the zygoma to the angle of the jaw $3\frac{1}{2}$ inches. Round the front of the lower jaw, from angle to angle, $9\frac{1}{2}$ inches. The increase in size of the lower jaw is almost entirely bony.

The neck is short; there is some cervico-dorsal kyphosis. The cartilages of the larynx are very distinctly felt. The thyroid gland is not well marked.

The chest is barrel-shaped; no heart's dulness; the heart-sounds are clear but weak, the breath-sounds harsh. Pulse 73, full volume, tension moderate. Nothing abnormal felt in the abdomen.

Urine normal. *Temperature* constantly subnormal, varying from 96° to 98° during the thirteen days he was in the hospital.

Limbs.—Upper: the hands and forearms are markedly broader and thicker than normal, but apparently not lengthened. The hands show this change far more than the wrists or forearms. The thickening seems to be partly bony and partly due to increase in the soft parts. All the joints move easily and painlessly, but the patient can only move them slowly. There is no paræsthesia in either hand.

Measurements.—Breadth at heads of metacarpal bones $4\frac{1}{4}$ inches. Length from tip to head of metacarpal bone: index $4\frac{3}{4}$ inches, middle $4\frac{7}{8}$ inches, ring $4\frac{3}{4}$ inches, little $3\frac{7}{8}$ inches. Circumference of first phalanx: index $3\frac{1}{2}$ inches, middle 3 inches, ring $2\frac{3}{4}$ inches, little $2\frac{1}{2}$ inches. Both hands are the same.

Lower: the feet are also markedly enlarged and clumsy-looking, the enlargement being specially marked in the toes. The lower ends of the tibiæ and fibulæ are also apparently thickened.

Post-mortem examination.—The body was very much damaged by the railway engine which caused the patient's death, the left arm and leg hanging on by skin only, and many of the viscera were ruptured.

The *external appearances* I need not describe again.

Head.—The skull-cap was thick and heavy, the frontal sinuses very large. The dura mater separated easily from the bones. The sella turcica was deep and wide, measuring 1 inch by $\frac{7}{8}$ inch. The olivary and middle clinoid processes being entirely, and the posterior clinoid partially absorbed. The pituitary body was con-

verted into a cyst containing a brownish semi-fluid substance, with some little solid matter in the walls of the cyst. The optic chiasma was flattened. The cranial nerves were natural. The brain was natural; no increase of cerebro-spinal fluid.

The skull-cap, lower jaw, and the pituitary cyst were preserved, and will be described more fully later on.

Neck.—The thyroid gland was slightly enlarged, otherwise natural. The larynx was natural. The cervical sympathetic ganglia were natural. There was well-marked cervico-dorsal kyphosis.

Chest.—The thorax was barrel-shaped, the sternum large and massive. No trace of the thymus gland was seen. *Lungs* showed well-marked emphysema; there were old adhesions at the right apex and left base. *Heart:* the right side was slightly hypertrophied; the valves were natural. The trachea, bronchi, great vessels, and thoracic sympathetic ganglia were natural.

The hyoid bone, clavicle, a rib and vertebra were preserved, and will be described more fully later on.

Abdomen.—Peritoneum natural. The stomach was dilated. There were some old adhesions about the cæcum and vermiform appendix. The rest of the alimentary canal was natural.

The liver, spleen, and pancreas were natural.

Kidneys: the capsules did not strip easily, some slight interstitial fibrosis being present. The supra-renal capsules, the abdominal sympathetic ganglia, the bladder and prostate, were natural. The penis and testicles were of normal size.

Limbs.—Upper: the joints were natural, fingers as broad at the tips as at the base, and so looked "sausage-shaped;" the nails were short, wide, and thick.

Lower: the legs were quite straight, the condyles of the femora and the patellæ were of normal size. The feet were large and thick; the toes flat, broad, and thick; the nails short, wide, and thick. The joints were natural.

Specimens preserved.—The *skull-cap* is thick, dense, and heavy. There is some heaping up of bone along the lines of the sutures; this change is better marked on the outer surface than on the inner. The lambdoid suture is synostosed. Along the line of the coronal suture the frontal and parietal bones have lost their serrations, and a wavy line marks the position of the suture. There is no distinction between the compact and cancellous tissue of the

bones forming the skull-cap; this change is most marked in the frontal bone. There also appears to have been some deposit of subperiosteal new bone on its outer surface. A boss of bone is seen on the upper part of the right temporal ridge. The frontal eminences are not marked. The frontal sinuses are enlarged. The grooves for the middle meningeal artery are deeper than they usually are.

The *inferior maxilla* (Plate IX, fig. 1) differs in a most striking manner from a normal bone. The body is massive and very deep from above downwards; its lower border projects beyond the alveolar process, forming a segment of a considerably larger circle. The angle is very obtuse, the rami being almost in a straight line with the body of the bone.

The muscular ridges and prominences are very well marked; the foramina are large. The sigmoid notches are shallow, and the anterior borders of the coronoid processes are curved inwards in an unusual manner. The condyles are large. The teeth, with the exception of the right second molar, have been lost in the process of maceration.

Cast of the jaws.—The lower jaw projected at least half an inch all the way round beyond the upper.

The hard palate is deep and narrow; its high-pitched sides slope straight down to the thickened alveolar process.

The *hyoid bone* is natural.

The left clavicle is large; its curves are rather less marked than usual, but the grooves and ridges for muscles and ligaments are abnormally developed.

The lower ends of the *radius and ulna* are enlarged by a heaping up of bone at the margins of the articular surfaces, but the articular surfaces are natural; the ridges and styloid processes are well marked.

The individual bones of the *carpus* are large, especially the palmar surface of the trapezoid. The ridge on the trapezium is larger than usual.

The *metacarpal bones* show little change; the heads of the bones and the ridges on the shafts are large.

The *phalanges* are large, the ridges for the vaginal ligaments being very well marked. In the terminal phalanges, pointed excrescences of new bone have evidently been deposited at their extremities. The effect of this is that the bones seem to taper very

little from the bases of the metacarpal bones to the ends of the third phalanges.

The *left fifth rib* is massive. All the ridges for the attachment of muscles and ligaments are unusually developed.

The transverse process of the *sixth dorsal vertebra* shows the same change; the body and spinous process are unchanged.

A piece of the *right ilium*, including the anterior superior spine and part of the crest, shows that the crest is broadened, owing to the development of the ridges for muscles.

The *lower ends of the left tibia and fibula* are somewhat enlarged, and the prominences and ridges are well marked. At the inferior tibio-fibular articulation the margins of the tibia overlap the fibula more than normally, owing to the formation of new bone. The articulations are natural.

There is no obvious change in the *tarsal bones*.

The shafts of the second, third, fourth, and fifth *metatarsal bones* are thinned near their heads; and the heads themselves are somewhat twisted outwards.

The shafts of the *first phalanges* are thinned; their extremities are large. The second and third phalanges have new bone heaped up at their extremities. These tuberous and pointed excrescences of bone are specially well seen in the terminal phalanx of the great toe.

Casts of the left hand and foot.—These were taken after death; they show the typical changes of acromegaly—sausage-shaped digits, &c.

The changes in the bones would seem to indicate some chronic periosteal irritation; the deposit of new bone has taken place at the margins of the articulations, especially the wrist and ankle, also at the points of attachment of muscles and ligaments, but the joints themselves are not affected. The changes in the lower jaw cannot be due to the enlargement of the tongue, for in many cases the jaw enlarges before the tongue does.

Microscopical sections of the tissues of the case.—1. *A section of the pituitary tumour* shows that it consists of an enlarged anterior lobe, in which the middle part of the central zone has broken down, leaving a cystic cavity (Plate VII, fig. 1). The solid gland acini can be seen in the wall of the cavity, and there is perhaps some increase in the fibrous tissue. Nearing the inner edge the cells are de-

generating, losing their structure and becoming detached from one another (Plate IV, fig. 2). In the boundary zone, as well as in the central zone, there are several small cysts lined with definite flattened cells; also there are several cavities filled with a colloid-like substance. Outside the boundary zone there is a largish cavity lined with flattened cubical cells. This is probably one of the cavities found at the junction of the two lobes, described by Weichselbaum ('Virchow's Arch.,' Bd. lxxv, 1879).

I should infer from the section that the pituitary body had been the seat of an adenomatous tumour, or a simple hypertrophy, affecting the central zone of the anterior lobe, and that this had degenerated and become cystic in its central part.

2. *A section of the thyroid gland.*—In parts of the section many of the follicles, instead of being occupied by colloid matter, are filled with cells (Plate VII, fig. 2); in other parts the follicles are enlarged into cysts; in others, again, the follicular structure has entirely disappeared, recalling the appearances described by Edmunds ('Trans. Path. Soc.,' 1895, p. 224) in cases of exophthalmic goitre.

3. *A section of the kidney.*—Shows some interstitial fibrosis; in places fibrous Malpighian tufts can be seen. There is also some degeneration of the epithelial elements.

4. *A section of the liver.*—Normal.

5. *A section of the spleen.*—Normal.

6. *A section of the pancreas.*—Normal.

Dr. M. Sternberg in his admirable monograph on 'Acromegaly' (Vienna, 1897) has collected forty-seven cases with *post-mortem* examinations. I have collected seven more cases, but have been unable to verify all Dr. Sternberg's references.

I have made a table comparing the condition of the structures generally considered to have most importance in the pathology of the disease, namely, the pituitary body, the thyroid, and thymus glands, and the sympathetic nerve ganglia. I have also noted anything of special interest that has been recorded about individual cases. For table see Appendix, p. 218.

If we analyse these forty-nine cases, we find that the pituitary body was affected in all of them.

DESCRIPTION OF PLATE VII.

Illustrating Mr. Percy Furnivall's Report on a case of Acromegaly. (Page 204.)

FIG. 1.—Section of the anterior lobe of the pituitary body, showing that the cells and connective tissues of the central zone have degenerated, forming a cyst. This is seen as a space dividing the upper and lower halves of the section. Small cysts, filled with colloid matter, can be seen in both the central and boundary zones.

FIG. 2.—Section of the thyroid gland, showing that in places the vesicles are enlarged into cysts, in others the vesicles are filled with cells.





Fig. 2

[illegible]



Fig. 1.

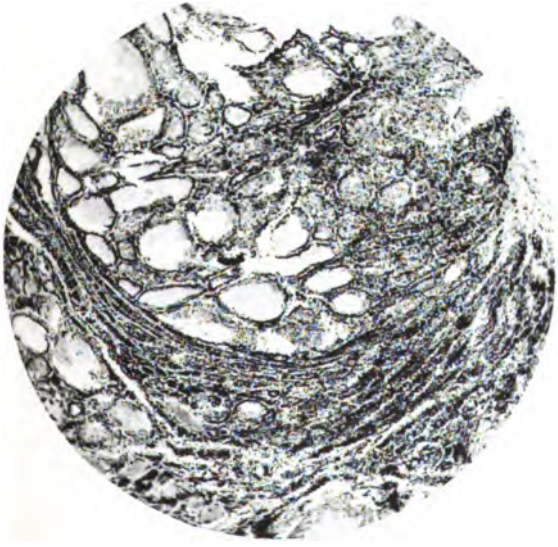

Fig. 2.

The *Pituitary body* was observed in 49 cases.

	Cases.
(a) *Enlarged.*	
Hypertrophy	7
„ vascular	2
„ of connective tissue with atrophy of glandular follicles	1
„ of posterior lobe, and foci of colloid degeneration	1
„ of anterior lobe, and small cysts in posterior lobe	1
Colloid degeneration	1
„ „ with hæmorrhages	1
Adenoma	6
„ with cystic degeneration	2
Sarcoma	11
„ or lymphadenoma (?)	1
„ spindle-celled, with psammomatous degeneration	1
Glioma	1
Neuro-gliomic sarcoma	1
Glioma or sarcoma (?)	1
Tumours, character not specified	3
„ containing liquid	2
„ containing pulpy matter	2
„ like cerebral substance	1
„ large round-celled	1
(b) *Not enlarged.*	
Softened adenoma	1
Necrosis with softening	1
	49

The *thyroid gland* was observed in 29 cases.

Normal	5
Hypertrophy	13
„ with a thoracic thyroid gland weighing 36·5 grms.	1
„ with degeneration	3
Colloid degeneration	3
Cystic degeneration	1
"Chalk-like" deposits	1
Atrophy	1
„ with increased connective tissue	1
	29

The *thymus gland* was observed in 19 cases.

Absent in	7
Hypertrophy	3
Persistent	8
„ left lobe hypertrophied in	1
	19

In many other cases the condition of the lungs and other thoracic viscera has been recorded, but the thymus gland is not mentioned. It is probable that in most of these cases the thymus was not persistent, or its condition would have been noticed.

The *sympathetic ganglia* were observed in 13 cases.

	Cases.
Normal in	6
Hypertrophy	6
„ with degeneration	1
	13

In the central nervous system—

The brain was "enlarged" in	2
The spinal cord was "hypertrophied" in	1
Degeneration in the spinal cord in	4
„ in Goll's column specially in	2
„ in Burdach's column in	1
„ of the peripheral nerves in	1

Muscular system.—Degeneration of the muscular fibres in 5 cases.

Osseous system.—Abnormal hyperæmia of the bone medulla in 2 cases.

Lymphatic system.—

	Cases.
Hyperplasia of the lymph glands, and spleen pulp and follicles	1
Enlargement of the spleen	3

Abdominal viscera.—Enlargement of all the abdominal viscera has been noticed in 4 cases.

It would seem from these observations that the pituitary body is always altered in cases of acromegaly. The changes in structure differ widely, but they are always the same changes that commonly occur in cases of lesion of the pituitary body not clinically associated with acromegaly.

What relationship there is between pituitary, thyroid, and thymus diseases, and changes in the nerve-centres, peripheral nerves, and their muscles, future observation and experiment must decide.

I have compiled the following summary of the pathological anatomy of the disease chiefly from Dr. Sternberg's monograph. The descriptions of the changes that take place in acromegaly vary greatly, each author describing his own case as being typical.

Doubtless this is due to the fact that cases may die and be examined at an early or late stage of the disease.

The *bones* are usually symmetrically affected, but the change in one of a pair of bones may be more marked than in the other.

In all the bones the muscular and ligamentous ridges and grooves are enlarged, the normal bony processes are exaggerated, and the foramina for the nutrient vessels are enlarged.

Less commonly flattened exostoses are found on the bones of the base of the skull, bodies of vertebræ, pelvis, and thorax, still more rarely on the long bones.

In true acromegaly stalactitic exostoses are never found in large numbers on the normally smooth parts of bone.

The *skull* is enlarged, its walls thick and heavy, especially in cases of long duration. The air-cells are enlarged; their walls may be thickened or thinned. In the vault of the skull the sutures are often early obliterated. The zygomatic arches are spread out, much curved and thickened. The alveolar processes are hypertrophied. The great overgrowth of the lower jaw and the obtuseness of the angle in long-standing cases may make mastication almost impossible.

The pituitary fossa may be greatly enlarged, and from pressure-atrophy the clinoid processes and the base of the fossa may be destroyed, the sphenoidal cells opened up, and even the body of the sphenoid destroyed, so that the pituitary body may be only covered by pharyngeal mucous membrane (Hausemann).

The *vertebral column* always shows cervico-dorsal kyphosis, with a compensating lumbar lordosis. This is due to atrophy of the anterior parts of the bodies of the vertebræ. The anterior common ligament may be ossified, and the vertebræ ankylosed.

The *ribs* are thick, spread out, and enlarged.

The *sternum*, especially the manubrium, is widened and more massive.

The *rib cartilages* often ossify extensively. The chondro-costal junction may enlarge, and so form a sort of rickety rosary.

The *thorax* is thus altered in a curious manner; it is roomy as a whole, the sides flattened, the antero-posterior diameter increased, and the sternum tilted obliquely forwards.

Of the *long bones* the clavicle shows specially well the enlargement of all the normal ridges, and is very wide and massive.

The *hand and foot bones* are not very noticeably altered. The

phalanges often have stalactitic exostoses on them, but these are also frequently found in normal hands, and cannot be said to be typical of acromegaly.

Marie divides acromegalic hands into two types:

1. The *long type*, where the whole of the bones of the hand are lengthened and enlarged.

2. The *massive or "giant" type*, where the bones of the hand are not lengthened, but are very thick and massive.

Structure of the bones.—The descriptions of the changes in structure vary even more than those of the changes in shape. Often different bones in the same skeleton show different changes.

Commonly the periosteal connective-tissue fibres are thickened, the nutrient vessels enlarged, and layers of periosteal new bone are deposited. The rough porous look of the bones is due to this change (Thompson, Brigidi, Boltz).

The compact bone may be thickened or thinned. The medullary spaces are enlarged, the trabeculæ thickened, and in Broca's case parts of the pelvis and the calcaneum showed well-marked osteoporosis. A specimen added this year, 1898, to the Museum of the Royal College of Surgeons, London, shows this change in the alveolar process of the upper jaw. The medulla may be highly vascular (Mossé and Daunic, and Hunter).

Changes in cartilage.—The cells are enlarged and proliferating. Lines of ossification are often seen. Fibrillation sometimes occurs. Changes like those seen in arthritis deformans are occasionally seen.

Changes in the skin.—The dermis and the subcutaneous tissues are thickened, occasionally two or three times thicker than normal. The cutaneous vessels, glands, and papillæ are enlarged, the pigment increased. The thickening of the cutaneous nerves begins in the outer sheaths and endoneuric septa.

Changes in muscles.—The muscle-fibres show all forms of degeneration and atrophy, with well-marked sclerosis of the interstitial tissue. Simple wasting may occur.

Viscera.—A single organ may be hypertrophied, *i. e.* splanchnomegaly; except in the case of hypertrophy of the mamma and in congenital enlargements, *e. g.* of the brain, this is an extremely rare condition. As it is frequently found in acromegaly it must be taken as one of the signs of the disease. This condition is found in the central nervous system, eyeball, alimentary canal, liver, and kidneys.

The *arteries* are thickened and dilated, all the coats being affected by fibrosis, the intima being most affected. These changes begin in the aorta and pulmonary arteries and spread to the smaller vessels. The dilatation is probably secondary to the degeneration of the vessel-wall, although Klebs maintains the contrary.

The *heart* is generally hypertrophied and dilated, which is probably due to the changes in the vessels.

The *lymphatic structures* are often enlarged, especially the spleen.

The *thymus* may be enlarged or degenerate as usual, but as Mossé and Dannic point out, "one cannot say anatomically whether one is dealing with a persistent thymus or a reviving organ."

Nervous system.—Degeneration and fibrosis have been found in the spinal ganglia, spinal cord, and the cranial and peripheral nerves, also in the sympathetic ganglia and nerves. The brain and spinal cord have been found to be enlarged.

The *pituitary body* seems always to be diseased. Doubtless some confusion has arisen about the various changes found, because it is difficult to give an opinion on a section of it.

Adenomata form from the growth of new columns of cells. Often the central cells die and the connective tissue softens, and a cyst forms. This growth is from the anterior lobe; the posterior lobe seems to disappear.

Sarcoma of the pituitary is difficult to diagnose.

Lymphatic cells invading the normal cells of the gland are described by Brigidi, Claus and Van de Stricht, Comini, Sigurini and Caporiacco, and Henrot.

Connective-tissue sclerosis and degeneration have also been described.

Sense-organs.—The *nose* increases in size and the mucous membrane hypertrophies. The cartilages of the *larynx* and *epiglottis* show proliferation of the cartilage cells, with lines and patches of ossification. Their mucous membrane is thickened, making the larynx look like a case of pachydermatous laryngitis.

Alimentary canal.—The *lips* are large and thick. The *tongue* is often greatly enlarged. This is due partly to thickening of the mucous membrane and partly to an increase of the intermuscular connective tissue. The tongue muscles are usually degenerating.

The *gingival mucous membrane* is thickened.

The *pharyngeal lymphatic* circle is hypertrophic.

The *stomach* is sometimes very large (Tarruffi, Cunningham, and Brigidi's cases); this is possibly mechanical.

The *intestines* in Cunningham's case were twice the usual length, and abnormally dilated, *i. e.* splanchnomegaly.

The *liver* is often large and engorged.

The *pancreas* generally normal; diabetes in Hausemann's, Dalmagne's, and Pineles' cases.

The *kidneys* are often large, and show signs of chronic nephritis. This is probably due to heart and vessel changes.

The *genital organs* are often large. It is not known whether this is due to changes in the skin only, or to changes in the erectile tissue as well.

Dr. M. Sternberg divides cases of acromegaly into three types:

(1) The benign type, lasting as long as fifty years.

(2) The ordinary chronic type, with a duration of from eight to thirty years.

(3) The acute or malignant form, lasting from three to four years.

Of this latter variety there are six cases on record. In all of these there was a true sarcoma of the pituitary body found, and the disease ran a rapid and similar clinical course.

That it is possible for sarcoma of the pituitary body to occur without causing acromegaly is well shown by a case recorded by Woollcombe ('Brit. Med. Journ.,' June 23rd, 1894, p. 1351), where after death a tumour the size of a hen's egg was found occupying the sella turcica. Mr. Butlin pronounced the microscopical appearances of the growth to be those of "Virchow's psammoma."

Several theories have been put forward to explain the actual causation of acromegaly, but none of them are satisfactory.

With regard to treatment, this has been almost uniformly unsatisfactory; and it gives us no clue as to the pathology of the disease. Pituitary and thyroid extracts have been tried in many cases.

Brown-Séquard ('Progrés Med.,' 1893) recommended the extracts of the spleen and thyroid glands, with bone-marrow.

Symptomatic treatment with antipyrin, ergotin, and induction currents (Mosler), arsenic, phosphorus (Verstraeten), mercury, iodide of potassium, &c., has been sometimes successful.

Trephining to relieve pressure has given relief in Caton and

Paul's case, and in Thomas's case ('Brit. Med. Journ.,' April 11th, 1896, p. 909).

It cannot be said that the researches of von Kupffer or Scott ('Wiedersheim's der Bau der Menschen,' 1893) or Andriezen ('Brit. Med. Journ.,' January 13th, 1894, p. 54) on the morphology of the pituitary body; or those of Horsley (1886), Gley, Vassale and Sacchi ('Centralb. f. allg. Path.,' May, 1894), or Schäfer ('Brit. Med. Journ.,' 1895, vol. ii, p. 341) on the functions of the pituitary body; or Krause ('Handbuch der Anatomie, 1876), Lothringen ('Arch. f. mik. Anat.,' Bd. xviii), Stieda (Inaug. Dis., Konigsberg, 1889), Schöneman ('Virchow's Arch.,' Bd. cxxix), Müller ('Jenasche Zeitschrift,' Bd. vi, 1871), Berkley ('Johns Hopkins Hosp. Reports,' vol. iv, p. 126) on the histology of the pituitary body, throw much light on the pathology of acromegaly. There is nothing certain about the connection of the pituitary body or the thyroid gland with the disease.

The pathogenetic *rôle*, if any, of the thymus gland, and of the lymphatic structures generally, is also quite uncertain. In fact we know little or nothing about the real ætiology and pathology of the disease.

Most of the *post-mortem* examinations have been very incomplete; and many more thorough observations of clinical histories, followed by complete examinations of all the tissues and organs after death, will be necessary before we can arrive at a clearer understanding of this most interesting and complicated disease.

February 1st, 1898.

APPENDIX.—*Table of 49 Post-mortem*

No.	Case of	Where published.	Pituitary body.
1	Verga	Rendiconti dell' Inst. Lombardo, 1864, iii	Tumour
2	Brigidi	Atti del. Soc. Medicofisica fiorentina, 1877, Aug.	Vascular hypertrophy
3	Henrot	Notes de Clinique Médicale, Reims, 1877, 1882	Adenoma (?)
4	Fritsche and Klebs	Beit. zur Path. des Riesenvuchses, Leipzig, 1884	Hypertrophy; probably a softened adenoma
5	Lancereaux	Traité d'Anatomie Path., Paris, 1888, t. iii, 1, p. 29	Tumour containing liquid
6	Strümfell	München. med. Wochenschrift, 1889, p. 571	Sarcoma
7	Thomson	Journ. of Anat. and Phys., 1890, xxiv, p. 475	Hypertrophy
8	Gauthier	Progrés Medical, 1890, p. 409, and 1892, p. 4	Tumour resembling cerebral substance, probably simple hypertrophy
9	Bury	Brit. Med. Journ., 1891, i, p. 1178.	Glioma
10	Marie and Marinesco	Arch. de Méd. Expér. et d'Anat. Path., 1891, iv	Adenoma
11	Duchesnau	Acromégalie, &c., Thèse de Lyon, 1891, and Contrib. à l'étude anat. et clin. de l'Acromegalie, Paris, 1892	Tumour containing pulpy matter
12	Holsti	Zeitschrift f. Klin. Medicin, 1892, xx, s. 298	Tumour, probably an adenoma with fibrosis
13	Cepeda	Revista balear. de sciencias medicas, 1892	Tumour, probably simple hypertrophy
14	Fratnich	Allgem. Wiener med. Zeitung, 1892, p. 405, and 1893, p. 351	Colloid degeneration with hæmorrhages
15	Dana	Journ. of Nerv. and Ment. Diseases, 1893, p. 725	Tumour containing liquid blood serum, ? colloid
16	Squance	Brit. Med. Journ., 1893, ii, p. 993	Hypertrophy; the canal communicating with the 3rd ventricle was patent
17	Caton and Paul	Ibid., p. 1421	Sarcoma
18	Wolf	Ziegler's Beiträge, 1893	Sarcoma; hyaline degeneration of vessels (? cylindroma)
19	Claus and Van de Stricht	Annales et Bulletin de la Soc. de Méd. de Gand, 1893, Nos. 71, 72	Necrosis with softening (not enlarged)
20	Linsmayer	Wiener klin. Wochenschrift, 1894, p. 294	Softened adenoma (not enlarged)
21	Lathuray	Lyon. Méd., 1893, p. 443, No. 31	Very large and softened
22	Arnold (Case 2)	Virchow's Archiv, 1894, June	Adenoma

Examinations on Cases of Acromegaly.

Thyroid gland.	Thymus gland.	Sympathetic ganglia.	Remarks.
—	—	—	—
—	—	—	—
Hypertrophy	—	Hypertrophy	Pineal gland enlarged.
,,	Hypertrophy	,,	Brain enlarged, specially the medulla oblongata.
,,	—	—	—
—	—	—	—
—	—	Hypertrophy	—
Hypertrophy	Absent	Normal	—
Hypertrophy; colloid cysts	Persistent	—	—
Atrophy; interstitial fibrosis	—	Hypertrophy	Capsule of spleen and trabeculæ thickened, whole organ enlarged.
Hypertrophy; interstitial fibrosis	Persistent	—	Degeneration and atrophy of muscles.
,,	,,	—	Brain enlarged; degeneration and atrophy of muscles.
—	—	Hypertrophy	—
Atrophied	—	—	—
Normal	Absent	—	—
Hypertrophy	Persistent; left lobe hypertrophied	—	—
Normal	Persistent	—	—
Hypertrophy	—	—	—
Interstitial fibrosis	—	—	Hyperplasia of lymph glands, and spleen pulp and follicles. Degeneration and atrophy of muscles.
—	Absent	—	Spinal cord hypertrophied (microscoped).
"Chalk-like" deposits	Persistent	—	—
Hypertrophy; contains colloid masses	,,	Hypertrophy, with degeneration	Fibrosis and degeneration of nervous system generally. Degeneration (Goll's column) of muscle-fibres.

No.	Case of	Where published.	Pituitary body.
23	Tamburini	Rivista Sperimentale di Freniatria, 1894, vol. xx, fasc. iii, iv	Adenoma
24	Dallemagne	Arch. de Méd. Exp. et d'Anat. Path., vol. vii, 1895, p. 588	Sarcoma
25	"	Ibid.	Hypertrophy of posterior lobe, and foci of colloid degeneration
26	"	Ibid.	Anterior lobe hypertrophied; posterior lobe, small cysts, ? colloid
27	Sigurini and Caporiacco	Rif. Med., vol. ii, 1895, p. 376	Large round-celled tumour
28	Worcester	Boston Med. and Surg. Journ., vol. cxxxiv, p. 413, April, 1896	Spindle-celled sarcoma, with psammomatous degeneration
29	Roxburg and Collis	Brit. Med. Journ., July 11th, 1896	Glioma or sarcoma (?)
30	Cunningham and Thompson	Journ. of Anat. and Phys., 1890, p. 475; 1897, p. 508	Large as a walnut
31	Klebs	Die allgemeine Path., Jena, 1897, p. 559	Cystic adenoma
32	Arnold (Case 1)	Zeigler's Beiträge, viii, 1891	Sarcoma or lymphadenoma
33	Boyce and Beadles	Journ. of Path. and Bact., 1893, vol. i, p. 350	Colloid degeneration
34	Boltz	Deutsche med. Woch., 1892, p. 635	Adenoma
35	Griffith	Brit. Med. Journ., 1895, vol. ii, p. 953	Large sarcoma
36	Mossé and Daunic	Bull. de la Soc. Anatomique, Paris, 1895, p. 633	Neurogliomic sarcoma with spindle-celled fasciculi
37	Bourneville and Regnault	Ibid., 1896, p. 587	Hypertrophy
38	Comini	Archivio per le scienze mediche, xx, 1896, p. 435	Sarcoma
39	Pineles	Wiener med. Blat., June 12th, 1895; Neurol. Centralbl., 1895, p. 720	Large-celled sarcoma
40	Hausemann	Berliner klin. Woch., 1897, p. 417	Large-celled sarcoma
41	Uhthoff	Berliner klin. Woch., 1897, p. 461	Sarcoma
42	Osborne	Yale Med. Journ., Nov., 1897, p. 1	? Sarcoma, small-celled and cystic. Same growth in small tumours attached to base of brain
43	Bonardi	Arch. Ital. di Clinica Medica, 1893, xxxii, p. 356	Fibrosis, with atrophy of the glandicular follicles (5 times normal weight)

Thyroid gland.	Thymus gland.	Sympathetic ganglia.	Remarks.
Normal	Absent	Normal	Some degeneration in spinal cord, *i. e.* in column of Burdach. Proliferation of nuclei and thinning of muscle-fibres.
Colloid degeneration	—	—	Some sclerosis of spinal cord.
Normal	—	—	Enlargement of all the viscera.
Cystic degeneration	—	—	Sclerosis of spinal cord, especially of Goll's column. Patient died of gastric cancer.
—	—	—	—
—	—	—	Combination of myxœdema and acromegaly.
Normal	Hypertrophy	—	Left optic tract completely destroyed.
—	—	Splanchnic nerves enlarged	Increased length of intestine, from pylorus to anus 48 feet. Liver, spleen, and kidneys enlarged. Stomach enormous.
—	—	—	Eyeball enlarged.
—	—	—	Third nerve involved by a growth in pituitary.
Simple hypertrophy	—	—	Liver normal, spleen 20½ oz., kidneys over 12 oz.
—	—	—	—
—	—	—	Nothing of special interest in the form of defect in field of vision.
Colloid degeneration	Persistent	—	Very large tumour compressing the frontal lobes of the brain. Medullary cavities highly vascular.
—	—	—	—
—	—	—	—
Colloid degeneration cysts	—	—	Spleen very small, cavernous sinus involved.
—	—	—	Pituitary growth lay directly under the pharyngeal mucous membrane.
—	—	—	Pituitary growth involved third ventricle.
Enlarged 101 grams, also a thoracic thyroid gland weighing 36·5 grams	—	—	Liver, spleen, and heart greatly enlarged, chiefly due to increase of connective tissue.
Atrophy with fibrosis	Absent	Normal	—

No.	Case of	Where published.	Pituitary body.
44	Norman Dalton	Trans. Path. Soc., 1897, vol. xlviii, p. 166, and vol. xlix, p. 242	? Hypertrophy or sarcoma
45	Neal and Smyth	Trans. Path. Soc., vol. xlix, p. 244	Enlarged to about the size of a closed fist, and roughly divided into two lobes (hypertrophy)
46	Rolleston	Trans. Path. Soc., vol. xlix, p. 237	Round-celled sarcoma
47	Godlee	Path. Soc. Lond., Nov. 2nd, 1897	Adenoma
48	Hunter	Trans. Path. Soc., vol. xlix, p. 246	Vascular hypertrophy
49	Furnivall	Trans. Path. Soc., vol. xlix, p. 204	Adenoma, with cystic degeneration.

Thyroid gland.	Thymus gland.	Sympathetic ganglia.	Remarks.
"Moderately large and quite firm"	Very large; two symmetrical lobes, each 5 inches long	—	Enlargement of all the abdominal viscera, with fibrosis. Thickening of the skin with pigmentation. Glycosuria. A combination of acromegaly and myxœdema.
Enlarged, weight about 6½ ozs.	Absent	—	Enlargement of the spleen and liver.
—	Persistent	—	—
Hypertrophy; degeneration before death	—	—	—
Hypertrophy	—	—	Kidneys hypertrophied. Bones showed abnormal hyperæmia of the medulla.
Hypertrophy with degeneration	Absent	Normal	—

2. *Specimen of tumour of pituitary body from a case of acromegaly.*

By J. Breward Neal, M.D.

[With Plate VI, fig. 1.]

History, &c.—Female aged 41, married, of temperate habits. Admitted into infirmary October 21st, 1893, died June 21st, 1897. Total duration of disease eighteen to nineteen years.

Previous diseases.—Chorea, hæmorrhoids, hæmatemesis.

Present illness.—Symptoms indefinite for several years, the patient noticing that she required larger boots and gloves, and her friends observing an alteration in her features, which became larger and more prominent. There was also deterioration of her general health, and for several months before admission she had suffered from drowsiness, some loss of power in legs, and occasional headache, with increased appetite for food. Menses ceased at onset of illness.

On admission she presented well-marked signs of acromegaly, the face bones, especially the lower jaw, being prominent and apparently hypertrophied, with some general enlargement of the head. The lips were thickened and protruding, and the tongue large and often partially projecting between lips, giving the patient a fatuous aspect. The hands and feet were enlarged, the chest deformed, and there was kyphotic curvature of the spine in dorsal region.

The eyeballs were prominent, and she was quite blind, the optic discs showing white atrophy. There was also a marked external strabismus.

There was general muscular wasting and loss of power in limbs, with absence of reflexes. Sensation seemed unimpaired.

The *thyroid gland* was not obviously enlarged. Her mental condition was very dull, and she had incontinence of urine and fæces.

Course and subsequent history.—She improved considerably in her general health and in her mental condition soon after she first came under treatment. No material alteration, however, occurred beyond this, and for twelve months or so before her death there was little or no indication for symptomatic treatment, the patient eating and sleeping well as a rule.

She was treated with thyroid extract soon after admission, and she seemed to improve slightly, physically and mentally, as a result. This was discontinued after two or three months on account of diarrhœa and vomiting which supervened; on subsequent occasions the same effects were produced when further trial of the extract was made, and it was accordingly omitted altogether.

Constipation was a somewhat prominent symptom, and required periodical treatment.

Termination.—She was taken ill somewhat suddenly with vomiting, followed by diarrhœa, rise of temperature, and signs of commencing pneumonia. Exhaustion rapidly supervened, and she died about thirty-six hours later.

Post-mortem examination (two days after death).—*External appearances.*—Body was fairly nourished, but there was general muscular wasting and a flabby condition of the subcutaneous tissues everywhere.

Face: the enlargement of bones was most conspicuous in the head and face, and especially marked in the malar prominences and in the lower jaw. There was general enlargement of the features also, especially affecting the nose, ears, and lips.

Trunk: the angle formed by the manubrium with the body of the sternum was very prominent, causing a general projection of the front of the chest, and some flattening on either side. There was also marked kyphosis of dorsal region of the spine.

Upper limbs: the hands were flabby and spade-like, but did not appear notably enlarged, and on removing one of the metacarpal bones there did not seem any hypertrophy of the bone.

Lower limbs: the knee-joints were enlarged, in a position of slight flexion, and the bones entering into their structure were apparently affected by outgrowths of an osteo-arthritic nature. Both feet were unduly large, prominent, and flattened on the plantar aspect, and there was great enlargement of the metacarpo-phalangeal joints of both great toes.

The *clitoris* was greatly hypertrophied and elongated.

The subcutaneous fat was everywhere fairly abundant, and there was an unusual amount beneath the scalp.

The muscles everywhere were pale and flabby.

Internal examination.—Head: the vertex of the skull presented some irregularity of the surface in several situations, especially in the right posterior parietal region, the bone in this area being

prominent, uneven, and perforated by small apertures, which contained vascular prolongations of the pericranial aponeurosis. These extended to the inner surface of the skull, but had no connection with the dura mater, which was not adherent. The skull was markedly thickened in places, especially in frontal and occipital regions, the thickness varying in an irregular manner in different parts of the circumference on the two sides.

Brain: the membranes appeared normal. On removal of the brain a large tumour was found on the under surface, occupying the central portion of the middle fossa of the base of the skull, and overlapping also slightly the anterior and posterior fossæ; thus completely filling the pituitary fossa and extending also on each side of this to some extent. It was smooth on the surface and covered with what appeared to be a prolongation from the pia mater, except on the right side over a small area where this had been torn away. The tumour was roughly divided into two lobes, right and left, the former being slightly larger, and it measured 3 inches in the transverse diameter by 2 to 2½ antero-posteriorly, being of an oblong shape. The optic tracts were stretched over the tumour and much flattened. The pituitary fossa of the sphenoid was enlarged, and the anterior clinoid processes widely separated. (The anterior half of the base of the skull was removed with the tumour *in situ.*)

Weight of brain 44½ oz. There was a marked concavity on the under surface, corresponding to the position of the tumour, and the parts forming the floor of the third and adjoining portions of the lateral ventricles were greatly thinned. Except for this condition there was no other noticeable appearance, and the substance of the brain seemed normal.

Spinal cord was removed for part of its extent; no abnormal appearances were seen by the naked eye, except a few small bony and calcareous particles on the inner surface of the dura mater.

The *thyroid gland* was considerably enlarged, weighing 6½ oz. The right lobe was slightly larger than the left, but otherwise the increase in size was uniform.

The *thymus gland* was not seen.

Chest.—Lungs weighed 35 oz. each. Both were congested at bases and posterior parts, and there was some early pneumonic consolidation of both lower lobes.

Heart weighed 18½ oz.; enlarged generally. The mitral valve

was thickened, and showed calcareous deposits, and there were old vegetations present on one of the cusps. The tricuspid valve was also somewhat thickened.

Abdomen.—Liver weighed 72 oz. No distinct morbid appearances present, beyond general enlargement of the organ.

Spleen was greatly enlarged, and weighed 18 oz. Substance appeared normal on section.

Kidneys each weighed 7 oz. Appeared normal on section.

Stomach.—Mucous membrane congested, but otherwise healthy.

Intestines.—There was accumulation of fæces in the sigmoid flexure and rectum, but no other abnormal conditions were noted.

November 2nd, 1897.

Histological report on Dr. Neal's case of acromegaly at Wandsworth Infirmary (by S. G. Shattock, F.R.C.S.).—*Thyroid.*—The gland is uniformly enlarged, but to no very notable degree. To the unaided eye the cut surface presents the structure of an ordinary parenchymatous goitre, and the microscopic characters correspond. The gland spaces, which are of abnormal size, are lined with a single layer of cubical epithelium, and enclose homogeneous colloid. There is no trace of papillary ingrowth into the spaces, as in the thyroid enlargement associated with Graves's disease.

Pituitary body.—The sections reveal a remarkably uniform structure of polyhedral cells, somewhat large in size, and without visible intervening substance. There is scarcely a trace of connective-tissue stroma, the cells closely filling the meshes of a capillary network, and resting directly on the capillary wall. In general characters the cells resemble those of the anterior lobe of the pituitary body. The changes may therefore be classed under the head of hypertrophy, as the enlarged body is everywhere encapsuled, and the surrounding bone uninvolved.

No actual enlargement of the bones of the hands or feet is present.

November 2nd, 1897.

[A more extended Pathological Report upon this case of acromegaly is appended.]

3. *Pathological report upon a case (Dr. Breward Neal's) of acromegaly.*

By Samuel G. Shattock.

[With Plate VI, fig. 1.]

The parts of the body removed and handed over to me comprised the pituitary and thyroid bodies, the spleen, one of the metacarpal and one of the metatarsal bones.

The two bones are quite smooth, and their shafts, if anything, unusually slender, so as to produce an apparent enlargement of the articular ends.

The size of the spleen is somewhat increased; 5¼ inches (13·3 cm.) in length, 2 inches (5 cm.) in extreme thickness. Its section offers nothing for notice.

Thyroid.—The gland is uniformly enlarged, though to no very notable degree; the extreme length of the lateral lobes is 7·5 cm. (3 inches).

To the unaided eye the cut surface presents the structure of an ordinary parenchymatous goitre, and the microscopic characters correspond. The gland spaces, which are of abnormal size, are lined with a single layer of cubical epithelium, and enclose homogeneous colloid. There is amongst the epithelial cells no reversion to a columnar type, and no trace of parietal infolding, such as occur in the compensatory hypertrophy of the thyroid which follows partial excision of the gland, and which are met with also in the goitre of Graves's disease.

Pituitary body.—This is remarkably enlarged, and measures over 2½ inches (6·5 cm.) in the vertical direction. Its lower portion occupies a correspondingly enlarged pituitary fossa, and has a diameter of one inch, the fossa itself being as much as 1½ inches (3·8 cm.) in depth; its upper projects as an overhanging somewhat globular swelling into the cranial cavity, and has an antero-posterior diameter of 1¾ inches (4·5 cm.). The enlarged gland presents on section a homogeneous macroscopic structure, and it is everywhere circumscribed by a capsule of fibrous tissue.[1]

The histological sections reveal a monotonously uniform struc-

[1] Half of this specimen is in the museum of the Royal College of Surgeons.

Fig. 1.

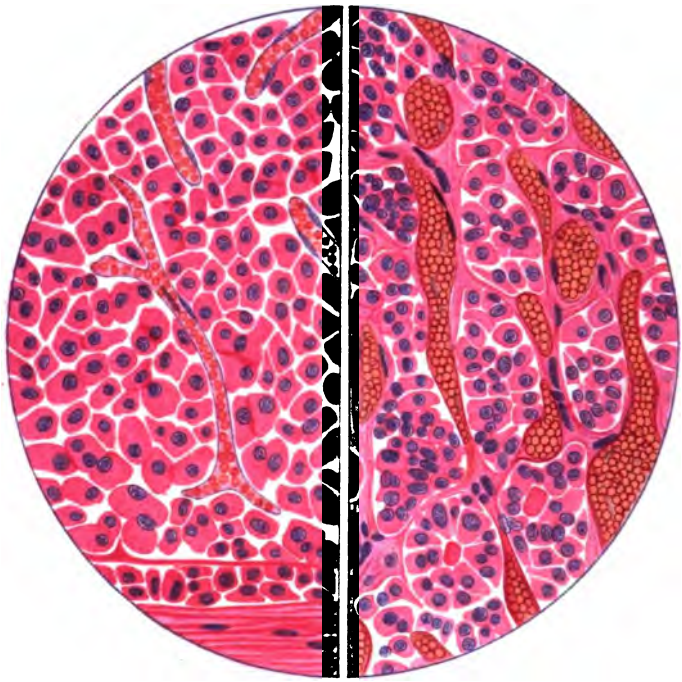

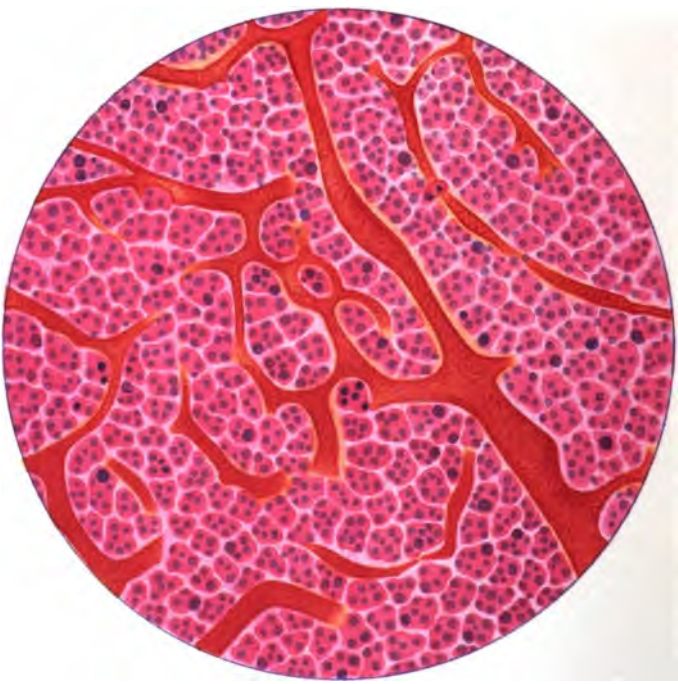

Fig. 2.

DESCRIPTION OF PLATE [illegible]

[illegible] 1 illustrates Mr. S. G. Shatte[illegible] Pathol[illegible] of Acromegaly. (Pages [illegible])

[illegible] half of the figure shows a portion [illegible] the right portion of a no[illegible] pituitary [illegible] hematoxylin followed by eosin, and [illegible] [illegible], oc. 2.)

[illegible] pituitary is bounded by [illegible] [illegible] in the figure.

[illegible] thyroid cells, which are [illegible] [illegible] size [illegible] There is scarcely a trace of [illegible] [illegible] pituitary walls.

[illegible] half of the figure [illegible] a portion of the [illegible] pituitary gland, which was removed [illegible] by [illegible] also hardened, first in [illegible]'s fluid, afterwards [illegible] [illegible] proximity to the posterior lobe, but [illegible] [illegible] groups scattered in the latter.

[illegible] figure shows a close mesh work of capillaries, [illegible] [illegible] filled with continuous masses of large [illegible] [illegible] places a lumen exists. This is [illegible] [illegible] around being more or less [illegible] between. The [illegible] tissue is [illegible] [illegible] capillaries directly supporting the epithelia.

[illegible] 2 illustrates Dr. W[illegible] Hunter [illegible] [illegible]tary body in Acromegaly." (Pa[illegible]

[illegible] of pituitary body after hardening in [illegible] [illegible] shows its [illegible] structure, [illegible] [illegible] [illegible] 4, [illegible] 1.

DESCRIPTION OF PLATE VI.

Fig. 1 illustrates Mr. S. G. Shattock's Pathological Report on a case of Acromegaly. (Pages 224 and 228.)

The left half of the figure shows a portion of the periphery of the pituitary goitre; the right, portion of a normal pituitary gland. The stain in each case is Ehrlich's hæmatoxylin followed by eosin, and the sections are equally magnified. ($\frac{1}{8}$ obj., oc. 2.)

The enlarged pituitary is bounded by a capsule of fibrous tissue, part of which is included in the figure.

The epithelial cells, which are larger at the periphery than more internally, and here exceed in size those of the normal gland, fill the meshes of a capillary network. There is scarcely a trace of stroma, the cells resting directly upon the simple capillary walls.

The right half of the figure represents a portion of the anterior lobe of a normal adult pituitary gland, which was removed *in situ* by cutting out the sella turcica, and so hardened, first in Müller's fluid, afterwards in alcohol. The spot figured is in close proximity to the posterior lobe, but does not include any of the epithelial groups scattered in the latter.

The figure shows a close meshwork of capillaries, the intervals between which are quite filled with continuous masses of large multiform cells.

In two places a lumen exists. This is occupied with homogeneous colloid, the cells around being more or less columnar; such spaces, however, are few and far between. The connective tissue is remarkably small in amount, many of the capillaries directly supporting the epithelial cells lying around them.

Fig. 2 illustrates Dr. William Hunter's case of "Hypertrophy of Pituitary Body in Acromegaly." (Page 246.)

Section of pituitary body after hardening in formalin and staining in logwood and eosin.

The gland shows its normal acinous structure, but great distension of its capillaries with blood. (Hartn., obj. 4, oc. 4.)

ture of large polyhedral cells without visible intervening substance. There is scarcely a trace of stroma, the cells closely filling the meshes of a capillary network, and resting directly upon the proper capillary wall.

The cells themselves have a finely granular or nebulous body, and special nucleus displaying the usual chromatic network.

The portion examined includes the periphery of the enlargement, and this is bounded by a thin, well-defined capsule of close fibrous tissue. The cells at the periphery are distinctly larger than those lying more internally, and they are more intensely coloured with the eosin, but this colour merges by imperceptible grades into the less crimson or bluish pink of the general mass.

Compared with the anterior lobe of the normal pituitary gland, the histological picture closely resembles it both in the scantiness of stroma, the prominence of capillary network, and the general characters of the cells. The peripheral cells of the enlarged gland are distinctly larger than those of the normal, but the more internal are of corresponding size.

In the normal gland certain of the cell bodies in a logwood-eosin preparation stain red, others blue. Such cells have been termed eosinophile and cyanophile respectively, though what the difference indicates is unknown. I have seen such differently staining cells in juxtaposition, but it must be borne in mind that every gradation obtains between the two, and that the main bulk of the cells acquire an intermediate colour.

As studied with $\frac{1}{12}$ homogeneous immersion, many of the cells in the normal gland are in various degrees vacuolated.

In high grades the vacuolation is so extensive as to lead to the general appearance presented by a plasma cell, *i. e.* the cell body contains not a single large space, but a close-set series. Such cell bodies take in consequence little or no stain, and possibly represent the cells which Comte ('Ziegler's Beiträge,' 1898) has named "chromophobe" in contra-distinction to the chromophile. Besides such vacuolation the granularity of the cell body differs in closeness; in some cells it is comparatively coarse and discernible, in others the body is nebulous or like ground glass. Such appearances, however, are common in cells of all kinds, and result from swelling of the hyaloplasm, the spongioplasm being rendered in consequence more open and apparent, and the entire cell larger.

In logwood-eosin sections of such a growth as a mammary carci-

noma somewhat similar vacuolated cells are to be seen with $\frac{1}{12}$. These are such as have undergone advanced fatty degeneration, the vacuoles being the spaces from which the oil has been removed by the alcohol in the course of preparation. This is obvious from a study of sections cut from tissue hardened in osmic acid and mounted in glycerine. I have found by the comparison of sections of normal pituitary similarly prepared, with those passed through alcohol and dyed with logwood and eosin, that the vacuoles in the epithelial cells are due to the same cause, though the term degeneration is not, perhaps, here applicable. The spaces which are quite empty in the alcohol specimens correspond precisely in form, size, and numbers with the deep black droplets of fat which are shown in the cell body in the osmic acid preparations. The fat droplets in individual cells are not many; their numbers correspond roughly with those met with in the cells of normal cartilage, though even here as a final stage of fatty infiltration the cell may be almost filled.[1] The distribution of the fat, however, is extensive, large numbers, if not the majority, of the cells showing its presence.

The gland upon which I made these observations was from a man aged twenty-two, who died with intussusception; the sections exhibiting the corresponding vacuoles were from a second normal gland.

When the abnormal and the normal glands are compared it appears that the latter does not present epithelial cells so large as those in the periphery of the diseased; but with this exception they closely correspond. The larger size at the periphery may be taken as indicating an active growth in this direction; thus Mr. Walter Edmunds notices enlargement of the cells in the parathyroid of a dog in which the whole of one lobe of the thyroid with the corresponding parathyroids was excised as well as the greater part of the opposite lobe of the thyroid, the dog remaining well and being killed at the end of six weeks ('Path. Soc. Trans.,' vol. xlvii, 1896).

In one particular the normal and pathological pictures differ; there is nowhere any trace of colloid, either within or between the cells of the pituitary goitre.

[1] The somewhat wide distribution of fat in these and other normal tissues may be compared with that of starch in plants, and is probably a physiological storage of carbohydrate.

The pathological formation sufficiently repeats the histological features of the normal to allow of its being classed as an hypertrophy of the pituitary body or a pituitary goitre.

Its limitation by a fibrous capsule, and the fact that it has not invaded the osseous tissue, remove it from the class of carcinomata; of malignant formations it is, indeed, more suggestive of a large round-celled sarcoma than of a carcinoma, by reason of the remarkable scantiness or absence of stroma and absence of glandular secretion.

In the case of the thyroid, as elsewhere, the term "adenoma" is commonly restricted to circumscribed formations of new gland tissue, a generalised enlargement being distinguished as hypertrophy. For this reason it is undesirable to name a general enlargement of the pituitary body an adenoma. If it is thought that the new tissue is not sufficiently like the normal to justify the use of the term hypertrophy, that of pituitary goitre may be here suggested as indicating a general enlargement closely if not absolutely of the nature of an hypertrophy and parallel with the various forms of benign enlargement of the thyroid.

In the problem presented, however, by acromegaly, the real question at issue is a physiological one; and what has to be determined by future investigation is whether there is a perversion or abeyance of pituitary function, which is not disproved by mere enlargement of the gland, even of the kind under consideration. The phenomena of acromegaly have sufficient resemblances to those of myxœdema and cretinism to render some caution necessary, lest arguments of the class once used against the causal relation of disease or absence of the thyroid in myxœdema and cretinism be allowed to settle the pathogenesis of acromegaly. How little is known of the altered physiology of the thyroid is well illustrated by the views held as to the part played by the enlarged thyroid in Graves's disease; for it is an undetermined matter whether there is a rapid removal of an excess of normal secretion, or the production of a secretion that is positively abnormal, and in consequence leads also in part to the results arising from an absence of the normal. In the latter way Mr. Victor Horsley would explain the dyspnœa of Graves's disease as that of athyroidea, although the gross size of the thyroid is increased.

The same want of knowledge is obvious also in those cases

where cretinism is associated with enlargement of the thyroid in place of its absence; here, again, it must be assumed that the function of the gland is at fault, although its mere volume is augmented.

The absence of symptoms in cases of tubercular and syphilitic disease or of certain benign or malignant tumours of the pituitary, is readily intelligible when it is remembered that none of these lesions are necessarily so destructive of the gland tissue as to entail a complete abeyance or perversion of its function any more than they are in the case of the thyroid.

The most recent writer on the relationship between the functions of the pituitary and thyroid glands (Louis Comte, 'Ziegler's Beiträge,' 1898) concludes from the examination of over 100 miscellaneous cases that these organs act vicariously. Not only have different authors described increased activity of the pituitary after excision of the thyroid (as evidenced by its hypertrophy), but pathological observations point to the same conclusion.

In goitre the examinations of Comte show that the pituitary increases in weight, though not in proportion to the volume of the thyroid. In explanation of this it is to be noted that parenchymatous enlargement of the thyroid does not imply an increased output of secretion into the circulation.

Mr. Victor Horsley has recorded a case of parenchymatous goitre accompanied with dyspnœa, which was not relieved by complete excision, the dyspnœa being due not to mechanical obstruction, but to the cause (whatever it is) to which it is due in athyroidea. The justness of this view is borne out by the recent analyses of Roos (Hoppe-Seyler's 'Zeitschrift für Physiologische Chemie,' Band xxv, Heft 1, 1898), who confirms Baumann's original observation that the iodine constituent of goitrous thyroid is less than in the normal gland. The observations of Roos were made upon Swiss, highly colloid goitres, and upon normal unenlarged human thyroids from Kiel, with the result that in the first there were 1·31 per cent. of iodine, and in the normal glands 2·58.

In the course of pregnancy both the thyroid and the pituitary undergo a temporary enlargement.

In the single case of myxœdema examined by Comte (loc. cit.) there was an excess of colloid in the pituitary. This observation accords with those already made by Prof. Boyce and Mr. Cecil Beadles ('Journal of Pathology,' March, 1892), who were the first to

describe pituitary overgrowth in two cases of myxœdema; in one of these there was a striking increase in the pituitary colloid. These authors include, moreover, a single example of sporadic cretinism in which, in confirmation of the previous observations of Nièpce ('Goitre et Crétinisme,' Paris, 1851) and one of Bourneville and Bricon ('Archives de Névrologie,' 1886), they found the pituitary enlarged.

Although the thyroid is enlarged in the case of acromegaly under consideration, this cannot be regarded as due to a compensatory overgrowth, seeing that, as before pointed out, the histological picture is that of a common parenchymatous goitre (in which the analyses of Roos show a deficiency of iodothyrin), and that there is an absence of the parietal infoldings which are to be seen in the true compensatory or vicarious hypertrophy following partial excision of the thyroid gland, and which are so prominent a feature in the goitre of Graves's disease.

The chemico-physiological aspect of this question has proved more complex than the first observations of Oliver and Schäfer seemed to indicate; thyroid extract causes dilatation of arteries and consequent fall of blood-pressure without diminishing the heart's beat, whilst that of the pituitary increases the contraction of the arteries and the heart, giving rise to marked increase of blood-pressure, and without slowing the heart-beat as happens in the case of adrenal extract.

In these experiments sheep pituitary was used, and in this animal the posterior lobe, like the anterior, is glandular in structure. The observations of Mr. W. H. Howell ('Journal of Experimental Medicine,' vol. iii, No. 2, p. 245, March, 1898), made upon the two lobes separately, gave the result that whilst extract of the anterior lobe caused little or no perceptible change in blood-pressure or heart-rate, and had no characteristic effect upon the circulatory or respiratory organs, the extract of the posterior lobe retarded the heart-beat and raised the blood-pressure, these results closely resembling those noticed by Oliver and Schäfer as arising from the injection of adrenal extract, but differing from the latter in the retardation of the heart-beat that it causes after division of the vagi.

The supra-renal itself is no less a composite gland, in that its cortex and medulla present so widely different a structure, and that these component parts may be represented by distinct organs.

In Elasmobranch fishes the observations of Mr. Swale Vincent show that the cortical portion is represented by a U-shaped inter-renal gland, the medullary by a series of small paired bodies seated upon the costal arteries and connected with the sympathetic. In Teleostean or bony fishes the cortex is alone represented. Excellent dissections of the Skate, Dog-fish, and Cod, illustrating these points, have lately been added to the anatomical collection of the Royal College of Surgeons' Museum (Nos. A 1277, A 1277A, A 1277B).

In the original observations of Oliver and Schäfer, however ('Journal of Physiology,' vol. xviii, 1895, p. 230), this, as might have been assumed, was taken into full account, the comparative activity of extracts prepared respectively from the cortex and medulla (by boiling in salt solution) having been investigated, with the result that whilst large doses of the cortical extract were found to be inert, even minute doses of the medullary led to highly pronounced effects.

This observation has been confirmed more recently by Mr. Swale Vincent ('Journal of Physiology,' vol. xxii, p. 111) who, at Prof. Schäfer's suggestion, extended the inquiry by testing extracts of the separate cortical and medullary glands from fish, and has found that the extract of the latter acts precisely like that of the mammalian supra-renal medulla.

But further than this, setting aside the hæmapoietic tissue which it contains, and which was first described by Mr. Victor Horsley in 1884, the human thyroid must probably be regarded as a composite gland. In the human subject, besides the proper vesicular colloid-holding tissue, the thyroid presents certain areas from which colloid is absent, and which have been considered by Wölfler ('Ueber die Entwicklung und den Bau der Schilddrüse,' Berlin, 1880) as gland buds, or "eyes" of young thyroid tissue. It is very noteworthy that these areas have in the main a peripheral, or as it might be termed a cortical disposition, and they may, I think, be regarded as of the same nature as parathyroid tissue, and as representing what in lower mammals constitute the distinct organs known as parathyroid glands.

It would be extremely difficult to say that none of these foci underwent a subsequent development into proper thyroid tissue, for one finds them lying in juxtaposition (in the adult) with vesicular colloid-holding structure, and finds, moreover, transitional cell-groups in which colloid is making its appearance. It is to be

observed here, however, that in the parathyroids of lower animals, although as a rule no colloid is encountered, this is not invariably the case; Mr. W. Edmunds has described thyroid tissue in the parathyroid of the dog ('Journal of Physiology,' vol. xviii, 1895), and one may hold that what is true both structurally and physiologically of parathyroid tissue in such distinct glands is true of the similar tissue within the thyroid. And it is significant that in the mammal next below man, the monkey, the parathyroid is not as in other animals extra-thyroidal, but lies embedded within the proper thyroid itself.

In other mammals the parathyroids, though of small size, are yet obvious from their distinct circumscription and superficial location, for they lie immediately upon the exterior of the proper thyroid, and in microscopic section are found divided from it by a zone of connective tissue. It is an interesting morphological fact in this relation, that in the human subject parathyroid tissue may take the form of a distinct, *i. e.* a discrete structure. One meets with accessory glands which have the structure not of thyroid but of parathyroid tissue, and which may be viewed as variations indicative of reversion to the lower extra-thyroidal type. Such true parathyroids should be distinguished by name from accessory thyroids; they are *accessory parathyroids, i. e.* parathyroids accessory to the parathyroidal tissue normally present in the thyroid itself, and in a general way comparable to the accessory adrenals which may lie upon the exterior or far removed from the main gland, and consist of cortical substance only. I have had the good fortune to examine such an accessory parathyroid, and can corroborate the description of Mr. W. Edmunds, who figures ('Path. Soc. Trans.,' vol. xlvi, pl. xii, fig. 5) the histology of one which was found in the vicinity of the thyroid of a man dying from phthisis. In my own case the accessory gland was quite loosely pendent from the lower border of the isthmus, the subject being a man twenty-two years of age, who died with intussusception; it was of lens-like form, and 5 mm. in diameter, with a thickness of 3 mm. Microscopic sections carried through the entire gland display throughout typical parathyroid tissue, with no trace whatever of colloid or vesicular structure. The capillary mesh is remarkably close, and meanders around groups of polyhedral cells with large spherical nuclei. Compared with the parathyroid of the dog, the tissues are indistinguishable.

The high importance of the parathyroid glands has been shown by many workers, but what the precise difference in function between thyroid and parathyroid tissue is has yet to be cleared up. That the parathyroid tissue is peculiar would appear from one of Mr. W. Edmunds's observations upon a rabbit, in which, 102 days before being killed, the whole of the proper thyroid had been removed, leaving only two parathyroids. The latter were found, after death, little hypertrophied, and devoid of noticeable histological change, *i. e.* they presented no vesicles and no colloid. It is to be regretted that the condition of the pituitary was not inquired into in this or in any of Mr. Edmunds's experiments—a defect which that investigator will doubtless in future remedy. We do not know, for instance, from Mr. Edmunds's experiments whether the colloid-forming function of the excised thyroid was replaced by the pituitary (whether there was an excess of [?] "iodo-pituitin" in the latter), or whether the parathyroids left performed the function of proper thyroid tissue, and some second function besides. These considerations make it obvious that if the human thyroid is, as here suggested, a composite gland, the only method of analysing its physiological action is by the use of separate extracts of the thyroid proper and parathyroids from animals in which these tissues are distinct and separable by dissection.

This being so, it is still less open to doubt that the anterior lobe of the human pituitary is a composite structure. For here the vesicular, colloid-holding component (which is chiefly cortical in position) is put into the background by the chief mass which consists of solid cell columns ramifying as in a parathyroid through the meshes of a close capillary network. When the central portion of the pituitary is compared with human parathyroid tissue the resemblance, however, is only general; the pituitary cells are notably larger. The structure is much more closely like the adrenal cortex of men; where the cells of the latter are largest, viz. in the external zone (zona glomerulosa), the correspondence of these elements and their general disposition are remarkably close. Not of course that the colloidless portion of the pituitary is thus shown to be identical in function with the adrenal cortex, but it points to the great probability of the pituitary having more than one function. This hypothesis will, moreover, harmonise the difficulties in regard to the vicariousness of the thyroid and pituitary bodies.

Some have regarded the two glands as identical because of a

certain degree of pituitary enlargement which follows thyroidectomy and pathological conditions of the thyroid. On the contrary, Oliver and Schäfer ('Journal of Physiology,' vol. xviii, 1895) conclude, from the different effects which follow the experimental injection of thyroid and pituitary extracts, that the functions of the glands are widely divergent. The truth probably is that the two glands are vicarious only as to what they have in common, *i. e.* as to their colloid-producing capacity; and so comparatively small is the colloid present at any given time in the pituitary, that in an extract its action would be masked by the other substance. From the therapeutical side also it follows that thyroid and pituitary extracts can be of service in disease of the converse gland only partially, or in so far as the two glands have a function that is common.

Maximilian Sternberg's excellent summary ('Specielle Pathologie und Therapie,' Band vii, Theil 2, 1897) shows how various are the pituitary lesions that may be associated with acromegaly. And this emphasises the importance which attaches to the altered physiology of the affected gland; the problem of acromegaly has practically passed into the domain of chemical physiology.

November 2nd, 1897.

---

4. *A case of acute acromegaly due to sarcoma of the pituitary body.*

By H. D. Rolleston, M.A., M.D.

History.—The patient, a woman aged 35, had been for the last two years under the care of Dr. Hollis, of Wellingborough, who on two occasions kindly sent her up to be under my care at St. George's Hospital. On the first of these occasions she was treated by pituitary extract with a negative result. A full account of her case at this time was published in the 'Lancet,' 1896, vol. i, p. 1137, and the suggestion was then made that the disease was

due to a disturbance of a chemico-physiological equilibrium, which in health is maintained by the interaction of the internal secretions of the pituitary and thyroid glands. On the second occasion she was treated by a combination of the extracts of these two glands, and her headache, which was extremely severe, seemed to be much relieved thereby.

The case was a well-marked one of acromegaly. Enlargement of the hands dated from the early part of 1894, though the patient had not been well since the birth of a child in 1891. The characteristic skeletal changes were present, in addition to advanced double optic atrophy and transient glycosuria. There was no post-sternal dulness, and the outline of the thyroid gland was normal.

Death took place in coma on August 16th, 1897, after an epileptiform fit, of which she had had several since June, 1897.

At the autopsy there was no pigmentation of the skin.

The skull bones were neither thickened nor thinned, and the dura mater was not unduly adherent. The pia arachnoid was thickened and adherent over the lips of the right Sylvian fissure, and also over the tip of the left temporo-sphenoidal lobe.

Both the olfactory nerves was normal, though rather thin.

In the situation of the pituitary body there was a soft creamy tumour the size of a walnut, covered over by dura mater and projecting with its convexity upwards. The growth was so soft that its removal was attended with great difficulty; indeed, a considerable amount of new growth was left behind in the deepened sella turcica.

No distinction between the anterior and posterior lobes of the pituitary body could be recognised.

The growth had extended to the floor of the third ventricle and invaded the anterior and mesial surface of the right optic thalamus, which on section was seen to be mottled by patches of white creamy growth. It appeared that the growth had extended upwards along the right optic tract.

The optic nerves were greatly displaced by the tumour, both of them were thinned and atrophied, and the right was almost destroyed at one point.

While under treatment in St. George's, my colleague Mr. Grimsdale pointed out the fact that there was a hemiopic pupillary reflex in the left eye; it was not obtained on the right side, that

eye being quite blind. The presence of the hemiopic reflex points to a lesion of the optic tract.

The left optic thalamus was normal.

Laterally the growth had eaten its way into the right cavernous sinus, and from thence into Meckel's space, and had begun to invade the tip of the petrous bone.

The sella turcica was very deeply excavated and as large as a walnut, the walls being smooth; the posterior clinoid processes were markedly displaced backwards as the result of pressure exerted by the growth.

The brain weighed 49 oz. The convolutions were slightly flattened and both lateral ventricles were dilated; this was probably due to pressure exerted by the pituitary tumour on the neighbourhood of the foramen of Monro, since neither the third nor the fourth ventricles were similarly affected. The pineal gland was healthy. There was no softening anywhere on the cortex, and no thrombosis of the veins.

The thymus gland was persistent though not hypertrophied, and indeed might easily have been overlooked had it not been especially looked for. Microscopically its structure was well preserved. Hassall's concentric corpuscles were prominent, and were much larger than they normally are in children, or in the remains of the gland, or when persistent in older persons.

The thyroid body was normal in size. Microscopically a few of its vesicles showed adenomatous growth and were devoid of colloid material, but the majority were quite healthy.

The liver was enlarged, weighing 76 oz., and appeared to be in an early stage of fatty infiltration. The gall-bladder was distended with bile, but did not contain any calculi.

The spleen, 8 oz., appeared normal.

The kidneys, 5½ oz. each, were healthy.

Microscopically the pituitary growth was a medium-sized round-celled sarcoma. It did not show any indications of being an adenoma, and was not vascular or cystic, and did not contain any colloid material.

Remarks.—The chief interest of the case lies in the facts that while the growth was undoubtedly sarcomatous, as shown by the fact that in addition to its histological structure it had invaded the brain and petrous bone, the disease had lasted three years. It may be noted in passing that the intense headache and the epi-

leptiform convulsions were the effects of a cerebral rather than of a pituitary tumour.

The course of the disease (three years), which is comparatively long for malignant disease, suggests either that some change had taken place in the nature of the pituitary tumour, such as the supervention of a more malignant and rapid type of growth in the later stages of the disease, or that pituitary sarcoma is less malignant than sarcoma in general.

Sternberg,[1] from an examination of 210 published cases and 47 *post-mortem* records of acromegaly, divides the disease into three varieties: (*a*) the benign form, lasting fifty years; (*b*) the ordinary type, chronic acromegaly, lasting eight to thirty years; and (*c*) the acute form, of which there are but six cases, all due to sarcoma of the pituitary body, in which the disease lasts from three to four years. The present case appears to be a member of this group, which, with two cases referred to by Williamson[2] and Osborne (see Addendum, p. 241), now numbers ten cases.

It is noteworthy that while sarcoma of the pituitary body may, as shown by this and by other recorded cases, give rise to acromegaly, the invasion from without of a sarcoma arising from the middle fossa of the skull may prove fatal without any symptoms of acromegaly developing. Primary tumours of the pituitary body need not give rise to symptoms of acromegaly; as an example we may refer to Mr. Woolcombe's case of psammoma of the pituitary body.[3] This is quite analogous with the occurrence of new growths, whether primary or secondary, in the supra-renal bodies, without any signs of Addison's disease.

A point of interest is the absence of any ocular paralysis on the right side, which would certainly have been expected from the extensive infiltration of the right cavernous sinus by the new growth.

The association of a persistent thymus has often been noted in acromegaly. P. Marie[4] drew attention in 1893 to the fact, which is now well recognised, that this persistence occurs in affections of the thyroid and of other glands presumably connected with the elaboration of the blood. Thus in cretinism a persistent thymus is found almost invariably, while in cases of myxœdema developing

[1] 'Die Akromegalie,' p. 67, 1897.

[2] Williamson, 'Medical Chronicle,' May, 1897, new series, vol. vii, p. 86.

[3] Woolcoombe, 'Brit. Med. Journ.,' 1894, vol. i, p. 1350.

[4] P. Marie, 'Bull. et Mém. Soc. Méd. des Hôp. Paris,' 1893, p. 136.

after puberty or in adult life he says that the thymus may develop afresh. He also refers to this condition in exophthalmic goitre and in acromegaly.

In the last volume of the 'Pathological Society's Transactions' Drs. Hector Mackenzie and Edmunds[1] described two cases in which a persistent thymus was found in Graves's disease, and pointed out that Hassall's corpuscles do not undergo degeneration so readily as in the normal state, but persist and grow larger. In the present case of acromegaly Hassall's concentric bodies were also much enlarged, and might be said to have shared in the general giant growth. It is noteworthy that in both exophthalmic goitre and in acromegaly the concentric bodies have been noticed to be enlarged. Dr. Dalton[2] in the same volume of this Society's 'Transactions' records the large size of the thymus in a case of acromegaly.

Maximilian Sternberg[3] sums up the condition of the thymus in acromegaly by saying that it may be enlarged and present the appearances normal in children, or may undergo involution in the ordinary way, and occasionally show calcification.

The condition of the thymus may either be regarded as a persistence or as a rejuvenescence of a gland which had already undergone some, if not all, the stages of normal involution. As to the meaning of thymus enlargement we are still in the dark; that it is an attempt at compensation has been suggested, but it is perhaps more probable that its enlargement is part of the morbid lesions bound up with the profound changes occurring in acromegaly, cretinism, &c.

The liver was enlarged. Splanchnomegaly or enlargement of some or all of the viscera has been recorded in acromegaly, notably by Dr. Dalton, who quotes a marked case of Dr. Dallemagne. The enlargement is interesting as showing the relation of acromegaly to general pathological overgrowth and pathological giants.

Addendum.—Since the paper was read I have seen Dr. O. T. Osborne's[4] extremely carefully recorded case of acromegaly in a

[1] Mackenzie and Edmunds, 'Trans. Path. Soc.,' vol. xlviii, p. 192.

[2] Dalton, ibid., vol. xlviii, p. 166.

[3] Sternberg, 'Die Akromegalie,' p. 27, 1897.

[4] Osborne, 'Trans. Assoc. American Physicians,' vol. xii, p. 262.

man who died at the age of forty-seven, having had the disease for twenty-four years. In the sella turcica there was a pulpy mass containing a cyst; microscopically there was some doubt as to the nature of the growth, but it is stated that "probably it is to be classed among the sarcomata." The right cavernous sinus and the Gasserian ganglia on both sides, but less so on the left, were invaded by the growth.

This observation is of especial interest when the long duration of the disease is borne in mind, as tending to suggest that sarcomatous growth had become implanted on an old-standing cystic condition of the pituitary body.

Splanchnomegaly was well marked. The heart weighed 41 oz., and only showed some slight thickening on the edges of the aortic valves. The right kidney contained three large cysts, and after they were emptied weighed 11 oz.; the left kidney weighed 10½ oz. Microscopically they showed slight interstitial and very slight parenchymatous change. Liver 7 lbs. 2 oz., was slightly congested, and showed early cirrhosis. Spleen 36 oz. The thyroid weighed 101 grammes (normal weight 30 to 60 grammes), and an accessory thyroid in the thorax, containing a large amount of iodine, 36·5 grammes. The lungs showed the effects of excessive inhalation of dust accompanied by chronic passive congestion and slight emphysema. Left lung 47 oz.; weight of right lung not given.

November 2nd, 1897.

---

5. *Further notes on a case of acromegaly.*

By Norman Dalton, M.D.

At the end of last session I showed the viscera of a man who had died of diabetic coma after having been affected with acromegaly for four years; and I am taking this opportunity of describing the microscopical appearances of these organs. The naked-eye appearances are recorded in the 'Transactions' of the Pathological Society for last year (vol. xlviii, p. 166), but the chief points

were that, in addition to the better known changes in the features, face, and hands, there was a well-marked increase in the size and weight of the liver, spleen, pancreas, thyroid, thymus, and in fact nearly all the organs. During life there had been diabetes, while the apathetic mental condition and the thickening of the skin suggested myxœdema.

The microscopic changes were as follows:—The medulla, spinal cord, and optic nerve were normal, except that the central canal of the cord was obliterated.

The intestines showed catarrhal inflammation and increase of the subepithelial connective tissue. There was no inflammatory infiltration of this connective tissue, so that I think the thickening was not inflammatory but such as occurs in myxœdema.

The solitary glands were enlarged by an increase of their lymphoid cells, which stained badly and appeared necrotic. The mesenteric glands showed the same changes as the solitary glands of the intestine.

The spleen was normal.

The cells of the pancreas were necrotic, and there was some increase of its connective tissue.

In the kidney there was very marked increase of connective tissue, and the tubes were filled with degenerated epithelium.

There was no increase in the connective tissue of the liver. The capillaries were gorged with blood, but did not compress the liver-cells, some of which were fatty, while most were normal. A few liver-cells showed very great enlargement of their nucleus, as if they were multiplying at an exceptional rate.

The thymus was normal, but stained badly. The thyroid was also normal, *i. e.* there were no intra-alveolar papillæ, no columnar epithelium, and no increase of fibrous tissue. The thyroid juice was, however, exceptionally fluid, and, even after embedding, very few alveoli retained their contents after mounting.

Sections of the skin are very interesting. They show a remarkable hypertrophy of the papillæ, which project from the surface like polypi. Even along the sides and at the bottom of the natural folds of the skin (which are here exaggerated) the projections can be seen. In connection with these hypertrophied papillæ it is interesting to recall that Mr. F. Gordon Brown showed at the Hunterian Society in 1892 a case of acromegaly with small growths of molluscum fibrosum. The papillæ contain irregular

clumps of pigment, some of which appear to be in the lymphatics and some in the blood-vessels. The epidermis is very thin, probably because it is stretched over the enlarged papillæ; and it is possible that the presence of the pigment in the papillæ rather than in the epithelium of the rete mucosum is due to the scantiness of that layer of cells. The "cutis vera" is thickened.

The small subcutaneous tumours on the abdomen proved to be simple compact fibromata. The skin over them shows the hypertrophied papillæ, and the rete mucosum is here pigmented.

The pituitary body showed no signs of a posterior lobe, and it was very soft. Microscopically it consists of irregularly arranged cells with very little stroma, so that the appearance of a sarcoma is presented. Many of the cells contain two and some of them several nuclei, but over a large area the cells are necrotic and do not stain. There are no signs of cyst formation. Although there is a general resemblance to a sarcoma, both the small and large cells of which the tumour is composed resemble the normal cells of the pituitary body, and such stroma as is seen is in the form of thin, sharply defined lines, more like the stroma of the pituitary body than that of a sarcoma, so that it is quite possible that the true interpretation of the appearances may be that there has been a great multiplication of the normal cells of the organ, followed by their rapid degeneration.

Remarks.—It will be seen that there is an increase of connective tissue only in those organs the epithelial cells of which are degenerating, *e. g.* the pancreas and the kidney. In the liver (where only a few cells are degenerating and many are proliferating), and in the spleen there is no increase of fibrous tissue. That this condition of the liver is not peculiar to the disease, but depends on the stage of the disease, is shown by the fact that in Dr. Dallemagne's case, which I quoted last year, the liver (which was enormous) was cirrhotic, just as the kidney is in my case; so it is quite possible that the liver of my patient would have become cirrhotic in time.

From these considerations it would seem to follow that, in the viscera, the increase of size is primarily due to an increase in the number of the functioning cells. It would also appear that, after a time, the nutrition of these cells cannot be kept up, so that they degenerate, and fibrous tissue grows in the organ.

The increase of the functioning cells should cause an increase of

function during the period which precedes degeneration. In most of the organs an increase of function is difficult to demonstrate, the glands with an internal secretion being excepted; but when degeneration sets in many symptoms would appear.

This would explain some of the anomalies of acromegaly, particularly the variability of the thyroid symptoms. For, while the functioning cells of the thyroid were increasing in number, the symptoms of exophthalmic goitre which have been reported in some cases would be present; and when the cells had degenerated, or were, at any rate, no longer able to make good thyroid juice, the symptoms of myxœdema which have been reported in other cases would ensue. The proliferation of the cells might be so transient, and their degeneration so rapid, that only the symptoms of myxœdema might appear. Or in other cases the degeneration might not take place, so that the symptoms of exophthalmic goitre might persist.

In the present case the thyroid was certainly not growing, as there were no intra-alveolar papillæ such as are found while the gland is enlarging in exophthalmic goitre, and after extirpation of a part of it. More likely it was degenerating, for although the cells stain well, the thyroid juice was exceptionally thin. At any rate certain signs of myxœdema were present.

The glycosuria and albuminuria may be attributed to degeneration of the pancreas and kidney.

I have not referred to the primary cause of the disease, which seems to be due to some changes taking place in the pituitary body, but it would advance our knowledge if we could be certain that the primary effect was a true hypertrophy of the various parts affected, followed at some future time by their degeneration, with or without the development of fibrosis.

November 2nd, 1897.

6. *A case of acromegaly; hypertrophy of pituitary body and thyroid; changes in bone marrow.*

By William Hunter, M.D.

[With Plate VI, fig. 2.]

A. C—, bus driver, aged 52, admitted into Charing Cross Hospital under Dr. Bruce, February 22nd, 1898, for cerebral hæmorrhage; died a few hours later.

Clinical notes.—He had been an out-patient at St. Bartholomew's Hospital since May, 1897, under Dr. Herringham, who has kindly supplied me with his notes of the case at that time.

He then presented appearance of a case of acromegaly, with massive face, nose, lips, and lower jaw, enlargement of hands, and also, though to a less extent, of feet.

He stated he had always had large hands, and had always looked the same; that he had not noticed any gradual change. But a friend who had known him for fifteen years said he had noticed a change in his face during the last five years, and a photograph at the age of thirty-three shown Dr. Herringham presented no abnormality of face at that time.

He came complaining of shortness of breath and sweating, and was found to have a rigid deformed chest with an upper dorsal kyphosis. Sight good; hearing good; thyroid gland could be felt.

From May to December, 1897, he was treated with at first three, then six tabloids daily of pituitary gland substance; subsequently until his death, two months later, with three tabloids of pituitary and three of thyroid gland substance daily.

Autopsy.—Body 5 ft. 9 inches; powerfully built, with massive head and features, especially nose and lower jaw; lips thick and protruding.

Hands massive, broad in metacarpal region; fingers relatively short; skin thick, hypertrophied, thrown into folds; wrist and forearm of natural size.

Lower limbs strongly built; tibiæ thickened at middle third;

feet larger than normal, but no such disparity betwixt size of feet and ankles as betwixt size of hands and wrists.

Chest deformed; upper dorsal kyphosis, projection of lower end of sternum on left side, and of left costal arch. Costal cartilages rigid and ossified.

	Ft.	In.
Height	5	9
Circumference of head around brow . . .		23
Length from forehead to chin . . .		9
„ upper limb		31
„ lower limb (from ant. sup. spine of ilium to heel) .		39
Circumference of chest, upper part . . .		36
„ „ around costal arch . .		39

Organs.—Heart 1 lb. 10 oz. Cavities dilated and walls hypertrophied; mitral and tricuspid orifices dilated, the former admitting three, the latter four fingers. Aortic valves thickened; aorta atheromatous.

Lungs: left 1 lb. 11 oz., right 2 lbs. 2 oz. Chronic bronchitis and emphysema.

Kidneys: left 7 oz., right 12 oz.; both hypertrophied. Slight dilatation of pelves; cortex not diminished; arteries slightly thickened.

Spleen 6 oz.; natural.

Liver 3 lb. 15½ oz.; slightly congested.

Brain: large hæmorrhage right side from outer part of corpus striatum tearing up centrum ovale; right lateral ventricle filled with blood-clot, also third and fourth ventricles; blood also in left lateral ventricle, and in subarachnoid space beneath cerebellum. Arteries at base of brain very atheromatous.

Pons shows a small hæmorrhage, size of a split pea, on left side about middle.

Medulla and *cerebellum* normal.

Changes in pituitary and thyroid bodies and in bones.—Pituitary body: seen from above appeared natural in size; bone around redder than normal; no pressure on nerves; no enlargement of sella turcica; no thickening of infundibulum. After hardening *in situ*, so as to preserve original colour of itself and surrounding bone, it is found on being divided by a mesial vertical section through it and the cavity in which it lies, to be considerably enlarged, filling up the sella turcica, and to present a highly

vascular red appearance contrasting markedly with that presented by the normal body.

Microscopically it shows (1) *extreme vascularity*, all the capillaries betwixt the alveoli as well as the blood-vessels around the capsule being distended with blood.

(2) *Hæmorrhages* (recent in origin) at certain parts, chiefly around the thickened capsule and at the junction of the anterior and posterior lobe.

(3) *Thickening of capsule* with marked distension of veins between it and dura mater. Arteries chronically thickened.

(4) *Glandular substance* increased but normal; cells very distinct. Certain alveoli filled more or less completely with colloid material.

Thyroid gland enlarged, weighing 1½ oz.; firm, red, hypertrophied.

Microscopically: alveoli filled with colloid material, each surrounded by a double or treble row of cells.

Bones.—The following were examined: skull, rib, femur, tibia, fibula, and bones of foot, humerus, radius and ulna, and bones of hand.

The chief changes presented (and preserved in the specimens now in museum, Charing Cross Hospital) are—

(1) *Increased vascularity.*—This is best seen in bones of skull, the inner table of which, as also the diplöe (which, notwithstanding his age, still persists) is markedly red. It is also very obvious in the basi-sphenoid and other bones of base of skull around the pituitary body. Here the redness was obvious even through the dura mater; but the divided bone shows it still more, the marrow being much increased, filling up the spaces and presenting a deep plum-red colour.

Increased vascularity is also seen in bones of foot, in the case of the long bones (femur, tibia, radius, and ulna) being confined to the marrow, in the bones of the foot in the cancellous tissue of the bone.

(2) *Redness of marrow.*—This change in the marrow is, as has been said, very marked in the case of the basi-sphenoid and bones around pituitary body.

Some increase of vascularity is presented by certain parts of the marrow of the femur and tibia, and by the cancellous tissue of tarsus, especially astragalus and os calcis.

Next to the basi-sphenoid the greatest change in this respect is presented by the marrow of the radius, and to a less degree that of ulna. In the radius, as shown in specimen, the marrow of shaft presents a bright red colour, very different from that of the normal.

(3) *Hæmorrhages in marrow.*—Hæmorrhages of considerable size and extent, and apparently of recent origin, are shown in the cancellous tissue of the upper part of tibia, where there is a group of seven or more; also one at lower end of tibia, and in the middle part of shaft of femur.

(4) *Entire absence of changes in periosteum, or in bone tissue proper.*—There is no indication anywhere of any inflammatory change in periosteum or bone proper. Even in the skull where the bone is very vascular the periosteum is normal. Nowhere is there any prominence of bony processes at points of insertion of muscles such as have been described in other cases.

The only bone that shows any local thickening is the tibia, the anterior border of which about its middle shows an old sclerosed thickening of bone, probably an old node.

Summary.—The changes found thus include hypertrophy of pituitary and thyroid bodies, hypertrophy of kidneys; hypertrophy of bones; of head; of hands and feet; of femora and bones of legs; and hypertrophy of skin of hands.

March 15*th*, 1898.

---

7. *Gumma of the pituitary body.*

By William Hunter, M.D.

The specimen exhibited is the pituitary body, in its position within the sella turcica, its relations to the surrounding parts undisturbed, its colour preserved by means of formalin.

It is from a woman aged 47, greatly wasted and cachetic looking, who died from suppression of urine after removal of the right kidney for pyonephrosis, the result of obstruction of the ureter. Admitted into Charing Cross Hospital under the care of Mr. Boyd.

She presented extensive and well-marked syphilitic lesions; in scalp (ulceration), bones of skull (syphilitic periostitis, subperiosteal gummata, ulceration of bone), tibiæ (periosteal nodes showing chronic periostitis, osteitis, and degenerative changes in marrow beneath the nodes), chronic osteo-myelitis, and lastly a mass of gumma in the liver with cicatrisation and deformity of left lobe.

On removing brain the pituitary body was seen enlarged to the size of a small marble, filling up the sella turcica and projecting slightly above level of fossa, of a firm consistence and yellowish colour (infundibulum slightly thickened and fibrous, firmly adherent to the wall of the sella, but not involving any of the adjacent nerves or pressing upon them).

It was left *in situ*, and removed along with the surrounding bone as shown in the specimen.

The right half of the body projected slightly higher than the left. On cutting across the upper portion of this side, the gland presents none of its normal red appearance, but is of a yellowish colour, and is seen to be composed of a tough, thick fibrous capsule of paler colour (forming two fifths of the entire diameter), surrounding a central more yellowish mass of less firm consistence and caseous appearance.

On microscopic examination the posterior part is entirely made up of tough fibro-cellular tissue. The anterior and central part is composed of a mass of small round cells, more fibrous towards the periphery, extremely irregular and misshapen towards the centre where there is a small mass of degenerated caseous material. Hardly a trace of the ordinary acinous structure of this portion is to be detected. Some isolated remains are seen amidst fibro-cellular tissue, or degenerated as in the caseous centre. In sections stained for tubercle bacilli, the outlines of acini completely degenerated can be made out in this caseous area. The appearances presented are those of a granuloma such as is met with in tubercle or syphilis. As regards the former, no giant-cells are to be found, and on suitable staining no tubercle bacilli. On the other hand, the tough fibrous capsule with the central caseous area still more strikingly resembles a gumma; and in view of the other numerous and undoubted manifestations of syphilis presented elsewhere in the body, the gummatous nature of the lesion appears undoubted.

The specimen is in the museum of Charing Cross Hospital.

Remarks.—Gummatous disease of this gland is a very rare con-

dition. Up to 1891 only two cases were recorded, one by Weigert ("Gummiknoten der Hypophysis cerebri," 'Virch. Archiv,' lxv, 1875) and the other by Barbacci ("Gumma Hypophysis Cerebri," 'Lo Sperimentale,' 1891). The only other case since then is that reported by Mr. Beadles twelve months ago before this Society, and recorded in the 'Transactions' for the year 1897, vol. xlviii, p. 1 ("Gummatous Enlargement of Hypophysis Cerebri"). The present case constitutes, then, the fourth recorded.

In Weigert's case, a woman aged sixty-four, the hypophysis was of the size of a hazel-nut, firmly attached to the walls of the sella turcica, and adherent also to the carotid and the vessels and nerves entering the orbital fissure, the bone being eroded.

On section whitish yellow, cloudy, firm area seen in its substance, not sharply defined from the surrounding tissue, irregular in shape, and occupying almost the whole posterior half, while in front they were only found isolated. These grey parts were found microscopically to consist of a connective-tissue stroma richly provided with cells and nuclei; the cells resembling lymph cells, the nuclei small and round. Of the proper alveolar structure of the hypophysis only a few traces near the periphery. Nowhere any giant-cells.

Numerous tubercles with giant-cells were found in pericardium and in liver.

Doubt has been cast (probably on account of this last-mentioned circumstance) on the syphilitic nature of the case described by Weigert. On the other hand, sharply defined syphilitic ulcers were found on the soft palate, and Weigert himself had no doubt as to the syphilitic as distinguished from tubercular nature of the lesion.

The case described by Barbacci was a woman aged forty-one; the central part of the hypophysis was caseous and degenerated, the periphery formed of dense white fibrous tissue, poor in cell elements, while the great bulk of the tumour was composed of round cells and leucocytes. No tubercle bacilli could be found.

This case resembles very closely from its description that just described by myself. In it there was a tumour of syphilitic character connected with the dura mater.

In Mr. Beadle's case, a woman aged forty-one, there was also a syphilitic growth connected with the dura mater (on its inner surface over the cerebellum), and evidence of syphilitic disease of nasal bones

(depression, with necrosis and discharge). The hypophysis was enlarged and harder than natural, and showed on section a central area of uniform colour, composed of a mass of granular amorphous structure with remains of feebly staining nuclei, a thickened capsule of dense fibrous tissue, and an intermediate zone of connective tissue infiltrated with round cells, with a few atrophied remains of the normal acinous structure. At one point he found a single multinucleated giant-cell.

In the case now recorded the evidences of syphilitic disease were more marked than in any yet recorded.

There were no symptoms directly referable to the enlargement. The tumour did not press upon or involve any nerves. The enlargement was considerable: breadth $\frac{5}{8}$ inch, antero-posterior $\frac{4}{8}$ inch, as compared with breadth $\frac{4}{8}$ and length $\frac{7}{8}$ inch in Mr. Beadles' case. The chief alteration was thus in breadth, $\frac{5}{8}$ as compared with the normal $\frac{3}{8}$ inch given by Mr. Beadles. The depth was not ascertained as the tumour has been left *in situ;* but this is also increased, and projects considerably above level of bone.

December 21*st*, 1897.

---

8. *Hæmorrhage into the supra-renal capsules in infants.*

By Geo. F. Still, M.D.

Hæmorrhage into the supra-renals in infancy, although not uncommon in the new-born infant, seems to occur very rarely after the first week of life.

The specimen shown is from a male infant aged 14 months. The child had measles at the beginning of February, 1898, and from that time until his admission into the Hospital for Sick Children, Great Ormond Street, had suffered from cough and wasting. On admission (March 21st) the child was very thin and anæmic, and there was considerable dyspnœa. Examination of the lungs showed

only a poor note at the apices; there was no definite dulness, but there were sharp râles all over the chest.

During the last six days of life there was severe diarrhœa and some vomiting, and during the last two days the dyspnœa increased and the lips were blue. The physical signs were unaltered. There was no abdominal pain and no purpura. The temperature was irregular, only once reaching 103°, usually 99° to 102°. Death occurred on March 26th.

Post mortem there were the usual appearances of acute miliary tuberculosis, almost every organ in the body being affected. The left supra-renal, seen through the peritoneum before it was exposed, appeared bluish purple. After removing the peritoneum the supra-renal was seen to be of a deep purple colour, and distended so that although it preserved its normal shape, it appeared fuller than usual.

On section the whole organ was seen to be engorged with blood, the medulla especially was of a uniform dark purple colour; there seemed to be a uniform infiltration with extravasated blood. The large blood-vessels appeared normal. There were one or two grey tubercles visible in the substance of the supra-renal.

Microscopically the medulla is infiltrated with extravasated blood-corpuscles, but there seems to be no disorganisation of the tissues; the hæmorrhage is nowhere circumscribed. The cortex shows engorgement of the small blood-vessels and some extravasation of blood, but less than in the medulla.

The changes in the supra-renal in this case appear to be exactly the same as those seen in the very acute cases in which purpura in infants is associated with a hæmorrhagic condition of the supra-renal, but clinically it is obvious that the present case belongs to a different group.

So few cases of intense congestion or hæmorrhage in the supra-renals in infants have been recorded, that it seemed worth while to collect the published cases, and add to them some cases that have come under my own notice.

In the records of 3791 autopsies on children under the age of twelve years at the Hospital for Sick Children, Great Ormond Street, there are only four cases of supra-renal hæmorrhage; one of these was in a child aged three years, the others in infants.

Two cases of marked congestion of supra-renals (both unilateral) have occurred recently, one in a child aged eleven years, who died

with acute tuberculosis and ulcerative endocarditis, the other in an infant who died with septicæmia.

The number of published cases is also very small if one excludes stillborn infants, in whom congestion or hæmorrhage of the supra-renals appears to be less rare. (Dr. Spencer in 105 stillborn infants found congestion of one or both supra-renals in thirty-three cases, and hæmorrhage in twenty-three cases.)

In twenty-five children who had lived not more than four days, Dr. Spencer ('Obstet. Trans.,' 1891, vol. xxxiii, p. 256) found congestion in four cases and hæmorrhage in one case.

In addition to these I have only been able to find two cases where congestion was recorded, and seven where hæmorrhage occurred in the supra-renal in infants.

I have thus been able to collect eighteen cases (including the cases from the Hospital for Sick Children shown by myself and by Dr. Batten) in which there was either congestion or hæmorrhage in the supra-renals. In seven of these there was congestion, in eleven cases there was hæmorrhage. Congestion occurred once on the left side and once on the right side only; it was found on both sides in five cases. Hæmorrhage occurred only in the right supra-renal in six cases, in the left in two cases, and in both supra-renals in three cases.

It would seem, therefore, that the lesion is generally unilateral, and that hæmorrhage is much more common in the right supra-renal than in the left.

Of the eighteen cases twelve occurred within the first week of life, and I have only been able to find amongst the published cases two which occurred later, one recorded by Dr. Wainwright in the 'Transactions' of this Society, vol. xliv, p. 137, an infant aged two months, who died with convulsions and empyema, and was found to have traces of old hæmorrhage in both supra-renal capsules. The other, a case recorded by Dr. Voelcker ('Registrar's Reports,' Middlesex Hospital,' 1894, p. 278), in which an infant aged two years died with acute illness and purpura, and was found to have hæmorrhage in both supra-renal capsules.

Clinically the cases seem to fall into three groups:

(1) Those in which death occurred within a few hours or days of birth (never later than the sixth day), *i. e.* cases of congestion or hæmorrhage in the supra-renals in the new-born. These form the largest group (twelve out of eighteen cases). In four of the

twelve cases mentioned supra-renal hæmorrhage appeared to be the immediate cause of death, the capsule being ruptured, and the blood escaping into the peritoneal cavity or surrounding tissues; the symptoms were abdominal pain and collapse.

(2) Those in which death occurred later, and the supra-renal lesion was a complication of some disease, usually of the respiratory tract. In one of the cases recorded here acute tuberculosis, in another severe broncho-pneumonia with septicæmia was the cause of death.

(3) Those in which, after an acute illness lasting only two or three days, usually with a purpuric or bullous eruption, death occurs, and the supra-renal lesion appears to be part of the fatal disease.

The specimen which I have shown this evening seems to belong to the second group; the supra-renal condition is, so to speak, merely an accidental complication of acute miliary tuberculosis.

The causation of the congestion or hæmorrhage is obscure. In every case except that recorded by Dr. Wainwright the hæmorrhage seems to have been quite recent, so that it must have occurred shortly before death.

In a certain number of cases in stillborn infants, and probably also in infants who die within the first week of life, the condition is traumatic, but in a much larger number of cases in Group 1 the condition appears to be asphyxial; delayed respiration at birth produces intense venous congestion, and so hæmorrhage into the naturally lax and highly vascular tissue of the supra-renal in infants. This explanation, however, will hardly account for the cases in which death does not occur till the fifth or sixth day after birth, and it seems possible that some change in the walls of the blood-vessels (such as the acute fatty degeneration described by Buhl and Hecker) may occur in these cases.

In the present case and in others of Group 2, the association with a respiratory disease which produced severe dyspnœa and cyanosis strongly suggests that some of these cases occurring in later infancy may also be asphyxial in origin; but one cannot exclude the possibility of a toxic origin in some of these cases, as, for instance, in those mentioned where the supra-renal lesion occurred as a complication in one case of acute miliary tuberculosis, in another of septicæmia. It may be significant in this connection that severe diarrhœa preceded death in some of the infantile cases

(as in the case I have shown) as well as in adults, and the hæmorrhagic tendency which accompanies severe diarrhœa is familiar in the purpura of gastro-enteritis.

A toxic origin seems almost certain in the third group. Clinically these cases closely resemble the disease described by Henoch as "purpura fulminans," the ætiology of which is unknown, but its toxic nature can hardly be doubted.

That hæmorrhage in the supra-renals may be produced by certain poisons has been shown by Pilliet ('Comptes Rendus de la Soc. de Biol.,' 1894, p. 97), who by giving large doses of essence of cloves to guinea-pigs produced hæmorrhage in the supra-renals; and also by Roger (ibid., p. 52), who found that when Friedländer's bacillus was injected into guinea-pigs, hæmorrhage or acute congestion occurred in the supra-renals, but only in cases where the culture was sufficiently virulent to cause death within about thirty-six hours.

A similar condition was produced by Roux and Yersin in guinea-pigs poisoned by diphtheria toxin, showing that hæmorrhage may be caused by a toxin, although the micro-organism which produced the toxin may not be present in the supra-renal capsules.

Other cases included in the statistics given above are those recorded by (1) Mattei ('Lo Sperimentale,' 1863), one case of intense congestion of both supra-renals in an infant aged six days; (2) Ahlfeld ('Archiv der Heilkunde,' 1870, v), hæmorrhage into both supra-renals in an infant who died with convulsions twenty-four hours after birth; (3) Milroy ('Amer. Journ. Obs.,' July, 1884), hæmorrhage into the right supra-renal in an infant who died fourteen hours after birth; (4) Holt ('Diseases of Infancy and Childhood,' p. 98), hæmorrhage into the right supra-renal and into the peritoneal cavity in a child who died on the fifth day after birth; the labour in this case was particularly noticed to have been "*easy;*" (5) Tuley ('Archives of Pediatrics,' ix, 842), hæmorrhage into the right supra-renal, which had ruptured, in a child aged four days; (6) Hodenpyl ('Proc. New York Path. Soc.,' 1890, p. 167), hæmorrhage into the right supra-renal, which had ruptured, in a child aged three days; the labour in this case is stated to have been "*perfectly normal;*" (7) Prudden (ibid., 1889, p. 92), hæmorrhage into the right supra-renal, which had ruptured, in a child aged five days.

Parrot ('L'athrepsie,' Paris, 1877, p. 356) states that he met with four cases in new-born infants, and says that in three of these there was venous thrombosis, but he gives no details of the cases, and it is not evident whether the infants were born alive; these cases, therefore, are not included in the above statistics. Two cases figured by Rayer in his 'Traité des maladies des reins,' Paris, 1839 (Atlas, pl. lv, figs. 1 and 2, pl. lvi, fig. 2), are omitted for the same reason.

May 3rd, 1898.

---

9. *Hæmorrhage into both supra-renal capsules in an infant aged four months.*

By A. E. Garrod, M.D., and J. H. Drysdale, M.D.

The specimen shown was one of the supra-renal capsules and the adjacent kidney of an unvaccinated female infant, aged 4 months, who was brought to the hospital, dead, on June 4th, 1897. The body, which was well nourished, was covered with a blotchy purpuric eruption. No membrane was found in the pharynx, larynx, or trachea. The thymus was large, the thyroid natural. There was no disease of either middle ear, and no tubercle was found in any part of the body. The brain, lungs, heart, liver, and spleen appeared natural. There were no swellings around joints or bones.

Both supra-renal capsules had a deep purple-red colour, but were not obviously increased in size. On section the cortex had a deep red colour throughout, and the medulla showed a deep purple tint. The discoloration was uniform throughout both capsules, and no circumscribed hæmorrhages were seen on the surface of, or around the glands.

On microscopic examination the stroma was seen to be fairly well preserved, so that it was easy to distinguish between the medulla and cortex. The cells of the gland enclosed in the meshes of the stroma had in large part disappeared, and their place was taken by effused blood. Some of the individual spaces contained

no epithelial cells at all, but were instead completely filled with red blood-corpuscles. In other parts glandular cells could be seen in considerable numbers, the nuclei of which stained well but the cell substance appeared to be partly destroyed. Cultures from the spleen, kidneys, liver, and supra-renal capsule all remained sterile.

Both in the clinical and pathological features the case very closely resembled that described by Dr. Andrewes at page 259 of this volume.

May 3rd, 1898.

---

10. *Hæmorrhage into the supra-renal capsule.*

By F. E. Batten, M.D.

The specimen was taken from a boy aged 2½ years, who had attended the out-patient department of the Hospital for Sick Children, Great Ormond Street, for lichen urticatus for one month.

On February 14th he was taken ill at 9 a.m. with vomiting and diarrhœa; this continued during the day and following night; the child was feverish, but complained of no definite pain. On the morning of February 15th he was brought to the hospital, but was not admitted as the onset of scarlet fever was feared. At noon of the same day the mother again brought the child as he had had a convulsion and was still convulsed.

On admission the child was comatose, pulse 200; respiration Cheyne-Stokes in character; temperature 102° F. He had frequent convulsive attacks, the arms and legs being rigid. There was strabismus, but no fundus change. There was some staining of the skin, probably due to the rash, from which he had suffered for some time. There were some bronchitic sounds all over the chest. The heart was acting very rapidly, but otherwise appeared normal. The knee-jerks were marked, and there was a tendency to ankle-clonus. The temperature rapidly rose to 106° F., and the child died eight hours after admission.

The *post-mortem*, made sixteen hours after death, showed two or three small extravasations on the floor of the lateral ventricles of the brain; the lower lobes of the lungs were much congested. All the other organs of the body appeared normal except the right

supra-renal, which was larger than the left and of a dark purple colour. On microscopical section it was found that the whole body was extremely congested, extravasation of blood having taken place into the medullary portion of the organ. The left supra-renal appeared to be perfectly normal.

May 3rd, 1898.

---

11. *Hæmorrhage into the supra-renal capsule.*

By F. W. Andrewes, M.D.

Florence G—, aged 15 months; living in Cloth Fair; unvaccinated. Taken ill July 22nd. Hæmorrhagic rash July 23rd, at 10 a.m. Brought to hospital at 11 a.m.; febrile, papules on chest; not taken in for fear of smallpox. Died suddenly that night. Total duration of illness less than two days.

Post-mortem (July 24th, from notes by Dr. Batten).—Well nourished. Covered with a purpuric eruption. A few small papules on chest (proved to be early stage of molluscum contagiosum). Brain, throat, and practically all viscera (except supra-renals) normal. Glands of neck noted as somewhat swollen. A few purpuric spots on the parietal pleura. Spleen normal.

Supra-renals symmetrically affected; not enlarged or altered in shape; dark red in colour, as if hæmorrhage had taken place into them.

No other morbid changes could be discovered.

The specimen has been preserved by the formalin method, and shows well the hæmorrhagic character of the lesion. The entire organ is uniformly affected, and both supra-renals were identical in appearance.

Cultures were taken from the supra-renals, lungs, liver, spleen, and kidney. All remained sterile. Films of blood expressed from the supra-renal and stained in various ways for micro-organisms gave entirely negative results.

Microscopic examination of the supra-renal, lung, liver, kidney, and spleen was carefully carried out, various methods of staining being employed. In no organ could micro-organisms be detected. The changes found were trifling—slight cloudy swelling in the

kidney and liver, and some congestion of the lung and spleen. The supra-renal shows a fairly uniform diffuse extravasation of blood, the proper tissue elements being obscured and apparently diminished in number.

Conclusions.—The history points to an acute toxæmia, presumably infective in character. Food poisoning cannot be excluded, but seems highly improbable.

Streptococcus septicæmia, which might have been a possible explanation in view of the hæmorrhages, can be certainly excluded by the complete bacteriological examination. Assuming that it is an infective process, it must have been by some organism which will not stain by ordinary methods or grow on ordinary media. Variola at once suggests itself, especially as the child was unvaccinated, and in fact the case was notified as probably such. Against this is the fact that there was no known source of infection from smallpox, and that no cases arose subsequently in connection with it. It nevertheless appears to me the least unlikely explanation of the condition. I am not aware, however, that the supra-renal lesion has been described in hæmorrhagic variola; nor indeed does the condition appear to have been described in any connection at all. Those who have worked at experimental diphtheria are familiar enough with the appearances of the supra-renals in guinea-pigs dead of diphtheria, which commonly show enlargement and intense congestion, or even actual hæmorrhage. This is the nearest approach I have seen to the condition of the supra-renals in the above case, and is some argument in favour of the infective nature of the disease, though here there is no question of diphtheria.

---

12. *Tumour of the supra-renal body.* (*Card specimen.*)

By Cecil F. Beadles.

Attached to the upper extremity of the left kidney by its capsule and embedded in a mass of fat is a small tumour three-quarters of an inch in diameter, intensely hard as though calcareous. It can be cut with a knife with some difficulty, when

it is found to be gritty, and the section to present a hard, white, fibrous appearance. Dissection amongst the fat disclosed no trace of a supra-renal body apart from the growth.

The minute structure of the growth is somewhat peculiar. Bands of swollen hyaline material run in all directions, and compose the larger part of the neoplasm. This degenerated tissue is amorphous, having but very slight traces of nuclei discernible, and it takes up logwood stain very unevenly, a large part remaining entirely uncoloured. Some of these bands, however, contain clusters of minute refractive spherules, for the most part only seen with a high power objective, probably of a calcareous nature, for scattered about are larger masses formed by the fusion of similar particles, which in places form white gritty masses visible to the naked eye. Compressed between the hyaline bands are groups of flattened and spheroidal-shaped cells, the former of which seem to line capillary spaces; as to the latter, which are smaller than normal adrenal cells, it is difficult to say if they are merely connective-tissue cells or whether they are newly-formed epithelial cells, or represent simply the atrophied remains of the natural supra-renal cells. Blood-vessels are scarce throughout the tumour.

Both kidneys were a little enlarged, their capsules adherent. The pelvis of the left was filled with fat, and the ureter and artery were slightly dilated. Sections of this kidney show a condition of chronic interstitial inflammation. There is increase of the intervening stroma with marked round-celled infiltration in places; the renal cells in parts atrophied, in others swollen and granular.

From a female lunatic aged 70, with senile mania of six years' duration. During the last year of her life she was quite demented, and had a fine senile tremor, was in very feeble health, and was constantly in bed for some days at a time. She gradually sank from senile decay. There were no signs pointing to a lesion of the supra-renal body.

Dr. Rolleston, after examining sections of the growth, inclines to a diagnosis of fibro-adenoma in which the fibrous tissue has undergone hyaline degeneration as well as calcification. He believes that glandular elements of the supra-renal lie compressed amongst the connective tissue. On the other hand, Dr. Lawrence, who has placed the specimen in University College Museum, suggests

that the tumour is unconnected with the supra-renal, but has its connection with the renal capsule, and would class it as a fibroma.

December 7th, 1897.

---

13. *Myxœdema: a report on three fatal cases, one of them associated with trichinosis.*

By Cecil F. Beadles.

[With Plate VIII.]

Strange to say, myxœdema has received but scant notice by this Society; in fact, the disease may be said to have been entirely passed over, and work which one would have thought might well have been carried out by the leading pathological society of the kingdom has been undertaken by others.

As is universally known, the Clinical Society has the credit not only of firmly establishing the existence of myxœdema as a distinct disease, but of elucidating the leading facts in the morbid anatomy and pathology of the affection.[1] Further, while important papers bearing on these points have since appeared from time to time in the reports of other societies and in various medical journals, the 'Transactions' of the Pathological Society of London are almost void of any reference to the subject.[2] This unfortunate oversight is past remedying, although in the present communication, while referring to several special points and others of peculiar coincidence, I shall touch upon many features now quite familiar and known to all pathologists.

During the six years 1892 to 1897 three persons affected with myxœdema have died while inmates of Colney Hatch Asylum.[3]

[1] 'Report of a Committee of the Clinical Society of London to investigate the subject of Myxœdema,' 1888.

[2] The following appear to be the only references:—"Malignant Disease of Thyroid from a Case of Myxœdema," vol. xxxvii, 1886, p. 511; "A Larynx from Myxœdema Female Patient," vol. xli, 1890, p. 32; "A Case of Myxœdema associated with Tubercular Disease of the Lungs and Larynx," vol. xliii, 1892, p. 184.

[3] In looking over the old post-mortem books of this asylum, two cases were

A detailed description of the *post-mortem* lesions found, together with an histological examination of the tissues in the first case, has been published in conjunction with Prof. Boyce,[1] and the following communication dealing with the others may be considered to a certain extent as a continuation of the former paper. As I shall have occasion to remark on some points in that case of L. D—, in order to compare them with the two later cases of myxœdema, I propose to refer to the former as Case 1, and to the additional subjects as Case 2 and Case 3.

CASE 2.—*History.*—M. S— (female, 10,984). A single woman who had been an inmate of Colney Hatch Asylum since December, 1890, of weak intellect, with aural hallucinations, optical delusions and others of suspicion, complained of noises in her head, was noisy and restless in behaviour. It was not until the middle of the year 1892 that it was hinted that she was suffering from early myxœdema. For several months an advanced case[2] of that disease had been under treatment with an extract of the thyroid gland; it was now suggested that the effect of the thyroid should be tried upon this patient, and this treatment was accordingly commenced in October of that year. During the preceding three or four months it had been noticed that her features had gradually assumed a rather more thickened aspect, and that her voice was distinctly more husky and monotonous in character. She was becoming more languid and slower in her movements, and she suffered much from cold, always being worse when the day was chilly. Her temperature was found to be seldom above 97°.

She was given a raw gland, minced in the form of sandwiches, at intervals of one and then two days for a period of six weeks, on eight occasions in all. The administration was then stopped owing to the grave symptoms that had followed, there being loss of consciousness with violent pain in the abdomen on the last three occasions. The patient lost two stone in weight during this short course of treatment. Towards the end of November it is noted

found which would seem to be cases of myxœdema (both females); but the notes are too scanty for any interest to be attached to them.

[1] "Enlargement of the Hypophysis Cerebri in Myxœdema; with Remarks upon Hypertrophy of the Hypophysis associated with Changes in the Thyroid Body," 'Journ. Path. and Bact.,' vol. i, pp. 223 and 359.

[2] Case 3.

that a considerable improvement both mentally and physically had followed, and this continued till May, 1893, when the patient was in very good health. She then showed slight signs of myxœdema, but to a less degree than in the previous October. Her mind was clear, she was feeling well, usefully employed, gaining weight, and much new hair now took the place of what before was scanty and thin.

In June an abscess on the leg was opened, and healed well. Continuing much the same up to January, 1894, it is noted that her myxœdematous symptoms were still less than they were two years before. Between November, 1892, to within a few days of her death she had taken small doses of a thyroid extract in powders at irregular intervals, but never more than three grains twice a week, occasionally skipping a week or perhaps more.

The patient died on September 6th, 1894, aged forty-six. She had only kept her bed a few days for what seemed to be general weakness with signs of cardiac feebleness. There was no rise of temperature suggesting inflammatory disease.

Autopsy.—The body, which was well nourished, inclining to stout, was by no means very characteristic of myxœdema, and would scarcely have been recognised as a case of that disease. There was no marked blunting or thickening of the features, and although the skin was unusually pale, white, and a little rough, there was but little sign of œdematous swelling. The hair on the head was thick and healthy in appearance, and existed in other usual regions of the body.

Fat was in excess both on the thoracic and abdominal parietes, but was of normal colour. The retro-peritoneal fat was also increased in amount, and this was inclined to be gelatinous.

Muscles that were seen had a rather paler tint than natural. The tongue was not particularly large. The mucous membrane of the larynx and œsophagus was congested.

Heart was neither hypertrophied nor dilated, but contained a great excess of fat on its exterior. This was of a yellow colour, more or less spread over the whole organ, but accumulated about the base and right ventricle. The myocardium was of a dark colour and soft; the endocardium and valves were deeply stained, but the latter were healthy. There was a very slight change in the intima of the aorta above the valve. A considerable amount of serous fluid surrounded the heart in the pericardial cavity,

Lungs: the left was firmly adherent to the chest wall. The upper lobe on both sides was puckered at the apex, and almost solid throughout. In each were several small hard nodules, which on section proved to be due to a ring of dense tissue surrounding a small cavity containing cheesy material; these were suggestive of dilated bronchi or quiescent tubercle. The lower lobes were healthy, with no sign of œdema.

Stomach and *intestines* greatly inflated, and the peritoneal covering congested, though presenting no sign of inflammation. The peritoneal cavity contained some serous fluid.

Liver of large size, flattened out, pale, soft, and fatty. There were no gall-stones.

Kidneys were both enlarged, the right to the greater extent. Their cut surfaces presented a pale waxy look, and their cortices were diminished in width. The capsules were a little adherent, and on removal left a slightly granular surface.

The *supra-renal bodies* appeared to be almost entirely converted into adipose tissue.

Spleen of fair size, dark and firm on section.

Uterus was small and healthy, except for a small polypus springing from the cervical canal and projecting from the os. *Ovaries* small and healthy. *Bladder* healthy.

Head: nothing abnormal to note about the calvaria or membranes of the brain, but there was some excess of fluid within the skull. The pia mater was, perhaps, a little thickened and slightly congested. The *brain* was well developed but bloodless, and its consistency putty-like. The ventricles were not dilated. There was no sign of hæmorrhage, old or recent, and the vessels at the base were healthy. The base of the skull was natural, and the pituitary fossa was not enlarged.

The *hypophysis cerebri* became detached on removing the brain; it was not appreciably enlarged, and did not protrude above the fossa. On removal it was found well developed, with distinctly marked posterior lobe. It weighed 13 grains (·844 gramme).

Thyroid gland greatly reduced in size, and owing to its extremely pale colour, and that of the muscles covering it, was with difficulty recognised. It retained its normal shape, but was soft with a few harder areas. There were a number of small hard nodules, size of a split pea or less, extending down either side of the trachea, and

connected with the thyroid by thin fibrous bands, which seemed not unlike accessory thyroid tissue.

The weights of the organs were—

Brain	41½ oz.
Heart	10¼ „
Lung, right . . .	17¾ „
„ left . . .	17¼ „
Liver	67½ „
Kidney, right . . .	6 „
„ left . . .	5¾ „
Spleen	6¼ „

CASE 3.—*History.*—M. B— (female, 11,460). Notes of this case have already been published on two separate occasions; in the 'Brit. Med. Journ.,' December 24th, 1892, the early results of thyroid feeding were given, and in a more extensive paper in the 'Journ. Ment. Sc.,' the further result of that treatment, together with photographs of the patient, appeared.[1] The condition of the patient up to that date and since may be briefly summarised as follows:

She was received into Colney Hatch Asylum in April, 1892, from St. Marylebone Infirmary, when in an advanced state of myxœdema, supposed to have commenced eight years before. Insanity took the form of religious melancholia, and had existed four and a half years. Her mental powers were greatly in abeyance, her memory a blank, all special senses exceedingly blunted. She was in a heavy drowsy condition, bordering upon a demented state. Skin thick, coarse, and scaly; features puffy and œdematous; hair thin and scanty on the head and other parts of the body; hands and feet swollen; speech slow and thickened; movements slow; temperature subnormal, namely, 95·2°; pulse 56.

For three months she was subjected to hypodermic injections of thyroid extract. By the end of that period she had so much altered both in her mental and physical condition as to lead one to hope that she would become practically cured, not only of her myxœdematous disease, but also of her mental symptoms. But during the whole period of treatment she had complained severely of acute pain felt in both her wrists, which had been somewhat

[1] "The Treatment of Myxœdema and Cretinism: being a review of the treatment of these diseases with the thyroid gland; with a table of 100 published cases," 'Journ. Ment. Sc.,' July and Oct., 1893.

DESCRIPTION OF PLATE VIII.

Illustrating Mr. Cecil F. Beadles' paper on "Myxœdema: a report on three fatal cases, one of them associated with trichinosis." (Page 262.)

These figures, reproduced in collotype from photographs, illustrate some of the microscopical conditions observed in the three cases of myxœdema. Fig. 4 is a low power (Swift, obj. $\frac{2}{3}$ in.). The remaining figures are under a high power, and of equal magnification (Swift, obj. $\frac{1}{6}$ in.).

FIG. 1.—Thyroid gland from Case 3. Edge of layer deeply staining cellular area. There are small groups of atrophied epithelium scattered amongst lymphoid-like tissue.

FIG. 2.—Pituitary body from Case 2. Anterior part of glandular lobe' showing scattered thyroid-like vesicles filled with colloid.

FIG. 3.—Cardiac wall from Case 3. Section from right ventricle, showing the following degenerative changes: wide displacement of muscle tissue by fat cells and œdematous connective tissue, vacuolation of fat-cell nuclei (although one only is clearly seen there are at least four such nuclei in the area figured), separation of individual cardiac muscle cells by a colourless ground substance.

FIG. 4.—Lung tissue from Case 1. Great thickening of capillary and small artery walls. The new tissue has undergone a hyaline degeneration, and occlusion of the lumen has occurred.

FIG. 5.—Lung tissue from Case 1. An air alveolus filled with a fibro-hyaline deposit.

FIG. 6.—Lung tissue from Case 1. A small dense hyaline deposit occupying an air alveolus. This is one of the so-called cartilage-like masses, the majority of which were of somewhat larger size and spread into several alveolar spaces.

Fig. 1

Fig. 2

Fig. 3

Fig. 4

[illegible] PLATE [illegible]

[illegible] paper [illegible] cases [illegible] of them associated [illegible]

[illegible] from photograph [illegible] observed in the three [illegible] Swift, [illegible] The [illegible] (Swift, [illegible])

[illegible] from Case 3. [illegible] small groups of [illegible] with [illegible]

[illegible] from Case 2. Anterior [illegible] vessels filled with [illegible]

[illegible] from Case 3. Section from right [illegible] changes [illegible] displacement of [illegible] connective tissue, vacuolation of [illegible] clearly seen there [illegible] at least [illegible] in the [illegible] of individual cardiac muscle [illegible]

[illegible] from Case 1. Great thickening of [illegible] The new tissue has undergone a hyaline [illegible] the lumen has occurred.

Fig. 5.—Lung tissue from Case 1. An [illegible] with [illegible]

Fig. 6.—Lung tissue from Case 1. A small [illegible] lying an air alveolus. This is one of the so-called [illegible] the majority of which were of somewhat larger [illegible] alveolar spaces.

Fig. 1.



Fig. 2.

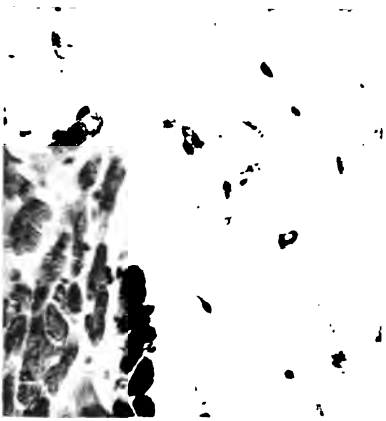

Fig. 3.



Fig. 4.

Fig. 5.

Fig. 6.

deformed for some years, as though from chronic rheumatoid arthritis. The pain was felt shortly after the injections, and was so severe that the patient always implored that they might be discontinued. Treatment entirely ceased for five months, and before the end of that period the patient had greatly digressed both mentally and bodily, although not quite to so unsatisfactory a stage as was present before the injections were commenced. Then thyroid powders were taken for a time, and improvement reached pretty much the same degree as it did before. Again the arthritic pains were felt, such pain being of a severe form and felt during the greater part of the day on which the drug was taken. The wrists had remained permanently enlarged and deformed.

For some months before the close of life, which took place June 24th, 1897, thyroid extract had been left off. The patient had developed into a completely demented state, with an appearance of most advanced myxœdema. Not leaving her bed, she slept continuously throughout the day, only waking up to take some food. She passed away, aged fifty-four, without the occurrence of any other special change. It may be mentioned that before, and frequently during the treatment, the urine was examined and no albumen found. The catamenia did not reappear, and there was no metrorrhagia. Much of the hair, which had grown to a remarkable extent, fell out again during the last few months of her life.

Autopsy.—Body very obese, weighing between 11 and 12 stone; height 5 feet 4 inches.

The face presented a characteristic appearance of advanced myxœdema; features blunted and swollen, eyelids œdematous, nose broad and thick, alæ thickened, lips swollen, the upper being broadened. Hands swollen, nails short (cut), fingers broad and stumpy, wrists deformed. Feet presented a swollen appearance, but not pitting on pressure; skin of soles especially thick. Labia swollen.

Skin over the whole body pale and sallow in tint, thick and tough, small cracks and flakes on the surface. No warts except one on the face.

Hair scanty over the upper part of the scalp, but fairly abundant over other parts of the head; almost absent from eyebrows and eyelashes, completely gone from axillæ, very scanty on the pubes; none over the rest of the body, but a few downy hairs on the upper lip.

Fat in considerable amount subcutaneously beneath the peritoneum and around the abdominal viscera; on the abdominal wall it was $\frac{3}{4}$ inch thick. Throughout it was of a peculiar pale gelatinous character.

Muscles of a pale pink tint, and seemed generally atrophied.

Bones, judged by the ribs, were soft and easily cut. All the serous cavities contained an excess of straw-coloured fluid.

The *tongue* was pale, large, and swollen, measuring $5\frac{1}{2}$ inches in length and $3\frac{1}{2}$ inches in breadth. Larynx, trachea, and œsophagus presented no sign of abnormality except that they were pale in colour.

Thymus represented only by fat.

Heart much enlarged from dilatation, more particularly of the ventricles. A considerable amount of pale gelatinous fat surrounded the organ. Muscular tissue exceedingly pale, and fatty tissue replaced a large part of the myocardium, especially of the ventricles and more particularly at the apex. Organ 5 inches long. Auriculo-ventricular orifices dilated, the valve flaps thickened, and some thickening also of the aortic cusps. There was slight yellowness in patches on the intima of the aorta.

Lungs not adherent to the chest wall; they presented a swollen œdematous aspect, filled with frothy fluid, and had a dark mottled appearance. There was no consolidation, and no part of either organ sank in water. No sign of tubercular disease existed.

Stomach distended, wall thinned, with a little congestion of the mucous membrane in places towards the pyloric end. On the anterior wall towards the fundus of the organ a small, hard, nodular growth the size of a pea projected on the inner lining, and was found to be firmly fixed and blended with the muscle wall, but not with the mucous membrane, the latter readily slipping over it and having but loose attachment.

Intestines pale and flatulent.

Liver large, well formed, nutmegish on section; no gall-stones present.

Left kidney a little enlarged, length $4\frac{1}{8}$ inches, very pale on section, and fatty throughout. Surface granular, and capsule adherent in places. There was one small area of adipose tissue below the surface of the capsule presenting the form of an infarct.

Right kidney rather smaller, length $3\frac{7}{8}$ inches, with a granular surface. One end of the organ was pale, the other had streaks of

congestion at the outer edge of the pyramids; cortex narrow throughout.

Spleen large, firm, and dark, with some white opaque thickenings on the capsule.

Bladder had hypertrophied walls, its lining pale; no signs of cystitis.

Uterus of normal size. A fibroid the size of a hazel-nut existed in the posterior wall of its body. There was slight chronic congestion of the lining membrane of the body, and some thick glairy mucus in the cervical canal.

Right ovary converted into a blood-cyst the size of a Tangerine orange, being filled with dark, reddish-brown, semi-solid blood-clot.

Left ovary rather smaller than natural.

Head.—Calvaria of yellowish tint, rather thinner than natural, but dense and heavy; smooth on the inside, with no projections or pits to speak of. The portion of bone as usually removed [1] weighed 12 oz. Nothing peculiar about the skull bones or the fossæ at the base. Only a little cerebro-spinal fluid present. Dura mater normal. Pia arachnoid thin; there was capillary congestion over the upper surface, but the larger vessels were not distended. Arteries at the base seemed fairly healthy. On the outer side of the right frontal lobe was a thin layer of blood-clot beneath the arachnoid of about 2 inches in diameter, extending to the lower edge of the lobe.

Brain well formed and of good size; convolutions not atrophied; very pale and rather soft throughout; ventricles not dilated. No localised softening or hæmorrhage anywhere within the brain.

Pituitary body did not seem to be appreciably enlarged while *in situ*, and no displacement of the bone existed, the fossa being of about normal size. On removal of the gland, however, it was found to project a little forward, and was then seen to be a trifle larger than the average-sized gland. It weighed while fresh 12 grains (·779 gramme). It had a healthy appearance.

Thyroid gland.—On account of the pale and atrophied condition of the thyroid and laryngeal muscles, and of the gland itself, the thyroid was found and dissected out with great difficulty. The true isthmus of the gland appeared entirely absent, the lobes being united together only by a thin band of connective tissue of whitish

[1] See 'Edin. Med. Journ.,' March, 1898, "The Cranium of the Insane."

colour ¼ inch in width. The lobes, presenting a pyramidal shape, were reduced in size, very soft, and of a pale tint. The right measured 1½ inches long, ⅞ inch broad, 1 inch thick; the left 1½ inches long, ⅝ inch broad, ⅞ inch thick. By the thickness is meant that at the outer and lower part, for on the laryngeal aspect the anterior and posterior surfaces tapered to a sharp angle, giving each lobe a wedge-shaped form.

This gland is distinctly larger, and does not appear to be anything like so atrophied as that of the case just described or of the one from the patient L. D—. Especially does this seem so after the organ has been some time in formalin solution, by which the tissues have become hardened. The change that is thus brought about is doubtless due to the fact that this reagent has more hardening effect on fibrous tissue than it has upon glandular and muscle tissue. Moreover, it will be seen later on that notwithstanding the apparent size of the thyroid gland, but little of the glandular tissue of the organ exists, it having been replaced by connective tissue.

The weights of the organs were:

Brain	48 oz.
Heart	15 „
Lung, right . . .	26 „
„ left . . .	28¾ „
Liver	57 „
Kidney, right . . .	3½ „
„ left . . .	4½ „
Spleen	4 „

Histology of the tissues and organs from Case 2.—The tissues were hardened in Müller's solution and the sections cut with the freezing microtome in gum, and stained with logwood.

Skin.—There is some increase in the amount of the horny layers of the cuticle, which is swollen, and the superficial layers are separating. Young connective tissue binds the tubules of the sweat glands together; the latter seem healthy, as do likewise the hairs.

The *subcutaneous tissue* is of a loose œdematous character. The fat-cells are normal in size; some of their nuclei are large, and contain vacuoles.

Muscle-fibres of the pectoralis major appear healthy, their stria-

tion about normal. There is a little loose connective tissue between some of the fibres.

Subcutaneous *nerves* have a rather swollen aspect.

Heart.—The pericardium consists of a thick layer of loose connective tissue with much fat. The cells of the latter are of normal size, many of their nuclei vacuolated. At one place immediately beneath the surface is a small collection of round cells. The endocardium is thin, and close upon the muscular tissue. The myocardium is made up of fair-sized bundles of muscle fibres, these being fairly healthy in appearance, though many of the nuclei seem exceptionally large. Several small collections of round cells exist amongst the fibres.

Lungs.—These show less of the peculiar change affecting the coats of arterioles in the alveolar septa than was observed in the case of L. D—; the walls of the vessels are not as thick, and bulbous-like projections into the air-cells only exist to a very modified degree. This is probably due to the fact that here the disease was in a much earlier stage. The capillaries of alveoli are engorged with blood. There are a few small hyaline bodies projecting into the air-spaces. One or two small cartilaginous-like masses are seen which apparently occupy distended air-cells. One of these, which seems to be imperfectly formed hyaline cartilage, and quite independent of a bronchial tube, has a deeply staining external part, and the centre composed of pale hyaline material in which are embedded irregular connective-tissue corpuscles. These peculiar masses are far less frequent, though as closely simulating cartilaginous tissue as in the previously recorded case.

Sections from one part of the lung show a definite pneumonic condition, there being intra-alveolar exudation with blood extravasation. Other sections exhibit unmistakable tubercular disease; this is of a chronic nature, with fibrous growth combined with tubercles containing giant-cells. A hard nodule that was excised is formed by a patch of fibrous consolidation surrounding a small breaking-down tubercular nodule with a number of typical giant-cells on the outskirts of the necrotic tissue.

Liver.—There is increased nucleation of Glisson's capsules. The bile-ducts and vessels contain amorphous material. Immediately around these the hepatic cells are swollen and their nuclei have not stained, or only indistinctly; further away at the periphery of the lobules the cells are clear, contain much pigment, and are

breaking down; their nuclei stain deeply, but vary greatly in size, a large number being considerably swollen, and having one or two pale colourless spherules (vacuoles) in their interior. A number of these cells are represented only by a large vacuole with a ring of fine pigment granules around. Only here and there are the capillary spaces distended.

In a section from another part of the organ a large portion of the hepatic cells are shrunken, and their place occupied by a fibrinous groundwork with capillaries.

Kidneys.—The most marked change here is an increased nucleation in the interstitial tissue immediately beneath the capsule. There is also sign of chronic interstitial nephritis about the cortex, as shown by small areas of connective tissue and increase of the connective-tissue nuclei in the glomeruli. Throughout a large part of the renal tubules the epithelium is swollen, stains badly, and their nuclei are not visible; those that do stain do so indifferently.

Spleen.—Vessels thick-walled and almost occluded. No abnormality noticed about the lymphoid tissue.

Brain.—Sections from the motor area of the cortex show some distension of the lymphatic spaces, some of which are filled with colloid. A number of the perivascular spaces contain pigment granules.

Pituitary body.—Throughout the whole of the anterior lobe there is increased activity manifest, as shown by the formation of thyroid-like vesicles containing colloid matter and groups of larger cells, some of which are more highly stained than others, although these changes are not so marked as in the case of L. D—.

Scattered more or less all over the lobe, but numerous in some parts, are small spaces lined by a layer of cubical epithelium, or irregularly by several layers with colloid within. This condition is perhaps most marked towards the lower part of the lobe, but it is also noticeably increased at the extreme tapering tip of the lobe. Along the boundary zone there is pronounced cystic development, such as is seldom seen except in glandular hypertrophy of the pituitary; one large somewhat triangular space with its base below occupies the lower two thirds of the zone; it is filled with colloid, and is in part lined by an even layer of cubical cells and partly by a mere heaping up of spheroidal cells; in addition some polypoidal growths project into it. Above this are a number of smaller cysts filled with colloid material.

In the capsule both above the anterior and posterior lobes are groups of particularly deeply staining epithelial cells.

The stroma for the most part is scanty; in places it contains colloid.

The small blood-vessels are filled with blood, and show no change in their walls.

The posterior lobe is well developed, and is composed of young connective tissue. There are few blood-vessels and no pigment present. Colloid-like material is scattered about, and not confined to distinct spaces. The fibrous tissue of the capsule and peduncle is of a hyaline nature, and the same character is observed in the wall of arterioles.

Thyroid gland.—This has on section the characteristic appearance of that in myxœdema. There are localised round areas varying in size from mere specks to others of about $\frac{1}{8}$ inch across, which appear as deeply stained sites to the naked eye. The rest of the section is made up of a large amount of fibrous tissue, dense, and more or less hyaline in character. Of the few fat cells present many have a vacuolated nucleus. A number of small vessels exist; the arterioles have thickened walls, some being almost occluded. The deeply stained areas consist of small round cells and young connective-tissue nuclei, with many engorged capillary vessels. In the larger ones there is seemingly both atrophy and compensatory hypertrophy of the epithelial elements. Small thyroidal vessels exist surrounded by one or more layers of cells, and filled most often with a watery form of colloid. These are embedded in a mass of epithelial cells, some apparently more or less filling vesicular spaces, others heaped together irregularly with an occasional spherule of colloid. In places, especially at the circumference of the area, is an infiltration of deeply staining small round cells. In the smaller areas where the epithelium has entirely disappeared, the round cells are giving place to elongated connective-tissue cells, which in their turn are becoming converted into fibrous tissue.

A little mass, thought perhaps to be accessory thyroid tissue, is found to be composed solely of lymphoid tissue.

Compared with the thyroid of L. D— there is more glandular tissue remaining, the lymphoid follicles are more numerous, there are not so many large blood-vessels, but what arteries there are show less thickening of their walls.

Histology of the tissues and organs from Case 3.—The hardening agents used were alcohol, Müller's fluid, and formalin solution. The tissues were cut by the freezing method, and the sections stained with logwood.

Skin.—This was examined from the neck and over the chest.

The *epidermis* presents a degenerated appearance, the deeper layers narrow and deeply staining, but with faint indication of individual cells; the superficial layers consist of faint colourless flakes without visible nuclei, easily detachable, with some flattened cells caught in a tangled mass on the surface.

The connective tissue of the *cutis* is formed of loosely arranged bundles of fibrous tissue, except close around the air-follicles, where there is a dense fibrous layer. Immediately beneath the epidermis the stroma is of a fine fibrillated nature, with a granular appearance from breaking up of the fibres. Small blood-vessels stand out prominently owing to the deep staining of involuntary muscle-fibre tissue, a point observable throughout myxœdematous tissue. The erector pili muscles stain in the same deep manner.

Hairs are in a degenerated state, breaking down into fibrils, and the follicles at their upper part and orifice are surrounded by an increase of scaly horny cells.

The *subcutaneous tissue* is composed of loose bundles and single fibres of fibrous tissue, which are largely split up into their component fibrillæ.

Fat cells vary a great deal in size; on the whole they are rather large. The nuclei of many of the cells are of particularly large size, and a considerable proportion of them are vacuolated; that is to say, there is a round colourless spherule within them, almost invariably only one, which is more often than not situated towards the centre of the nucleus. It does not appear that other connective-tissue nuclei have this vacuolated condition, at least to any extent, though I have seen a few nuclei of cells which do not seem to belong to fat cells, which show indications of the condition. Nuclei of other tissues are entirely free from it.

Voluntary muscles examined were the left pectoralis major and left and right sterno-thyroid. The fibres invariably stain deeply; for the most part they seem quite healthy, though a few have a marked granular appearance. The cross-striation is usually very beautifully seen with a $\frac{1}{8}$ inch objective. The muscle-fibre nuclei stain deeply, and in places seem to be increased in number. Fat

cells intervening between the muscle fibres are of normal size; the intra-cellular contents has taken up stain, and is often collected to one side; many of the nuclei are vacuolated.

The muscle fibres of the right sterno-thyroid are separated into small bundles or singly by loose connective tissue and fat cells. The fibres vary much in size; the nuclei are exceedingly numerous in some places, and lie on the fibres in clusters or in long strings. In some parts a distinct round-celled infiltration exists amongst the muscle fibres, showing the existence of inflammation.

Nerves.—Small nerve bundles lying amongst muscle tissue show a loose arrangement of the nerve fibres. The outer sheath in some is distended, a considerable space intervening between it and the fibres within the space being occupied by colloid-like material. Transverse sections of the trunk of the hypoglossal nerve show a similar condition; the individual component fibres are mostly separated from each other by colourless ground substance.

Small arteries associated with the muscles have their muscular and fibrous coats thickened to a slight degree, but there is no marked hyaline change in them.

Heart.—Sections taken from near the apex of the right ventricle show fat infiltration to an advanced degree. The muscle tissue is loosely arranged in small bundles and separated by areas of myxœdematous connective tissue containing exceptionally large fat cells in considerable amount, which even to the naked eye gives a streaky appearance to sections through the cardiac wall. Individual muscle fibres are separated from one another by a colourless ground substance. They show, if anything with increased clearness, the transverse striation, and are often distinctly swollen, and many of their nuclei are of particularly large size.

The connective tissue of both peri- and endocardium is of a similar nature to that tissue elsewhere, and is increased in thickness. A large proportion of the nuclei of fat cells are several times the normal size, and contain a spherical vacuole through their centre, and occasionally two. This vacuolation is also to be seen in some other of the connective-tissue cells scattered amongst the muscle fibres. There are no collections of any size of small round cells. Small arteries show some peri- and endarteritis.

Lungs.—Most of the vessels and capillaries are filled with blood. The small arteries have their muscular walls thickened to a slight

degree; in some this is irregular, only affecting one side, and there is a certain amount of hyaline degeneration present. In some there is an indication of endarteritis. Some contain an excessive number of leucocytes. Amorphous material is seen in some of the smaller blood-vessels. Many of the smaller capillaries forming the walls of alveoli are thickened to a slight extent on one side by a swollen homogeneous change in the muscle or fibrous tissue. In others there is a distension and thickening of the walls at the angles of union of adjoining alveolar spaces, so that when these break away and are attached only at one side they have the appearance of small bulbous masses protruding into the air-spaces; particularly is this so where the lumen is almost occluded by hypertrophy of the wall. This condition, however, is not nearly so marked as in the case of L. D—.

No cartilage-like masses within the alveolar spaces have been found such as were observed in that and the other case now recorded, but some air-cells are occupied by fibro-hyaline deposits either derived from the alveolar walls or formed as exudations within the air-spaces.

Sparsely scattered about the lung, recognisable to the naked eye in unstained sections as small areas the size of pins' heads and of fainter tint than the surrounding lung tissue, are peculiar little solid growths which appear to have developed from blood-vessels. These are found to be localised areas surrounded on all sides by lung alveoli and quite apart from bronchial tubes, but usually in close proximity to a small blood-vessel. Their minute structure consists of connective tissue in which is embedded a group of deeply staining cell masses, at first sight presenting much the lobulated appearance of a racemose gland. Under a high power, however, these deeply staining cells are found to be irregular elongated cells blending with the stroma, and it becomes fairly evident that they owe their origin to the endothelial lining cells of small blood-vessels.

A condition best seen in formalin-hardened specimens is the presence of a mucoid-like deposit in some of the alveolar spaces. This has a stringy appearance like coagulated mucus, and has usually shrunk away to one side of the air-spaces. It is this material that probably gives to the fresh lung its gelatinous character. In a few of the spaces are to be found small spherules of colloid; these stain more deeply than the mucoid material, and

are quite structureless. Similar masses may be seen distending capillary vessels.

In other parts of the lung are small areas of grey exudation; there are scattered air-cells filled with large round corpuscles derived from the lining endothelium, and other distinct pneumonic patches filled with small round-celled exudation, the alveolar walls masked, the interior of area caseating and breaking down in the centre. Areas such as these are small, not so large as small peas, and are but few in number. There is no sign of tubercular giant-cells. Some fibrous septa contain an increase of leucocytes. The connective tissue around bronchial tubes is of a loose character.

Liver.—The hepatic cells are much pigmented, and many are distinctly degenerated, large, swollen, and breaking up into granular matter. A large number of the nuclei are swollen and deformed, and some are vacuolated. A number of the swollen cells have a clear œdematous outer part, others are compressed and atrophied. The capillary spaces are exceptionally distended, and contain much fine granular matter mixed with red corpuscles; the distension is most marked in the central part of the lobules. The connective tissue of Glisson's capsule has its cells separated by œdematous material.

Kidneys.—There is increase of intervening connective tissue, in places in larger areas. This has the peculiar appearance of that generally seen in myxœdema, there being a loose network formed by fine fibres or breaking-up fibrillæ. Almost throughout the renal epithelium is markedly swollen, granular, and in places its nuclei have disappeared. A number of the glomeruli are represented only by dense, hyaline-like, spherical masses; in one or two, where this degeneration is not quite so advanced, there is a more distinct, dense fibrous, glomerular capsule. In the walls of the larger blood-vessels the muscle-fibre cells are usually widely separated.

Spleen.—The fibrous-tissue trabeculæ have the same appearance as though the fibres have broken up into minute fragments. The vessels are thick-walled. Splenic pulp seems natural.

Brain.—Portions examined consisted of the cortex from the frontal region and the internal capsule and grey ganglia. The blood-vessels in the region of the cortex have their walls markedly thickened. Sections through the blood-clot and cortex adjoining show extravasated blood contained in meshes of the pia arachnoid;

part is free from corpuscles, and exists only as a fine fibrinous network. The blood passes into and partly destroys the cortex cerebri.

Some of the small blood-vessels and lymph channels are filled with amorphous, colloid-like material. Pigmented cells exist in a few of the perivascular sheaths. The endothelial lining of the lateral and third ventricle is normal; the neuroglia beneath seems thickened and œdematous in appearance.

Specimens have not been specially prepared to show the nerve-cells of grey basal matter and large pyramidal cells of the cortex, but in logwood-stained sections many of these are shrunken, and more or less surrounded by considerable spaces. Such a condition may possibly have been artificially produced by the mode of preparation and reagents employed.

Pituitary body.—There is no excessive cystic formation of the glandular lobe, although there is a distinct cystic formation stretching completely down the hinder part of the anterior lobe in the vicinity of the boundary zone. Here there are numerous small cysts or distended alveolar spaces lined by cubical cells and filled with colloid. Similar colloid material passes into the posterior lobe in this neighbourhood, but for the most part is not here confined in distinctly lined spaces, but seems to form a diffuse mass in the ground substance. There is less general thyroid-like formation throughout the anterior lobe, such as existed in the other cases, though there are numerous small scattered colloid masses within the epithelial cell masses, more particularly around the outer parts of the gland. In some the colloid is evidently altered in character, for it has become deeply stained with logwood. Many of the epithelial cells are considerably swollen, but not hypertrophied to the same extent as in the case of L. D—; a few contain small colourless spherules, apparently of a colloid or watery secretion.

The stroma is about normal in amount and not much altered in appearance. At the lower and hinder part of the anterior lobe is a small area in which the epithelial masses are of irregular arrangement and more deeply stained, but such a condition is by no means rare in the pituitary body, and can scarcely be looked upon as abnormal, although perhaps the condition is a little in excess in the present instance. The glandular tissue is continued some way up the peduncle, a number of the cell masses containing small collections of colloid.

The posterior lobe is composed of loosely formed bands of connective tissue with a good deal of intervening colloid material.

Thyroid gland.—Section taken from the outer and lower part of the left lobe shows a condition of the gland usual to myxœdema. There is an exceptional amount of dense fibrous tissue with an absence of fat and with but few small blood-vessels, which latter have their walls somewhat thickened. Scattered about are the usual "lymphoid nodules," of which there are some half-dozen in an area of half a square inch. They show up strikingly to the naked eye in stained sections, and vary in size from a pin's point to areas of $\frac{1}{8}$ inch across. The smallest of these consist only of small round cells as of inflammatory origin; the larger masses are composed of similar small round cells contained in a fine reticulum of delicate fibres and branching cells, and scattered about this tissue are a variable number of small groups of epithelial cells, almost all in a very atrophied condition.

In these "lymphoid nodules" there is an absence of colloid-containing vesicles, but in some sections may be found small isolated areas of the thyroid tissue where the atrophic changes are less advanced; here there are distinct alveolar spaces lined by cells somewhat modified in appearance with vesicles containing colloid. One or two small groups of solid epithelial cell masses are also to be seen quite apart from the lymphoid tissue; these cells have a healthy appearance, they are uniform in size and stain deeply. It seems probable that these are isolated portions of the gland that have undergone compensatory hypertrophy.

A small lymphatic gland from beneath the right lobe of the thyroid, which in the fresh state was of a yellow tint and not appreciably enlarged, is found on section to contain normal lymphoid tissue, but there is the œdematous-like change in the connective tissue, and slight replacement of gland by fat cells.

Having described the general pathological conditions present in the body in the two cases of myxœdema, both from the naked-eye and microscopic point of view, I wish now to call attention to two remarkable morbid conditions coexisting in the second of these cases. One was a peculiar little growth found in the stomach, the other the existence of a parasite in the voluntary muscles. Both of these are presumably a merely accidental association, but lend increased interest to the case.

Growth in stomach wall.—On referring to the *post-mortem* de-

scription of the case it will be observed that reference is made to a minute nodule in the wall of the stomach. This at the time of the autopsy was cut out with the whole thickness of the wall of the viscus, and subsequently sections were cut through the entire piece vertically to the surface.

In preparing the sections the mucous membrane became detached from the remaining tissue. There is no indication of ulceration on the surface, but the secreting glands are masked by a lymphoid tissue-like infiltration with definite collections of round cells in places, more particularly towards the base of the glands immediately above the muscularis mucosæ. At one place the glandular structure seems to have broken through into the tissue below.

Sections through the actual nodule prove this to be formed of glandular growth situated in and amongst involuntary muscle tissue. In the superficial portion is a fair-sized area of gland tissue with the typical structure of a tubulo-racemose gland; the acini are of regular formation, cut transversely, and separated into lobules by a small amount of intervening connective tissue. This seems to be a non-malignant adenoid growth. The deeper part of the nodule, however, presents a very different structure. Here in clefts amongst thick masses of plain muscle tissue are small columns of columnar-shaped epithelium, either irregularly massed together with a small amount of colloid matter, or arranged in a single row round a central lumen. These cells are mostly long, even, with a clear free end, the nuclei being situated close to the attached extremity of the cell. The majority of these epithelial cells occupy a position in the centre of circular muscular masses, which seem to be arranged very definitely around them, this giving the growth a very peculiar appearance. This growth extends through the whole thickness of the muscular wall. In some parts there is a round-celled infiltration, in others distinct increase of the plain muscle nuclei. This part of the growth is scarcely distinguishable under the microscope from columnar-celled carcinoma, such as occurs in the gastro-intestinal tract. The external serous coat of the stomach is not involved, the connective tissue is loose, and the small vessel walls are thickened. It thus seems to me that there has been a proliferation of the plain muscle tissue together with some glandular element that has become cut off from the secreting glands of the mucous membrane, and that these have commenced to take on a malignant development.

Parasite in voluntary muscles.—In the first section which I happened to examine of a portion of the right sterno-thyroid muscle, I came across a peculiar object which at once suggested to my mind the form of a parasite of the nature of *Trichina spiralis.*

To the naked eye there was not the slightest indication of anything of the kind in any of the muscles exposed at the autopsy. The muscles, as has been said, were uniformly of a pale pink tint, showing nothing to lead one to suspect the presence of such an object. There was not the faintest indication of any spotted or "measly" appearance such as that usually present in cases of trichinosis. This, I am inclined to think, was due to the pale colour of the muscles, the small size of the parasite, and the almost entire absence of fat cells around its capsule.

The body referred to above lies in the connective tissue between the muscle bundles, and consists of an oval capsule of amorphous structure staining with logwood, and within are two oval diatom-shaped masses, which are presumably portions of a worm that has been cut across. Even in stained sections the whole structure is seen with difficulty by the naked eye owing to its minute size; it is a mere speck.

Fortunately portions of the left sterno-thyroid muscle and of the left pectoralis major had been preserved, and these were consequently examined for the presence of this body. Owing to the want of proper embedding methods, muscle fibres were mounted with difficulty and in small quantities, but several excellent specimens were forthcoming from both these sites. Several perfect encapsuled worms were luckily hit upon, which leave no doubt as to the nature of the intermuscular parasite. The parasites are situated between the muscle fibres, they have a dense oval capsule deeply staining with hæmatoxylin, and coiled up within this are portions of, and in others complete worms, which also have taken up the stain to some extent. There is an absence of round-celled infiltration close by, and usually no adipose cells at either end, although occasionally there are one or two such cells; generally there are only a few connective-tissue cells at either end, but some have a row of nuclei stretching along the muscle fibre, that lies almost in contact with the capsule. The capsules seem to be formed of a hyaline material with absence of calcareous matter, and are about $\frac{1}{50}$ inch in length. The parasites are undoubted *Trichina spiralis.*

No unencapsuled worms have been seen. They were not found

in the cardiac muscle or in any other tissue of the body that has been examined. As a rough guide to their frequency in the muscles, it may be mentioned that one was found in each of the five left sterno-thyroid, two out of three right sterno-thyroid, and three out of five left pectoral muscle specimens that were mounted. Considering their presence in the muscles that have been named, it may be presumed that they also existed in the other striped muscles of the body. It has been said that they are especially abundant in the muscles of the larynx, but it may be that these muscles have been more thoroughly examined than many others.

It is impossible to account for the presence of this parasite in the present case. The patient was an inmate of the asylum for five years. Here pork is occasionally given as an article of diet, but I have never seen or even heard of a case of trichinosis in Colney Hatch. If such a disease occurred here we might reasonably expect to find cases presenting the symptoms of that disease, or even recognising the measly appearance in the muscles exposed at an autopsy examination. Previous to her admission in Colney Hatch she was in St. Marylebone Infirmary from October, 1891; she had, moreover, been an inmate of that institution between July, 1885, and April, 1888.

From notes supplied to me by Mr. Lunn when she first came under my care, I will quote the following extract as possibly bearing upon the subject. It is a note made in July, 1885.

"Always had good health; only ailing twelve months. First commenced in the big toes with intense pain, which was followed by swelling in the wrist. Is said to have slept in a damp bed in March, 1884, since which she has been unable to attend to her calling, and has been for the most part confined to her bed. There is swelling and thickening of the lower end of the femur, with grating in the joints; both knees can be bent. Phalangeal joints enlarged and thickened. Complains of intense pain in all the joints. No nerve symptoms." Two years later she seems to have developed religious delusions, and afterwards paroxysms of religious frenzy. It has already been said that when admitted to Colney Hatch Asylum both wrists were swollen and deformed, which gave one the idea of old chronic rheumatoid arthritis; no other arthritic affection was present unless it was masked by the general swelling produced by the myxœdema, which disease, as has been described, was of a typical form and influenced in the characteristic way by

the administration of thyroid preparations, although producing acute pain in the wrists.

The symptoms occurring in trichinosis are not unlike those given above. They resemble in the first instance, after the intestinal symptoms have passed off, those of acute rheumatism, with rheumatic-like pains in the muscles and immobility of the limbs; and secondarily of myxœdema, with dropsy of the face and limbs, particularly of the eyelids, with also hoarseness of voice. Other signs might be mentioned in which the parasitic disease resembles one or other of the two referred to.

At first it might seem a far-fetched theory to venture to suggest any relation between the presence of trichinæ in the muscles and the development of myxœdema in the same person, but taking the foregoing history into consideration, and seeing that the laryngeal muscles are said to form a favourite site to which these worms are wont to migrate, and as we have clear evidence of their presence there in this case, as well as signs of old inflammatory lesions in these muscles, possibly the result of the parasites present, it seems to me at least conceivable that atrophy of the thyroid gland may have been set up as a result of inflammation around or actually in the gland as a consequence of the parasite, and that myxœdema followed as a sequence.

Be this as it may, it seems now, in the light of subsequent events, that the pain complained of in the wrists of this patient had some relation to the presence of the parasite. Possibly these were affected by the stimulating action of the thyroid given; they may have been awakened and commenced a migration to other parts. I do not know if we can entirely negative the theory that the parasite was introduced into the body with one or other of the thyroid preparations given; but this becomes less probable in the light of the early history that is given.

Another theory I might venture to put forward is in relation to the growth in the wall of the stomach. Could some epithelial cells have been carried down from the surface at the time the parasites were eating their way through the wall of that viscus, and there taken on new life and growth? Such might account for the peculiar pierced condition of muscle bundles in which the epithelial growth is largely contained. These theories are indeed speculative, they may be exceedingly improbable, but I do not think they should be called impossible.

Summary of three cases.

All three were females dying insane, with mental symptoms of eight, four, and ten years' duration, at the respective ages of 49, 46, 54. Myxœdema was first recognised in the first two cases some time after admission to the asylum, but in the third case it was observed about three and a half years before the onset of the mental condition. The second was still in an early stage of the disease at the time of death; the others were very advanced. The first died before thyroid treatment was introduced; the others both underwent a course for a time.

Macroscopical lesions.—Cases 1 and 3 at death presented the external appearance of advanced myxœdema, together with the usual conditions found internally; Case 2 was not greatly marked in either respect.

In Cases 1 and 3 the tongue was much enlarged, the fat excessive in amount and of a peculiar pale gelatinous character, all muscles of a pale tint, heart enlarged and exceedingly fatty, arteries atheromatous, lungs œdematous, kidneys of about normal size but slightly fatty and granular on surface, liver nutmegish.

In Case 2 the tongue was not enlarged, fat in excess but only slightly altered in appearance, muscles pale, heart not enlarged but fatty, arteries fairly healthy, lungs not œdematous but contained a number of small foci of old tubercle in a caseous condition, kidneys enlarged and fatty, liver fatty.

Case 1 had old hæmorrhages in the brain, and Case 3 a hæmorrhage beneath the pia mater over right frontal lobe; Case 3 had a uterine fibroid and a large blood-cyst of the right ovary; in Case 2 was a small uterine polypus. The thyroid gland in all three cases was extremely pale, and of the first two cases much reduced in size, but less so of the third.

The pituitary body in all three cases was above the normal in size and weight, most marked, however, in the first of the series; their respective weights were 19, 13, and 12 grains.[1] The dimen-

[1] Five to 10 grains may be looked upon as the weight of an ordinary pituitary body, although more than once I have found it reaching as much as 14 grains. The gland, when above 10 grains, invariably owed its increased weight to engorgement with blood, and not, as in the above cases, seemingly to proliferative changes in the epithelium and increased colloid secretion. Hypertrophy of the pituitary body in myxœdema to the size of a walnut has been reported by Kr.

sions given in parts of inches through the central diameters of the three glands were—

Case 1.—	Transverse	$\frac{13}{16}$;	antero-posterior	$\frac{8}{16}$;	vertical	$\frac{3}{16}$.
„ 2.—	„	$\frac{10}{16}$;	„	$\frac{9}{16}$;	„	$\frac{3}{16}$.
„ 3.—	„	$\frac{9}{16}$;	„	$\frac{7}{16}$;	„	$\frac{4}{16}$.

Microscopical appearances.—Attention may be drawn more particularly to certain histological features. The loose character of the connective tissue with fibrous bundles largely broken up into individual fibres. The vacuolation of a considerable portion of the fat-cell nuclei.[1] Both these conditions are present throughout the body wherever these tissues exist, and are common to all three cases. A thickening and hyaline degeneration of the muscular and fibrous coats of the small arterioles, carried to an excessive degree in Case 1, where marked endarteritis also exists. A loose arrangement of the fibres composing small muscle and subcutaneous nerves, with often a colloid deposit within the sheath. Cardiac

Gron ('Norsk Magazin for Lægevidenskaben,' Aug., 1894). This was in a woman aged 62, dying in a demented state with myxœdema of five years' duration, in whom the thyroid was greatly atrophied; see 'Brit. Med. Journ.' (epit.), Sept. 1, 1894. Reference may also be made to the epitome, 'Brit. Med. Journ.,' Nov. 2, 1895, and 'Brit. Med. Journ.,' Jan. 25, 1896, p. 204.

[1] Remarking on the vacuolation of nuclei of fat cells, Prof. Horsley says: "I first observed it in 1885, but could not find any reference in the literature of that time to the matter; and subsequently Prof. Boyce and Mr. Beadles independently observed the fact in a case of myxœdema published by them in 1894 [this should be 1892]. Since then the question of the vacuolation of the nuclei of fat cells in general has been very thoroughly investigated by Sack, who goes much further and finds that vacuolation of the nuclei of fat cells occurs not only in diseased tissues, namely lipomata, but also in normal developing fat and in fat undergoing senile degeneration. It is obvious, therefore, that vacuolation of the nuclei of the fat cells, although a very interesting biological condition, is not peculiar to myxœdema, and consequently cannot be regarded as pathognomonic of that disease change" ("An Address on the Physiology and Pathology of the Thyroid Gland, delivered before the Medical Society of London," 'Brit. Med. Journ.,' Dec. 5, 1896). Since the above remarks were made, I have examined with care the subcutaneous fat from a number of aged insane women, and also sections from half a dozen fatty tumours removed from the living. True, a few vacuolated nuclei may be found in both these conditions; perhaps, after a diligent search, as many as six to twelve throughout an entire section half an inch square may sometimes be found. Very different is it in the case of myxœdematous patients, where amongst any group of fat cells in a field of the microscope a number of vacuolated nuclei are invariably to be seen, and stand out as conspicuous objects under a $\frac{1}{6}$ inch objective.

muscle separated into small areas by adipose cells, and the separation of independent cardiac muscle cells from one another by a colourless ground substance, most marked in Cases 1 and 3. Areas of round-celled infiltration beneath the pericardium in Cases 1 and 2. In all three cases a mixed form of nephritis.

The lungs present some very peculiar conditions. In Case 1 the small artery walls are affected to a extraordinary degree by peri- and endarteritis, the new tissue having undergone a kind of hyaline degeneration. In many of the air cells are peculiar masses of a hyaline nature, some of which seem to have been formed as deposits in the air-spaces from changes in a fibrinous exudation, and others from a degeneration taking place in a growth from one side of the capillary walls, and cell nuclei appear to have become included amongst the swollen homogeneous material. In addition to this there are numerous peculiar deposits not unlike hyaline cartilage present in the air vesicles. These are scattered throughout the lung, just visible to the naked eye in stained sections. These minute chondromata, if such they are, give one the impression that they have been developed from the deposits above referred to; they have no connection with the bronchi, and their structure is different from the cartilage in the walls of those tubes. A few similar cartilage-like masses exist in the lungs of Case 2, which fact I am inclined to look upon as an argument against the accidental association and congenital origin of these deposits; moreover, I believe that a gradual transition can be traced between the hyaline deposits in the air-spaces, which seem undoubtedly the result of an exudation, and those masses which bear a striking resemblance to cartilage. In Case 3 are many fibro-hyaline deposits in the air cells, but none of the so-called cartilage-like tumours were seen. There are, however, small foci of solid growth apparently derived from endothelial cells of small blood-vessels. Some air cells are filled with mucoid exudation, a few with pneumonic; a few capillary vessels contain colloid, and spherules of this material lie free in the air cells.

All three cases show marked atrophic changes in the thyroid gland, the normal tissue has been replaced by dense fibrous tissue, in part hyaline in nature, and there are deeply-staining islands varying in size from mere specks up to $\frac{1}{8}$ inch across, where the atrophied remains of the gland exist, associated for the most part with a round-celled infiltration. Some of the smaller areas contain

only a few clusters of epithelial cells or colloid masses; some of the larger have atrophied epithelial cells embedded in lymphoid-like tissue, others are mostly composed of an irregular compact mass of epithelium with scattered vesicles of small size but normal structure.

The deeply-staining cellular areas which are always to be found in the atrophied thyroid of myxœdema have, up to the present time, invariably been considered as small portions of true thyroid tissue in an inflammatory and atrophying condition. Sometimes they have been spoken of as lymphoid tissue. Since, however, the structure and function of the parathyroid has been so extensively worked at, the suggestion has been made that some of this tissue may possibly be of the nature of parathyroid tissue, to which it apparently bears some resemblance.

Of the three entire glands only a small portion of each was submitted to microscopical examination, but the sections from each of these contain large cellular masses the nature of which might be in doubt. After a careful study of these I am strongly in favour of the view that the tissue seen is atrophying thyroid tissue, and not parathyroid tissue.

Stages may be observed from a round-celled infiltration of fairly normal vesicular thyroid structure, through others where there is little more than a collection of leucocytes associated with a few degenerated epithelial cells, to a final stage where but a small collection of the small round cells remain, surrounded on all sides by a dense fibrous tissue that has taken their place. This is an identical process to that which always occurs where chronic inflammation is proceeding. And as in other glandular tissues where slow chronic inflammation occurs we usually find an attempt at compensation by an irregular and imperfect formation of the epithelial structure, so, too, in the thyroid in myxœdema there is often to be seen an accumulation of epithelial cells with imperfectly formed vesicles and others more or less filled by cells derived from the single layer of cubical cells.

The larger cellular area in Case 1 is made up of small round, deeply staining cells indistinguishable from leucocytes, but scattered amongst these are small groups of epithelial cells, large and faintly staining, and for the most part broken down and greatly degenerated. A similar mass in Case 3 presents a structure more resembling lymphoid tissue, viz. small uniform round cells held

together by a loose network of fine fibrils and branching cells, and here and there small groups of epithelial cells scattered about. In both these there is an absence of colloid vesicles, though small masses of colloid occur in places.

In Case 2 the larger oval area bears more resemblance to the description of parathyroid tissue, but I believe this to be simply altered thyroid tissue, the result of atrophy associated with some compensatory hypertrophy. The greater part of the tissue is composed of epithelium. The cells are massed irregularly together, in places evidently taking the place of colloid in vesicles through proliferation, and scattered throughout are round vesicles. The latter are much smaller than normal thyroid vesicles, and their contents is of a more watery nature than the normal colloid matter of the gland. Apart from the frequency of these vesicles, the arrangement of the epithelial cells does not correspond with those of the parathyroid, in which the cells are arranged more or less in columns with intervening narrow strands of connective tissue. Around the periphery is a distinct inflammatory infiltration amongst the epithelial cells.[1]

The pituitary body in all shows signs of increased activity in the glandular lobe. The cystic condition at the boundary zone is increased in extent, the spaces larger and more numerous. Through-

[1] Sections from the thyroid glands have been submitted to Mr. Walter Edmunds for an opinion, he having done much useful work on the pathology of the parathyroid and thyroid. He agrees with me in considering the deposits referred to above as portions of the thyroid proper that are in a state of inflammation and atrophy. The structure observed in Case 2 he acknowledges as bearing some similarity to parathyroid tissue, but there is an absence of grouping of the cells in columns, and the presence of such a large number of colloid-containing vesicles does not occur in the parathyroid; moreover, he has shown that when compensatory hypertrophy of the parathyroid takes place after removal of the thyroid, there is simply a slight increase in size of the normal parathyroid without the development of vesicles or colloid. The arrangement of the epithelium more resembles that which occurs in the proliferation of the thyroid epithelium in goitre and thyroid tumours. Further, experimental evidence is directly opposed to the view that parathyroid tissue remains intact in cases of myxœdema. It is only by extirpation of the parathyroid in animals that serious symptoms are produced, and removal of the thyroid alone gives rise to little effect so long as the parathyroids are left uninjured. Consequently one would expect to find degeneration or disappearance of these bodies in persons dying with advanced myxœdema. A report of Mr. Edmunds' work will be found in 'Journ. Path. and Bact.,' Jan., 1896, and Jan., 1898; 'Path. Soc. Trans.,' 1895 and 1896.

out the anterior lobe the epithelium is more irregular, in places larger in size. There is an unusual number of perfectly formed vesicles lined by a single layer of cubical epithelium with colloid within simulating thyroid tissue. Cases 1 and 2 show these changes to the greater extent, and Case 1 especially the irregularity and enlargement of the cells; but Case 3 has much scattered colloid and some swollen epithelial cells containing vacuoles, which are evidently droplets of secretion.[1]

Apart from the lesions that may be incidental to myxœdema, there was discovered by accident after death in the third case two remarkable conditions; one of these was a small glandular growth in the wall of the stomach, the other was the presence in the voluntary muscles of a parasite, the *Trichina spiralis*.

April 5th, 1898.

[1] This condition of the epithelium I do not remember to have seen in other pituitaries. A similar condition has been described in the thyroidal epithelium, but not, so far as I know, in the epithelium of the hypophysis cerebri.

VIII. DISEASES, ETC., OF THE SKIN.

1. *Lipoma nasi.* (*Card specimen.*)

By Edgar Willett.

Microscopical sections were shown obtained from a specimen removed by operation by Mr. Howard Marsh from a gentleman about 70 years of age, who had noticed the deformity for about four years; there was no special history of alcoholism. Under a low power the sections show that the structure consists in the main of increased fibrous tissue in the deeper structure of the skin, in which are embedded masses of hypertrophied sebaceous glands; it will be noticed that fat is chiefly conspicuous by its absence.

Of some very beautiful sections, kindly prepared in various ways by Dr. F. W. Andrewes, some stained by osmic acid showed much darkening, but this is mostly in the sebaceous material itself, and not in the fibrous tissue; other sections specially stained showed the bacilli said to be specially connected with seborrhœa.

The question of sex is interesting; the disease is supposed to be the result of alcoholism, although this habit is by no means confined to the male sex; the disease, if not confined to the male sex, is at all events much commoner among men than women.

January 4th, 1898.

---

2. *Papilliferous cyst of a sudoriparous gland from the axilla.*

By H. Betham Robinson, M.S.

The following specimen was removed from a little child aged 13, on December 7th, 1897.

In the skin of the outer wall of the left axilla was a small

tumour covering the area of a shilling, which was bulging in the centre and translucent, with a small amount of thickening around what was evidently a cyst. This was excised.

The history given was unimportant. The lump had only been noticed a very short time, and it gave no inconvenience. There was no history of any scar, nor were there any swellings elsewhere.

On cross-section a cyst about the size of a Barcelona nut was exposed, from which exuded a clear fluid without any trace whatever of any sebaceous matter; this fluid was not of sufficient quantity to allow of a chemical examination. Round the cyst could be seen some smaller cysts embedded in a reddish vascular tissue. At the side of the large cyst over a small area was a nodule of a similar character projecting into it.

On microscopical examination the skin epithelial layer is intact, and the growth is embedded in the corium. The cystic spaces are lined by epithelial cells two or three layers thick, flattened more or less, presumably from pressure. From certain spots are papillary growths projecting into the interior. The papillæ are covered by a columnar epithelium, the superficial cells becoming vacuolated. The connective tissue shows no sign of round-celled invasion, and there is no doubt that the growth is innocent in its nature.

The histological characters of the cyst and tissue around seemed to exclude any other conclusion but that the growth had its origin in a sudoriparous gland. These are, of course, very much in evidence in the axilla, where the cyst arose.

On making a search through surgical and pathological records for any similar specimen I have passed over a completely barren field, but in Unna's work on the 'Histo-pathology of the Skin' I find reference to cyst formation from the sudoriparous glands in the following terms. Cysts are only known of the duct and its prolongation through the epithelium, not of the "coil." The cysts arising within the epithelial layer he terms "poro"-cysts, and the block occurs in the horny layer. Such cysts are met with in relation with scars. The duct cysts—hydrocystoma—are met with in the cutis, and are due to blocking in the principal cell layer, or where the duct enters the cutis. These cysts contain clear sweat secretions; their size seems to be quite small, like the porocysts. Under the term "spiradenoma" he speaks of an increase in the gland epithelium in the coil, but this is not associated with retention of sweat, and is not in relation with any other skin lesion.

Under the term "lymphangioma tuberosum multiplex," first used by Kaposi, many cases are grouped which have some rough likeness to this, but I have not found descriptions of their pathology. The names are various: syringo-cystadenoma (Török); adénomes sudoriferes (Davies), and epitheliomes kystiques benins (Jacquet).

Another suggestion has been that the cyst had occurred in a supernumerary mamma, but against this view may be urged the position of the lump on the arm side of the axilla, and the fact that nothing at all approaching the appearance of a nipple had been ever previously seen.

January 18*th*, 1898.

---

3. *Round pellets of sebaceous material from a dermoid cyst.* (*Card specimen.*)

By H. D. Rolleston, M.D.

The patient, a man aged 30 years, had noticed a swelling in the left side of the floor of the mouth for a year. Eight months ago it was tapped, and as a result some blood was drawn off. When admitted into St. George's Hospital under Mr. Bennett's care, a soft swelling existed on the left side which pushed up the floor of the mouth and projected below the jaw in the submaxillary region. It was incised, and a number of round white pellets about the size of rabbit's fæces came out; they were soft in consistence, and somewhat like putty. Microscopically they were composed of squamous epithelium undergoing fatty change. The cyst wall was subsequently dissected out, and was found to be lined by glistening skin showing microscopically a well-marked stratum granulosum with eleidin particles, which were stained, as directed by Mr. Shattock,[1] by Gram's method. The wall did not contain any glands, and no hairs were found in the cyst cavity. The cyst was therefore a dermoid, as shown by the presence of the eleidin-bearing cells, although its wall contained no

[1] 'Trans. Path. Soc.,' vol. xlviii, p. 254.

glands or hairs. The remarkable thing about it was that its contents had formed into separate and well-formed spheres.

May 3rd, 1898.

---

4. *Mycetoma papillomatosum.*

By Samuel G. Shattock.

[With Plate X, figs. 3, 4.]

The more common forms of lesion produced by the *Streptothrix Maduræ* are so well known from the various specimens contained in museums and from Dr. Vandyke Carter's monograph ('Mycetoma,' London, 1874) that any re-description would be altogether superfluous. The particular form to be described, however, has either hitherto not been met with, or if seen it has not been put on record by any who have written on this subject; from Carter's collection of cases it is conspicuously absent, and this presumably because it had not come under that author's notice; the minuteness of his several descriptions warrants such a conclusion.

The whole of the foot was, as is usual in advanced stages of the disease, greatly swollen, and presented the openings of numerous sinuses passing into the deeper structures. The unusual feature consists in a wide-spread and highly papillomatous condition of the skin, which I have thus described in the catalogue of the Royal College of Surgeons, from parts of the specimen recently placed in the museum:—"A slice from the sole of a foot affected with Madura disease. The integument and subcutaneous tissue are greatly thickened and œdematous, and are riddled with a complex system of sharply defined tortuous channels in which lie the soft, pale yellow, fish-roe-like grains of the parasite; the different spaces are for the most part thinly lined with connective tissue. The specimen is unusual in the develoment of a coarse papillary condition of the surface, some of the upstanding processes exceeding a quarter of an inch in height. The processes, like the

deeper parts, are hollowed out by spaces holding the parasite, some of which spaces reach to their very summits. The epidermis has been raised as a continuous structure, and presents a series of hollowed elevations accurately corresponding with the subjacent processes."

This preparation is followed by another portion from the sole of the same foot, the epidermis being completely removed to show the papillary formations, some of which are smooth, whilst others bear fine papillæ like those on the intervening areas of skin. The epidermis corresponding with the elevations is everywhere imperforate and intact.

That this condition is very unusual appears, as before noticed, from the absence of all reference to it in Dr. Vandyke Carter's monograph, where the different macroscopic characters of the disease are so minutely described.

It is highly interesting to note in passing that the occasional occurrence of *scarlet* "grains" is described by this author (loc. cit.), portion of the foot (Plate VII) and certain of the "grains" (Plate X) being carefully figured. The case, which evidently much impressed the author, is the second of those recounted under the pale or ochroid variety. The foot on section appeared as if strewn with red pepper grains, which were recognised as the parasitic bodies. These were very numerous, and from $\frac{1}{150}$ to $\frac{1}{40}$ inch in diameter; when lowly magnified they presented a mammillated exterior; one is partly burst, and is unpigmented within.

One cannot, of course, help seeing now that these scarlet grains represent colonies of the streptothrix which, from some unusual circumstance, have produced their particular pigment whilst amid the living tissues, for upon artificial media the elaboration of pigment is very erratic. Vincent describes and figures ('Annales de l'Institut Pasteur,' vol. viii, 1894, p. 129) the brilliant red colour which growths commonly assume upon potato, and I have many times seen this in sub-cultures of the strain from Vincent's first case. The coloration is confined to the exterior (as was the case in the natural colonies figured by Carter, loc. cit.). Upon glycerine-agar the growth is white, though after a while it becomes blotched with pink. The formation of pigment upon this medium is, as a rule, partial and variable; upon most other media it is wanting.

Whether this papillary condition is due to an uncommon and wide-spread invasion of the corium itself by the microphyte (which

DESCRIPTION OF PLATE X.

Fig. 1 illustrates Dr. Freyberger's case of "Anæmic Infarct in the Lung." (Page 27.)

Section through the posterior border of the right lung to show the position and shape of the infarct.

Fig. 2 illustrates Mr. S. G. Shattock's paper on Molluscum Contagiosum in Birds. (Page 394.)

The head of the first bunting sparrow described, showing a spherical molluscous tumour (in section) beneath the mandible; in its centre there is an irregular cavity, the interior of which has a somewhat coarse pseudo-papillary character. From a photograph (nat. size).

Figs. 3 and 4 illustrate Mr. S. G. Shattock's paper on "Mycetoma Papillomatosum." (Page 293.)

FIG. 3.—Showing a portion of the thickened integument, with sections of the devious tracks which hold the colonies of the streptothrix. The epidermis has been removed to show the character and number of the up-standing processes which project from the corium. From a photograph (nat. size).

FIG. 4.—Another section of the thickened integuments from the sole of the foot in the case described. The epidermis is partially raised from the subjacent coarsely papillary surface. Many of the papillary processes are riddled with spaces containing colonies of the *Streptothrix maduræ*. From a photograph (nat. size).

Fig. 1.

Fig. 2.

Fig. 3.

Fig. 4.

has induced an irritative hyperplasia), or to some less specific cause (the parasitic invasion of the processes being in this case a secondary occurrence), it is difficult to say.

Carter believes the usual mode of infection to be through the sweat ducts of the sole, rather than traumatic lesions of the skin itself. And the condition under notice may have arisen from an unusually extensive entry of such a kind, either original or by auto-inoculation from the discharges of certain of the sinuses. The results of irritation as an excitant of papillary formation in general are of wide distribution, and obtain not only in the skin but in mucosæ (even in those where no papillæ normally exist), in synovial membranes, and the ducts and secreting recesses of glands, as well as in retention cysts, whether arising in normal structures or in new formations. The best known cutaneous lesion of an analogous kind is, of course, that met with in filarial or other elephantiasis, though here the condition is commonly of a much less regular type, the cutis presenting a series of close-set elevations which, although they may bear enlarged papillæ, are themselves so coarse and ill-defined that the epithet of papillomatous is hardly applicable to the primary processes. The papillary outgrowths that are associated with macroglossia range themselves in the same category.

Apart from the filarial examples of elephantiasis, there is a less well known and rarer form of papillary outgrowth at times met with in association with eczema—eczema papillomatosum.

If the example of dermatologists is followed, a new name of some kind would be indicated for such a lesion as that recorded; and the one suggested in the title, mycetoma papillomatosum, may, perhaps, sufficiently answer the purpose. Of the papillomatous condition consecutive to eczema there are two excellent models in the College of Surgeons, amongst the masterpieces of Baretta. In one of these the hypertrophic formation extends from the heel across the external ankle and dorsum of the foot to the toes. The skin immediately bounding the granulated mass is red and thickened by infiltration, and the papillomatous growth is subdivided into polygonal and hemispherical lobes, the latter being made up of lobules and papillæ. The disease had been four years in progress.

In the second of the two cases the lower part of the leg and foot were also the seats of the change. Three years after the com-

mencement of the eczematous attack the lower third of the leg had become covered with nodosities and nodules, ranging from the size of a pea to that of a hazel-nut. A varicose state of the veins of the leg contributed its share to the development of the disease.

March 1*st*, 1898.

IX. MORBID GROWTHS.

1. *A case of melanotic sarcoma.* (*Card specimen.*)

By James Calvert, M.D., and T. Strangeways Pigg.

F. D—, aged 31, a messenger, was admitted on August 31st, 1896, into St. Bartholomew's Hospital under the care of Dr. Brunton, complaining of "a lump" in the abdomen.

History.—Three and a half years ago the right eye was excised at Windsor. We are indebted to Major Sheldrake, R.A.M.C., for the information that a growth was found in the eye, which looked like a gumma, but it was not examined microscopically. No other illnesses. He has been losing flesh and strength for eight months, for three months he has suffered pain at the epigastrium, and for two months he has noticed at the epigastrium a lump, gradually increasing in size.

Among the more important circumstances which happened to him during his stay in the hospital may be mentioned—

October 21st.—Left eye becoming prominent; commencing optic neuritis. Later the eye became very prominent, the optic disc choked, and the eyelids much swollen.

November 10th.—Left lobe of thyroid noticed to be enlarged and hard.

27th.—Some cutaneous nodules noticed on the chest.

December 27th.—Difficulty in swallowing.

January 12th.—Enlarged glands above left clavicle throughout. No abnormal signs were detected in the heart, and he died, apparently from exhaustion, on March 21st.

Post-mortem.—New growths were found in skin, subcutaneous tissue, muscles, glands of neck, thorax, and abdomen, thyroid, left

orbit, behind and below the eye, lungs, pleuræ, heart, stomach, intestines, liver, gall-bladder, spleen, pancreas, supra-renals, kidneys, bladder, testes, lumbar vertebræ, and dura mater. Some of these growths were black with pigment, some were partially pigmented, some were unpigmented. There was no growth in the left eye.

The pleuræ.—On the visceral pleuræ were many deeply pigmented growths, flat and circular like a button; some of them were pedunculated. A few similar growths were on the parietal pleuræ.

Heart.—Weight 15 oz. The pericardium was everywhere adherent by membranous adhesions, which easily broke down. No fluid. A few nodules projected from the walls of the auricles, and many from the ventricles, especially near the auriculo-ventricular groove, where some of them were as large as walnuts. Many nodules were seen buried in the muscular substance of the ventricles, and others bulged beneath the endocardium into their cavities. The valves were natural. All the growths in the heart were deeply pigmented.

Stomach.—On the posterior wall near the greater curvature, and about two inches apart, were three circular, flat, black growths about a quarter of an inch in diameter. The mucous membrane over them was intact.

Gall-bladder.—Within the gall-bladder were two black nodules at the fundus, and another at the neck.

Supra-renals.—In the right were several nodules, some deeply pigmented, others not pigmented. In the left was one nodule. In the notes of the case there is no record of pigmentation of the skin.

Bladder.—On the mucous surface was one small black growth, a little bigger than a pin's head.

Testes.—A deeply-pigmented growth occupied the centre of each testicle, and on the left side were two small black growths on the epididymis.

Dura mater.—One small, circular, flat, deeply-pigmented growth attached to dura mater at the base of the skull, another on the tentorium cerebelli.

Very conflicting statements are made concerning the relative frequency of melanotic sarcoma in the various organs; therefore it may perhaps be worth while to say that in the cases recorded in the 'Transactions' of the Pathological Society—

Liver	has been involved	19	times.
Heart	,, ,,	13	,,
Lungs	,, ,,	12	,,
Kidney	,, ,,	9	,,
Pleura	,, ,,	6	,,
Pancreas	,, ,,	6	,,
Spleen	,, ,,	6	,,
Supra-renals	,, ,,	4	,,
Dura mater	,, ,,	4	,,
Brain substance	,, ,,	3	,,
Bladder	,, ,,	3	,,
Stomach	,, ,,	2	,,
Thyroid	,, ,,	2	,,
Floor of lateral ventricles	,, ,,	2	,,
Choroid plexus of lateral ventricles	,, ,,	once.	
Testes	,, ,,	,,	
Prostate	,, ,,	,,	
Ovaries	,, ,,	,,	
Gall-bladder	,, ,,	,,	
Common bile-ducts	,, ,,	,,	

The specimens shown at the meeting were fixed in formalin and mounted in glycerine—a process begun at St. Bartholomew's and introduced into England by Dr. Kanthack.

October 19th, 1897.

---

2. *Symmetrical rodent ulcers of the face.*

By Percy Furnivall.

The patient, a male aged 64 years, was under my care at the Metropolitan Hospital. He had a typical early rodent ulcer, about the size of a sixpence, in the skin over the right zygoma, on a level with and about three quarters of an inch from the right external auditory meatus. There was a similar growth about the size of a threepenny bit in the same position over the left zygoma.

He had noticed the pimple on the right side of his face for about eight months, and that on the left side for about four months.

The microscopical sections of both the growths show them to be typical rodent ulcers.

November 16*th*, 1897.

---

3. *Symmetrical rodent ulcers in groin.* (*Card specimen.*)

By T. Strangeways Pigg.

E. F—, female aged 47, single, admitted suffering from an ulcer in the groin.

Fourteen and a half years ago the patient noticed a small pimple in the fold between labium and left thigh. This gave no trouble, but gradually grew larger.

Five and a half years ago it began rapidly to increase in size, and in nine months doubled its size.

Four and a half years ago the patient was first seen, and an ulcer five inches long and about one inch in breadth was found occupying the fold between the labium and left thigh, and extending on to the groin. No glands were to be felt. The ulcer was removed by Mr. Butlin, and found to be microscopically a rodent ulcer. At this time a small nodule about one third of an inch in diameter was noticed in the right groin; it was not inflamed or indurated, but it was raised above the surface of the skin, and had all the appearances of an ordinary wart.

A few days ago the patient returned to the hospital (St. Bartholomew's) with recurrence in the left groin, and a small ulcer half an inch in diameter was found at the site of the old scar left by the previous operation; it was surrounded by firm scar tissue, but was not indurated; the growth extended deeply below the skin, reaching the femoral vein.

In the right groin at the site of the previously mentioned nodule was an oval swelling about three quarters of an inch long, raised above the surface, and with a small ulcer on its summit.

Both ulcers were removed, and microscopically proved to be rodent ulcers. The specimens are of interest because of the rarity of symmetrical malignant growths.

November 16*th*, 1897.

---

4. *Rodent ulcer near the umbilicus.* (*Card specimen.*)

By H. D. Rolleston, M.D.

The specimen which by Mr. W. H. Bennett's kindness I show to-night was removed from a medical man aged 77. For some time (duration not stated) there had been a watery excrescence just above the umbilicus, which he himself had treated by ligature, caustics, and lotion.

On admission there was an excavated ulcer just above but not involving the umbilicus, with hard and somewhat undermined edges. There was no glandular enlargement. The free removal of the affected area was followed by complete recovery.

Microscopically there is the typical appearance known as rodent ulcer; it is most marked in the superficial layers of the dermis, and grows up to and even becomes continuous with the overlying epidermis. The deeper layers of the dense dermis are also invaded by straggling streaks of growth resembling the more superficial part. The growth is composed of small cells, chiefly round, but sometimes elongated by pressure, arranged in alveoli which are bounded by delicate connective tissue. There are no cell-nests or signs of keratinisation.

The epidermis showed signs of moderate irritation in elongation of the interpapillary processes, and the proliferating cells at their edge so closely resembled the cells of the rodent ulcer growth that their character certainly might be taken as supporting the view that rodent ulcer may be derived from the rete mucosum. But after all, the elongated downward growth of the interpapillary processes is equivalent to an abnormal appendage of the skin, so that this observation hardly helps one to decide the much-debated point whether rodent ulcer is derived from the rete mucosum or from the appendages of the skin such as the sebaceous or sweat glands,

the hair follicles, or rudimentary skin glands. The broad view taken by J. Hutchinson, jun.,[1] that rodent ulcer may arise from either the skin or its appendages is, it seems to me, very hard to controvert.

In this specimen sweat glands were very scarce, no sebaceous glands were seen, but there was a hair follicle cut across in the neighbourhood of the growth.

Rodent ulcer rarely occurs except on the head or face; in sixty-six cases collected by Mr. Bowlby[2] there were only two exceptions, one on the nape of the neck and one in the dorsal region. Mr. H. B. Robinson[3] has described a rodent ulcer of the male breast, and in the last volume of this Society's 'Transactions' Mr. Jonathan Hutchinson, jun., gave an account of a rodent ulcer of the forearm, and referred to a rodent ulcer of the groin under Mr. Eve; and in the subsequent discussion Prof. Kanthack[4] spoke of a rodent ulcer in the groin that had recently been examined at St. Bartholomew's Hospital.

Mr. Jonathan Hutchinson[5] has recently described as a superficial rodent ulcer an ulcer the size of the palm of the hand situated on the flank of a woman aged seventy-four. This case was, however, not examined microscopically. It is noteworthy that Mr. Hutchinson classes rodent ulcer with Paget's disease of the skin.

November 16*th*, 1897.

[1] 'Trans. Path. Soc.,' vol. xlviii, p. 220.

[2] Bowlby, ibid., vol. xlv, p. 159.

[3] Robinson, ibid., vol. xliv, p. 147.

[4] Kanthack, 'Brit. Med. Journ.,' 1896, vol. ii, p. 1384. This is, I believe, from the same patient as the symmetrical rodent ulcers of the groin shown by Mr. T. Strangeways Pigg; *vide* this volume, p. 300.

[5] Hutchinson, 'Medical Press and Circular,' Oct. 13, 1897.

5. *A case of colloid carcinoma of the breast; recurrence and dissemination.*

By C. E. M. Kelly, M.D.Lond., and W. D'Este Emery, M.D.Lond.

The history of this case is that in June, 1890, the patient, a married woman aged 39, was admitted to University College Hospital for a discharge from the nipple of the right breast; she was operated on by Mr. Hill, the greater part of the breast being removed for a growth which was thought to be duct papilloma; the tumour is described and illustrated in 'Erichsen's Surgery,' vol. ii, p. 781, 10th edition.

There was no recurrence until December, 1894, when she noticed a small lump in the same breast, but as it was painless she did not have anything done, although it was increasing in size, until August, 1896, when she was again admitted to University College Hospital. It was then found that the scar of the first operation, extending obliquely upwards to within two inches of the right axilla, was firmly healed. At its upper end, situated on each side, were two tumours: the one on the inner side, as large as a small egg, was rounded, and caused a marked projection under the skin; it was nodular or bossy, semi-elastic, with apparently little cysts which could be felt and seen on its surface. The skin could be picked up over it and it could be moved freely over the pectoral muscle beneath it, although not quite so freely when the latter was put into action.

The other tumour, situated just behind the anterior axillary fold, was rather smaller, but was similar in appearance and consistence; it was fairly moveable. There were no enlarged glands in the axilla nor above the clavicle; below the larger tumour was a small nodular mass of breast tissue.

The tumours were removed in August, 1896, with a piece of the overlying skin, the fascia over the pectoralis major, and some fibres of the muscle which were adherent, and a good deal of the surrounding fat.

Section of both growths presented the same characters—rounded tumours with a distinct capsule, of greyish-pink colour, granular

surface, with soft areas where the tissue had become gelatinous and viscid.

Histologically the growth was composed chiefly of colloid material showing small clusters of degenerated cells; at one part there was a strand of fibrous tissue surrounding large groups of spheroidal epithelium cells.

In July, 1897, she again came under our notice, as a small lump had made its appearance under the scar of the previous operation; it was about as large as a pigeon's egg, quite round, elastic, and finely nodulated; the skin over it was normal in appearance, and non-adherent. Her general health seemed fairly good, but she was complaining of pain in the right hip and down the right leg, which was considered to be rheumatic. No sign of any other secondary growth could be detected, so the small tumour was again removed and found to be typical colloid carcinoma. The last operation was trifling and she was soon well again, but now a general cachexia appeared, the pain in the right leg continued and grew worse, a troublesome cough developed, with the physical signs of bronchitis and a frothy mucoid expectoration, sometimes tinged with blood; this continued till her death, five months later. She had much pain in the right hypochondrium and all over the right side of her abdomen; the liver was enlarged, extending 2 inches below the ribs, while two or three nodules as large as a marble could be felt in it.

Three months before her death, after complaining very much of headache, which was intense and boring in character, a depression was found in the right half of the frontal bone; it was about 2 inches in diameter, nearly circular in shape. The edges of the depression were rough and irregular, but not at all raised, while the depression itself gave the impression of the bone having disappeared and been replaced by a thin, tense membrane through which the pulsations of the brain could be easily felt. This depression increased slowly in size till her death, so that near the end she presented a most curious appearance; all the right side of the front of her head sank in to a depth of about 1½ inches, the depression being bounded by the upper margin of the orbit, which was rough and irregular, by the middle line, the coronal suture, and the upper margin of the temporal fossa. Pressure on the depression gave rise to intense pain, but there were no cerebral symptoms. The skin covering it was normal in appearance, and non-adherent.

Two months before her death the sternum became affected, a tumour formed at the junction of the manubrium and gladiolus, the bone evidently being extensively involved by a semi-elastic new growth which extended into the cartilages of the third ribs on both sides. This growth attained a large size, and the patient complained much of pain there and of a feeling of pressure which it seemed to occasion in respiration.

She died in January, 1898.

At the autopsy the sternum was found to be involved by a new growth which had replaced the manubrium and the cartilages of the second and third ribs on both sides, only a shell of bone about a quarter of an inch thick remaining in the front; the tumour was yellowish-grey in colour, like soft cartilage in consistence. The lungs were filled with disseminated knots of new growth, none of which were larger than a pea, which were scattered closely over all parts of the organs; the lung tissue between the knots appeared normal; the tumours themselves were colloid in appearance, very firm or semi-elastic; there was no fluid in the pleura, and no adhesions were found.

The liver was much enlarged, and contained a few scattered nodules of new growth, round and white, the largest being the size of a marble, which in all respects resembled secondary deposits of scirrhus.

In the skull the right half of the frontal bone was replaced by an irregularly circular membrane, which was firm and depressed below the level of the bone round it; it was $3\frac{1}{2}$ inches in diameter, and $\frac{1}{8}$ inch thick, but this included the dura mater, which was closely adherent to the membrane, so that the membrane itself was only about $\frac{1}{20}$ inch in thickness. The edges of the bone round the depression were infiltrated with a new growth, which extended about $\frac{1}{2}$ inch into the bone; they were not thickened, but the bone was softened and more red and vascular than normal.

Histological examination of the material removed at the *post-mortem* showed that the growth was of the nature of a spheroidal-celled carcinoma, which had in some cases undergone colloidal degeneration, while in others it had not. In the liver there were masses of growth about the size of a marble. These had the typical structure of an alveolar carcinoma of glandular type, without any colloidal change; this was the more remarkable because the centre of the nodules showed distinct signs of degeneration. In the

lungs the nodules were much smaller, but there was a considerable amount of colloid degeneration, which, however, reached its greatest development in the sternum, the manubrium being practically entirely replaced by a mass of this substance, the bone being almost entirely removed. In this situation each small alveolus of growth was surrounded by a thick layer of colloid. The growth also extended into the body of the sternum, but was less advanced in this situation.

The chief interest is attached to the growth in the skull, and sections were made of the edge of the aperture in this bone with the membrane near it. The bone was found to be undergoing a process of rarefaction, this being most marked nearest to the edge of the gap. The spaces left were filled up by young-looking fibrous tissue with elongated or spindle-shaped nuclei, and in the middle of this fibrous tissue were round or oval alveoli of growth, these being most numerous where the bone ceased. The cells composing them had round nuclei which were very prominent, but their protoplasm was indistinct; in many cases nothing but nuclei could be made out. When these alveoli of growth were traced into the membrane they were found to become much more compact, and only the nuclei were visible, all traces of protoplasm disappearing; and these nuclei, although staining well and deeply, appeared to be degenerated, while the alveoli were smaller and less numerous in proportion as they were distant from the bone. There was no trace of any colloid change in any part of the bone or membrane.

The edges of the bone where it was undergoing absorption were surrounded by small round or oval cells, regularly disposed (osteoblasts ?). No osteoclasts were found.

It would appear that this remarkable aperture in the skull was formed by a process of absorption of the bone running parallel with the deposit of alveoli of carcinoma cells, and probably the new formation of fibrous tissue; that the alveoli of growth had but a short life, and did not attain any large size so as to form a definite tumour, but, on the contrary, rapidly underwent degeneration, so as to leave in place of the original bone merely a membrane containing a few compact masses of nuclei, the remains of the original growth. This fibrous tissue is much denser than where it occupies the interstices of the bone, and with the dura mater and periosteum added is not more than $\frac{1}{5}$ inch thick.

The most interesting points in the case appear to be the super-

vention of colloid cancer after the removal of the duct papilloma from the breast, which was probably a coincidence, as it is hard to see a connection between the two affections. The growth progressed more rapidly than in most reported cases of this variety of cancer, the secondary recurrence occurring in four and a half years, and death in eight years. No glandular enlargement was found.

It was curious, too, how the secondary tumours in the lung and sternum kept to the original type, while those in the liver and skull showed no trace of colloid degeneration. We have not been able to find record of any similar affection of bone like that in the skull by a new growth in which at no time was there any increase of tissue or enlargement of the bone.

Our thanks are due to Mr. Drew and Dr. Curtis, surgical registrars of University College Hospital, and Mr. Raymond Johnson, who have given much help in the early history of the case.

April 19*th*, 1898.

Report of the Morbid Growths Committee on Dr. Kelly and Dr. Emery's case of duct papilloma of the breast, followed by colloid carcinoma.—We agree with the authors' histological descriptions of the series of tumours shown by them. We have through the courtesy of Mr. Lawrance, the curator of University College Museum, re-examined the tumour removed by Mr. B. Hill four years previously, both macroscopically and by means of microscopic sections. On making a fresh section of the growth and adjoining part of the breast, numerous small cysts were rendered evident in the neighbourhood of the large cyst, together with certain minute areas strongly suggestive of epithelial infiltration. The microscopic sections made by us included, therefore, a considerable area of this suspicious tissue, and they display the characteristic features of a carcinoma. The cells composing the groups are polyhedral, and nowhere show a true columnar character. The wall of the cyst enclosing the papillary new formation is invested with a thick lining of cells nowhere of the columnar type, and without definite arrangement of any kind.

The free processes of the intra-cystic growth have a similar epithelial covering, and large groups of polyhedral cells occur in the substance of the intra-cystic growth itself.

We conclude, therefore, that the original tumour is a spheroidal-

celled carcinoma, and is to be regarded as the primary growth, and that the series of tumours described by the authors are true metastatic formations.

SAMUEL G. SHATTOCK.
NORMAN MOORE, *Chairman.*

---

6. *Lobulated fibroma of nipple.*

By CHARLES D. GREEN, M.D.

THE specimen was removed from the right nipple of a woman aged 33, a few weeks after the birth of her fourth child. She had been married six years, and at the time of her marriage had merely a small wart on the under surface of the right nipple, which

FIG. 11.

gave no trouble. It began to increase in size during her first pregnancy, and became somewhat painful; during lactation the pain considerably increased, and the patient was not able to allow the infant to make use of that breast.

During each successive pregnancy the tumour increased considerably in size, remaining fairly stationary in the intervals.

The base of the tumour became ulcerated, and considerable pain was caused by it, and the axillary glands became enlarged.

There has been no recurrence (three years have elapsed) since the growth was removed, and the patient has given birth to a child and has been able to use the breast for lactation without inconvenience.

The specimen (Fig. 11) consists of a fairly long, nipple-like pedicle, which was attached entirely to the under surface of the nipple, the incision for its removal not touching upon the areola, and of an irregularly pyramidal lobulated body. Histologically it was a pure fibroma.

There is a drawing in the museum of the Royal College of Surgeons of England of a somewhat similar specimen which was observed by Mr. Jonathan Hutchinson, and which is thus described:—"A breast from which there hangs a papilloma which had slowly developed from the areola; the nipple itself was not involved, and the patient, who was a married woman, could nurse her infant at the breast." This specimen differs from mine in being more minutely subdivided, and in growing from the areola.

In the 'British Medical Journal' of June 20th, 1896, Mr. Marmaduke Sheild figures a similar specimen growing from the areola and nipple.

The specimen is preserved in the museum of the Royal College of Surgeons of England.

April 19th, 1898.

---

7. *Lipoma of the ischio-rectal fossa.* (*Card specimen.*)

By H. J. Curtis.

This tumour, which was removed by Mr. Bilton Pollard at University College Hospital from a man aged 39, was first noticed about June, 1895, when it was "the size of a Brazil nut."

From May, 1897, it commenced to grow steadily, until at the time of the operation (April, 1898) it weighed on removal 1¼ lbs.

The chief interest in the case is the fact that it gave rise to a

very marked impulse on coughing, suggesting the possibility of its being or forming part of a hernia in the perinæal region. The physical signs apart from the impulse were those of an ordinary fatty tumour.

At the operation it was found to extend high up into the right ischio-rectal fossa, and its apposition to the levator ani, from which, however, it was readily peeled off, accounted for the impulse on coughing. There was no evidence of any communication with the peritoneal cavity, the growth shelling out without difficulty.

Two photographs of the patient before operation were exhibited.

May 17th, 1898.

---

8. *Lipomata: α. From back of right shoulder; β. From the substance of the right deltoid.* (*Card specimens.*)

By H. Littlewood.

Patient a man aged 51. Tumour removed January 24th, 1898.

α. The lobulated tumour had been growing six years, and was removed from the subcutaneous tissues over the back of the right shoulder.

β. The larger smooth tumour is said to have been growing about two months. It was removed from the substance of the right deltoid muscle. Before the operation it was thought to be a collection of fluid, probably a chronic abscess.

February 15th, 1898.

---

9. *Fibro-sarcoma of hand.* (*Card specimen.*)

By H. Littlewood.

Patient a woman aged 55.

Thirteen years before admission she had a very severe burn of the right hand at the back and near the ulnar border. This left a deep cicatrix.

Two years ago some growth was removed from this region.

After this it healed up, but soon commenced to increase slowly in size. At the time of the operation the growth, which was very hard, occupied the ulnar portion of the metacarpus; a radiograph showed that the metacarpal bone of the index finger had disappeared.

August 16th, 1896.—Growth removed along with three outer fingers. Some months after there was recurrence in the stump, and on April 25th, 1897, amputation was performed through the forearm. Since then no recurrence.

Microscopical examination.—Fibro-sarcoma.

The specimen is in two parts: 1, parts removed on August 16th, 1896; 2, showing recurrence.

February 15th, 1898.

---

10. *Sarcoma of hand.* (*Card specimen.*)

By H. Littlewood.

Woman aged 53. Three years ago a swelling appeared in the palm of the right hand near the inner margin of the thenar eminence. It slowly increased in size for two years, but more rapidly during the past twelve months.

August 16th, 1897.—Amputation of forearm. No recurrence at present.

The tumour occupies all the outer part of the palm, forming a large prominence in the interval between the thumb and index finger. (From the radiograph shown it does not appear that any of the bones are involved in the growth). Microscopically it is composed chiefly of round cells.

February 15th, 1898.

11. *Squamous-celled carcinoma of the alveolar process of the upper jaw, removed by operation from a man aged twenty. (Card specimen.)*

By WALTER G. SPENCER.

THE disease appeared as a new growth on the palate surface extending from the first molar tooth. There was no irritation about the tooth. The diagnosis was made by the microscopical examination of a small piece. The alveolar process of the upper jaw was removed, and the patient has remained free from recurrence for two years.

The bone has been cut through vertically, and the new growth appears to have originated deep in the alveolus. The new growth is a squamous-celled carcinoma.

November 16th, 1897.

X. BACTERIOLOGY.

1. *The bacteriology of the simple posterior basic meningitis of infants.*

By George F. Still, M.D.

[With Plate IX, figs. 2 and 3.]

Simple posterior basic meningitis, a disease which occurs chiefly within the first year of life, and is, indeed, very rare after the end of the second year, has only recently been recognised as a definite clinical entity with characteristic symptoms and course.

It was described in 1878 by Dr. Gee and Dr. Barlow in a paper on "The Cervical Opisthotonos of Infants," [1] and more recently it has been fully described by Dr. Carr [2] and also by Dr. Barlow and Dr. Lees,[3] so that it is unnecessary to refer here to its clinical aspect, except to emphasise the fact that it is quite as definite and constant in its symptoms as tubercular meningitis, and in the majority of cases can be diagnosed from other forms of meningitis with equal certainty.

It has, moreover, a morbid anatomy which is quite characteristic and even more constant than its clinical symptoms, as may be seen from the account given by the writers above mentioned, and from the brief notes given below.

Even from the macroscopic appearances it would be difficult to imagine that this disease was due to the same micro-organism that produces the ordinary suppurative cerebro-spinal meningitis of pneumococcal infection, or the so-called "septic" meningitis of

[1] 'St. Barth. Hosp. Rep.,' London, 1878, vol. xiv, p. 23.

[2] 'Med.-Chir. Trans.,' London, 1897, vol. lxxx, p. 303.

[3] In a forthcoming volume of Allbutt's System of Medicine.'

ear or nose disease. Hitherto, however, no specific micro-organism has been described, and it has even been thought that it might be due to different micro-organisms in different cases, or to such widely different agencies as traumatism and syphilis. Such a view is quite inconsistent with the clinical and pathological constancy of the disease; and the observations here recorded will, I think, tend to prove that *the simple posterior basic meningitis of infants is a specific disease, due, always and only, to a particular micro-organism.*

One further and very important point must be mentioned here, namely, that the disease referred to, although comparatively uncommon, is always prevalent, at any rate in England; and, as appears from the writings of American authorities on diseases of children, in America also.

The disease has a seasonal variation, being decidedly commoner in the spring than at any other time, but cases occur throughout the year.

During the past ten years, of forty-nine fatal cases verified by autopsy at the Hospital for Sick Children, the smallest number in any one year was two, the largest number seven, but several cases which recovered, or were not examined *post mortem*, are not included in these statistics.

All these cases, including the cases described below, were sporadic; none of them formed part of any outbreak which could be considered epidemic.

Eight consecutive cases were examined bacteriologically *post mortem*, and in seven of these the micro-organism here described was found. The first case alone proved sterile, probably for the reasons given below. The cases examined were—

Case 1.—William R—, aged 6½ months. Convulsions with rigidity began November 19th, 1896. Later, head retraction and opisthotonos; probable blindness; no optic neuritis. Head retraction varied in degree; gradual hydrocephalus; emaciation; exhaustion; death March 23rd, 1897, on the 104th day of disease.

Post-mortem.—Adhesions and fibrous thickening between medulla and cerebellum; some thickening as far forward as optic chiasma. Ventricles much dilated; vertex normal; some opacity of pia mater on spinal cord. No exudation left anywhere, only fibrous thickening.

CASE 2.—Phœbe M—, aged 10 months. Vomiting, retraction of head, and "gone blind" since April 10th. Later, fontanelle bulged, head retracted; opisthotonos; rigidity of limbs; no optic neuritis. Gradual wasting; death May 4th, the twenty-fourth day of disease.

Post-mortem.—Thickening of the arachnoid reflection between medulla and cerebellum, closing the foramina of Magendie and Luschka. Yellowish-white exudation (which in this case, as in all the others examined, was rather lymph than pus) in the meshes of the pia mater, extending forward to the optic chiasma; ventricles dilated; ependyma slightly opaque; vertex normal; exudation all over spinal cord.

CASE 3.—Edgar W—, aged 12 months; vomiting, headache, unable to sit up since May 12th. (History incomplete, and only under observation in hospital three days.) Head large, but no definite retraction; quite blind; no optic neuritis. Convulsions; death June 11th, on the thirtieth day of the disease.

Post-mortem.—Thickening of arachnoid reflection and adhesions between medulla and cerebellum. Foramina of Magendie and Luschka closed. Exudation as far forward as the optic chiasma; ventricles dilated; vertex normal; exudation all over posterior surface of cord.

CASE 4.—John F—, aged 2 years 5 months. Vomiting and convulsions April 21st. Later, retraction of head; no optic neuritis. Became comatose on May 26th, and died next day, on thirty-sixth day of disease.

Post-mortem.—Thickening of arachnoid reflection, with exudation between medulla and cerebellum; foramina of Magendie and Luschka seem to be closed. Exudation as far forward as the optic chiasma; ventricles distended; ependyma opaque; vertex normal; exudation all over spinal cord.

CASE 5.—Alice H—, aged 7 months. Convulsions and retraction of head on June 14th. Later, rigidity; extreme retraction of head and opisthotonos; blindness; no optic neuritis; death July 11th, on the twenty-seventh day of disease.

Post-mortem.—Thickening of arachnoid reflection with exudation between medulla and cerebellum; foramina of Magendie and

Luschka, and also iter a tertio closed; exudation as far forward as the optic chiasma. Ventricles dilated; exudation floating in cerebro-spinal fluid, and filling up the fourth ventricle; vertex normal; exudation on spinal cord, chiefly posterior.

CASE 6.—Alfred W—, aged 6½ months. Convulsions about June 30th, vomiting since. Later, marked retraction of head; blindness; no optic neuritis. Became semi-comatose, and died August 15th, on the forty-sixth day of disease.

Post-mortem.—Exudation over reflection of arachnoid from medulla to cerebellum, and as far forward as the optic chiasma. Foramen of Magendie probably closed; ventricles dilated; ependyma opaque; no exudation on vertex; exudation on spinal cord.

CASE 7.—Ellen B—, aged 13 months. Pain in head on May 31st, followed by convulsions and stiffness of neck. Later, marked retraction of head; opisthotonos; rigidity of limbs; blindness; no optic neuritis. Gradual emaciation; death September 11th, on the 103rd day of disease.

Post-mortem.—Slight thickening and opacity of arachnoid between medulla and cerebellum, and some adhesions here; slight thickening of pia mater in interpeduncular space. Ventricles dilated; vertex normal; very slight opacity of pia mater on spinal cord. No exudation left anywhere, only the fibrous thickening and adhesions.

CASE 8.—Edith C—, aged 5 months. Date of onset uncertain, probably about September 16th. Bulging fontanelle, blindness, no definite optic neuritis. Later, marked retraction of head; wasting. Swelling and redness over metacarpo-phalangeal joint of second finger of right hand. Only under observation in hospital a few hours. Death October 18th, probably about the thirty-second day of disease.

Post-mortem.—Exudation more extensive than usual. Very thick yellowish-white exudation covering the arachnoid reflection between medulla and cerebellum, and extending forwards to the optic chiasma; foramen of Magendie probably not completely closed. Streaks of exudation along some of the vessels in sulci on vertex. Flakes of exudation in cerebro-spinal fluid of the lateral and the fourth ventricles; only slight distension of ventricles; exudation on posterior surface of cord.

In all the above eight cases, except in Case 1, the micro-organism here described was obtained, either from the exudation at the base of the brain or from the cerebro-spinal fluid. It will be seen that in Case 1 death occurred very late, when all the exudation had already disappeared and only fibrous adhesions remained.

It seems most likely that in such cases the micro-organism may have completely disappeared; hence the negative result. At that time, however, I had no experience of the micro-organism, and was not aware that it might still be found in the lateral ventricles when it was no longer present in the basal adhesions, and also that it might be necessary to take a comparatively large quantity of the cerebro-spinal fluid (2 to 3 c.c.) for distribution over the surface of the medium, owing to the scarcity of the micro-organism at so late a stage of the disease. It is, therefore, quite possible that I overlooked its presence in that case.

In six cases (2, 3, 4, 5, 7, 8) a pure growth was obtained; in Case 6, by some accident, the growth was contaminated with extraneous micro-organisms (staphylococci).

The micro-organism which was thus found in seven consecutive cases of simple posterior basic meningitis in infants, is a diplococcus.

The cocci of which it consists have their opposed surfaces usually more or less flattened, and in some cases even concave; they vary in shape from an almost complete sphere to a hemisphere, and can usually be seen to be separated by a narrow clear space; the two cocci are not always exactly equal in size.

The diplococcus is, as a rule, decidedly smaller than the pneumococcus; there is, however, some variation in its size, both in cultures and in the exudation.

There is little risk of confusing it with the pneumococcus if cultures are made, but, so far as morphology goes, it differs also in shape, for the lanceolate form so common in pneumococcus is, I think, never seen.

Both in the exudation and in cultures the resemblance to gonococcus is often striking; indeed, individual diplococci may be quite indistinguishable from gonococci.

In the exudation at the base of the brain and on the cord the diplococci may be found singly or in groups; in the latter case they are sometimes aggregated around a nucleus, as if enclosed

within a cell wall, but much more commonly they are found free, either in the exudation or in the cerebro-spinal fluid. Either arrangement may predominate in any particular case, but the intra-cellular appearance seems to be rather the exception than the rule, for most of the cases examined showed only the single free diplococci. That the one arrangement is interchangeable with the other is seen from the fact that when the diplococcus has only been found singly and free in the exudation on the brain, intra-peritoneal injection into a susceptible animal produces an exudation in which some of the cells may be crowded with diplococci. There is a tendency to grouping in pairs, so that an appearance somewhat like that of *Micrococcus tetragenus* is produced (*vide* Plate IX, fig. 2). Grown on solid media, two or even three diplococci joined end to end may occasionally be seen, but such an arrangement is rare, and appears to be quite accidental; it bears no resemblance to the streptococcic growth which is often seen in cultures of pneumococcus.

No capsule has been demonstrated in any of the cases.

The diplococcus stains easily by any of the ordinary methods (I have used a saturated aqueous solution of methylene blue in most cases). It does not stain by Gram's method. It may seem hardly necessary to point out a possible source of error here, but as it has more than once misled me I venture to mention it in this connection. In staining cover-glass preparations of the diplococcus, great care must be taken not to leave them in the anilin-gentian-violet more than from a half to one minute; otherwise decolorisation may be very slow, and the diplococcus may be wrongly supposed to stain by Gram's method. It seems possible that in some of the cases in which only cover-glass preparations have been made, the supposed presence of pneumococcus may be attributed to this fallacy.

The diplococcus is aërobic, and grows well at a temperature of about 37° C.; no growth occurs at the ordinary temperature of the room. Agar-agar or glycerine-agar may be used as media; on either of these growth is rapid, and in sub-cultures may be recognisable within four hours. If some of the exudation from the brain be smeared on these media, from a case in which the diplococci are scanty, the growth may not be apparent for thirty-six hours or even longer, but more often the growth is visible in about twelve hours as small, slightly raised, greyish-white colonies, viscid

DESCRIPTION OF PLATE IX.

Fig. 1 illustrates Mr. Percy Furnivall's Report on a case of Acromegaly. (Page 204.)

The lower jaw from a case of acromegaly. A massive rough bone with a very obtuse angle.

Figs. 2 and 3 illustrate Dr. George F. Still's paper on "The Bacteriology of the Simple Posterior Basic Meningitis of Infants." (Page 313.)

FIG. 2.—From a photograph of the diplococcus found in the simple posterior basic meningitis of infants. Thirty-one hours' growth on blood agar (Case 5). (× 1000.)

FIG. 3.—From a photograph of growth of the diplococcus which is found in the simple posterior basic meningitis of infants. Agar-agar.

Fig. 1.



Fig. 2.

Fig. 3.

in consistency and tending to run together to form larger, irregular, rosette-shaped patches. In streak sub-cultures the growth consists of a slightly raised greyish-white streak, with a tendency to beading at the margin (Plate IX, fig. 3).

The growth is much thicker and more opaque, and the colonies are larger than those of pneumococcus.

On blood-agar, that is, agar on the surface of which a thin layer of sterilised blood has been smeared, growth is rapid and more profuse than on the other media mentioned; it forms a thick white opaque layer like paint, quite different from the usual appearance of pneumococcus on that medium.

On blood serum growth is very scanty. The addition of a trace of sulphuric or lactic acid to agar-agar or glycerine-agar prevents growth on these media.

There is no growth on gelatine at the ordinary temperature of the room; and no growth occurs on potato, even in the hot incubator. In broth this diplococcus grows well, producing in about twelve hours slight cloudiness of the fluid, which increases until a filmy or a powdery sediment, according to the amount of growth which occurs, settles at the bottom of the tube. The growth in broth has seemed to be more abundant when the tube is occasionally shaken, so as to aërate the fluid thoroughly. The behaviour of this micro-organism in broth seems to constitute one small difference from the *D. intra-cellularis*, which, according to Weichselbaum, shows "almost no growth" in broth.

Growth is abundant in milk, but no coagulation is produced even after the lapse of weeks—a further point of distinction from the pneumococcus, which certainly often, if not usually, coagulates milk.

The most striking difference between this micro-organism and the *D. intra-cellularis*, as described by Weichselbaum, is the much greater vitality of the former. Weichselbaum lays stress upon the remarkably short vitality of the *D. intra-cellularis* as one of its chief characteristics, and states that in no case did it live beyond the sixth day; whereas in Cases 2, 3, 4, 5, and 8 the diplococcus lived thirty-three days on ordinary media (agar-agar and glycerine-agar), and at least twenty-one days in broth; in Case 7, where the micro-organism was obtained on the hundred and third day of the disease, and seemed, probably on that account, to have less vitality and to grow less luxuriantly, sub-cultures could still be made from agar-

agar or glycerine-agar growths on the twenty-fourth day, and from a broth culture on the thirtieth day. On blood-agar it lives longer, *e. g.* in Case 3 it lived forty-four days, and in Case 7 fifty-three days.

Too much importance must not, however, be attached to this difference, for it has been shown by Jaeger,[1] of Stuttgart, that the *D. intra-cellularis* has not always such a brief vitality; he found that in several cases, in an epidemic of cerebro-spinal meningitis, it lived ten to fourteen days, and in one case seventeen days on agar-agar. The medium used probably makes some difference, but as in my cases media from at least four different sources were used, the great vitality can hardly have depended entirely on the use of any particular formula of medium. The figures which I have given represent, of course, the maximum vitality; some cultures lived for a shorter time; and in any case where the vitality was retained after the first week or two, only part of the culture, and often a very small part, remained alive.

Certain precautions are necessary in searching for this micro-organism. The ease with which accidental impurities are obtained in cultivations from the dead body is well known, and the greatest care must be taken to avoid any possible source of contamination. Another important point must be remembered, namely, that the diplococcus of posterior basic meningitis is seldom present in great numbers, so that it is quite easy to find the exudation perfectly sterile if a platinum rod be merely pushed into the exudation and then rubbed on the medium. This, no doubt, accounts for the fact that even where exudation was present, some observers have been unable to find a micro-organism. It is best to use a platinum loop, and having made a small opening with a red-hot knife in the pia mater, at the base of the brain, push the platinum loop through the opening and bring out some of the exudation; a piece as large as a pea may be used with advantage, and spread over the medium. The base of the brain is preferable to the spinal cord, as there seems to be a greater liability to contamination with extraneous micro-organisms in cultures made from the latter.

In cases where the exudation has already almost or quite disappeared, the diplococcus may be obtained from the recesses of the lateral ventricles, even when the adhesions at the base prove sterile, as in Case 7. For this purpose I have used a sterilised

[1] 'Ztschr. f. Hyg.,' Leipzig, 1895.

glass tube, drawn out into a very fine pipette, with a bulb at its middle; with this at least 1 to 2 c.c. of the ventricular fluid is withdrawn from the deepest part of the lateral ventricles, and allowed to run down into the culture tube over the surface of the nutrient medium. In this way in Case 7, nearly four months after the onset of the disease, a pure growth was obtained from each lateral ventricle.

But even with these precautions it is possible to miss the micro-organism altogether, unless several tubes are inoculated from each case. I have made, in almost every case, at least six inoculations, and in some cases two or three, or even more, have proved sterile, so that one might easily have overlooked the micro-organism altogether.

If a case could be examined shortly after the onset of the disease, no doubt the diplococcus would be present in larger numbers; but as death usually occurs several weeks after the onset, it is well always to adopt the precautions mentioned.

It may here be added that I have made repeated attempts to obtain the diplococcus from the blood during life, but hitherto without success.

It is, however, quite certain that the micro-organism is not always limited to the brain. One of the distinguishing features of this disease, wherein it contrasts markedly with the ordinary suppurative cerebro-spinal meningitis, is the absence of any affection of the thoracic or abdominal viscera; still there does occur, though rarely, an affection of the joints, or rather, to be more accurate, an affection in the neighbourhood of the joints, which consists of an inflammatory exudation just outside the capsule of the joint, and surrounding one or more of the neighbouring tendon sheaths. Usually this occurs only about one joint. I have seen it in four cases, and it affected respectively the tendon sheaths about the shoulder, those about the ankle, those about the wrist, and those about one metacarpo-phalangeal joint. In each of these cases the exudation was limited to the tissues mentioned; the joint itself was healthy.

The striking resemblance between the exudation here and that at the base of the brain in the thick, adhesive, lymph-like character common to both, and the absence of any real suppuration (for, as on the brain, the exudation is not pus, and shows no tendency to become pus), had led me to suspect that the *peri-arthritis*

of posterior basic meningitis is due to the same micro-organism that produces the meningeal exudation.

No opportunity for verifying this opinion by bacteriological investigation presented itself until the fourth case (Case 8) occurred. In this case the exudation about the tendon sheath over the right second metacarpo-phalangeal joint was examined and found to contain the same micro-organism as was present in the meningeal exudation; on culture pure growths were obtained, and it was shown to be the same micro-organism as had been found in the meninges in the previous cases of posterior basic meningitis.

It seems almost necessary to suppose that the micro-organism is conveyed by the blood in these cases of peri-arthritis, and that therefore it might, at any rate in some cases, be found in the blood during life.

The difficulty in finding it is easily understood from the results of intra-venous injection of the micro-organism in rabbits. In a rabbit which died about sixteen hours after intra-venous injection of 1 c.c. of an emulsion containing half a large agar culture, five cover-slip preparations of the heart blood showed not a single diplococcus, and even when about 0·5 c.c. of blood was spread over agar-agar only three or four colonies appeared, proving that the micro-organism was present only in very small numbers, and might have been overlooked if a small amount of blood had been used. A negative result, therefore, with the small amount of blood which can be examined clinically, cannot be accepted as proof that this micro-organism is not present in the blood.

As to the pathogenic effects of the diplococcus which is found in the posterior basic meningitis of infants, the results of inoculations cannot yet be considered conclusive. The following inoculations into mice, rabbits, and guinea-pigs were made:

Case 2.—(1) Emulsion in sterilised broth of a twenty-four hour sub-culture on blood-agar was injected under the skin at root of tail of a white mouse. The mouse seemed ailing for one or two days, taking its food badly, after the injection, but otherwise showed no ill effect.

(2) A few days later a similar emulsion was injected under the skin of the abdomen of another white mouse. No ill effects followed.

CASE 3.—(3) Emulsion of sterilised broth of a twenty-four hour growth on blood-agar injected under skin at root of tail of a white mouse. No ill effect.

CASE 4.—(4) Inoculation into peritoneal cavity of rabbit, but result useless, as culture used for inoculation was found to contain *Bacillus coli communis*, and the rabbit died of general infection with the *B. coli communis*, which was found in the heart blood.

CASE 5.—(5) Exudation and growth therefrom on agar-agar, made into emulsion with sterilised broth, and about 3 c.c. injected into the peritoneal cavity of a rabbit. No ill effect.

CASE 6.—(6) Injection into pleural cavity of a white mouse of growth on agar-agar, emulsified with sterilised salt solution. No ill effect.

(7) Injection into vein of ear of rabbit of same emulsion as in (6). No ill effect.

These two inoculations, (6) and (7), were of little value, however, for it was found that the material injected was impure, staphylococci being present.

CASE 7.—(8) and (9) Emulsion of cerebro-spinal fluid and pure growth therefrom on agar-agar, with sterilised broth, injected into peritoneal cavities of two guinea-pigs.

Both guinea-pigs seemed very ill, and refused food altogether for about twenty-four hours after the injection, but then began to take food, and recovered.

(10) and (11) Two rabbits were inoculated with the same emulsion as (8) and (9); the injection was made into one of the veins of the ear. Both rabbits seemed rather quieter than normal for about twenty-four hours after the injection, but otherwise no ill effects.

CASE 8.—(12) Broth emulsion of growth on agar-agar (thirty-six hours old) injected into peritoneal cavity of a guinea-pig. Seven hours later the guinea-pig was very ill, and death occurred probably about fourteen hours after the injection.

Peritoneal cavity contained about 1½ drms. of viscid but clear serum, with a few small shreds of lymph floating in it. There

was some whitish-yellow lymph on the lower edge of the spleen and on the omentum. There was slight pale mottling of the liver.

The serous exudation was found to be crowded with diplococci, and pure cultures were obtained therefrom. The heart blood, tested by culture, was found to be sterile.

(13) Same emulsion as in (12), *i. e.* about half a large growth on agar-agar, injected under skin of ear of rabbit close to vein. No ill effects observed.

(14) Serum, ¾ c.c., from peritoneal cavity of guinea-pig (12) injected into peritoneal cavity of another guinea-pig, with the intention of increasing the virulence of the micro-organism. No effect whatever, guinea-pig remained quite well.

(15) Serum, ¼ c.c., from peritoneal cavity of guinea-pig (12) injected into subcutaneous tissue of abdomen of rabbit. No ill effect.

(16) Broth emulsion of a four days' sub-culture on agar-agar, mixed with culture from peritoneal cavity of guinea-pig (12), and injected into peritoneal cavity of a guinea-pig (¾ c.c. used). Death occurred forty-eight hours after the injection.

Peritoneal cavity contained viscid serum, about 1 drm., with some flakes of yellowish lymph. Spleen was slightly enlarged.

The serum was crowded with diplococci, but contained also a few motile bacilli, probably from the intestine. There were some large oval and round nucleated cells in the exudation, which were crowded with diplococci, some of them closely resembling gonococci.

(17) Same emulsion as in (16) injected into vein of ear of a black rabbit. Death about sixteen hours after the injection.

Spleen slightly enlarged and soft, otherwise nothing abnormal to naked eye. Brain normal. Cover-slip preparations of heart blood showed no micro-organism, but cultures made with about ½ c.c. of the heart blood showed three or four colonies.

(18) Broth sub-culture (forty-eight hours old) injected into subcutaneous tissue of abdomen of mouse (about 1 c.c. used). No ill effect.

(19) Same sub-culture as in (18) injected into peritoneal cavity of a black-and-white mouse (about 1 c.c. used). Death twenty-two hours after the injection.

Peritoneum slightly sticky, but no lymph. The sticky exudation was found to be swarming with a pure growth of the diplococcus.

Heart blood showed a few diplococci in cover-slip preparations. Pure cultures of the diplococcus were obtained from the blood and from the peritoneum.

It will be seen that subcutaneous inoculations did not produce a fatal result in any case. Intra-peritoneal injection proved fatal in a mouse. Intra-peritoneal injection in guinea-pigs was uncertain in its result. In two cases it was fatal, in two it produced an illness which was not fatal, in one case it produced no effect. In rabbits intra-peritoneal injection produced no effect in the only case where it was tried (in Case 6 the fatal result was due to an accidental cause). Intra-venous injection in rabbits seemed uncertain in its results; in three cases no ill effects were observed; in one case it was fatal. On the whole, therefore, guinea-pigs seemed to be the most susceptible animals; but the micro-organism is also pathogenetic to mice and rabbits. In no case did any suppuration or œdema appear at the site of inoculation.

The question now arises, whether the diplococcus found in the simple posterior basic meningitis of infants is to be identified with any of the diplococci hitherto described as the cause of other forms of meningitis. From the pneumococcus it differs so widely that there can, I think, be no reasonable question of identity. The chief differences may be seen from the following comparison.

Pneumococcus.	Diplococcus of Posterior Basic Meningitis.
Average length, measured in meningeal exudation, 1·5 μ to 2·2 μ.	Average length, measured in meningeal exudation, 1·2 μ to 1·5 μ.
Often lanceolate.	Never lanceolate.
Simulates streptococcus.	Does not simulate streptococcus.
Colonies on agar-agar and glycerine-agar very minute and thin.	Colonies on agar-agar and glycerine-agar much thicker, larger, and more opaque.
Vitality very brief, about four days.	Vitality long, about four weeks.
Stains by Gram's method.	Does not stain by Gram's method.
Coagulates milk.	Does not coagulate milk.
Very virulent to mice and rabbits, even with subcutaneous inoculation.	Virulence very variable in mice, guinea-pigs, and rabbits; no fatal result after subcutaneous inoculation.

The differences from the *D. intra-cellularis*, as hitherto described in epidemic cerebro-spinal meningitis and in some sporadic cases of acute cerebro-spinal meningitis, are much smaller. They are—

the much greater vitality of the diplococcus of posterior basic meningitis, its more abundant growth in broth, and its less certain virulence. Such distinctions are, however, slight, and can hardly, I think, be considered sufficient to disprove the identity of the diplococcus of posterior basic meningitis with the *D. intra-cellularis* of epidemic cerebro-spinal meningitis. If this identity be established, the sporadic cases of simple posterior basic meningitis, which is always prevalent among infants, must be considered as sporadic cases of the disease known as "epidemic cerebro-spinal meningitis."

Clinically there are obvious objections to such a view. When epidemics have occurred they have affected sometimes only adults, and when children were affected it has often been the older children and those beyond the age of infancy; whereas posterior basic meningitis is much commoner in the first year of life than at any other time, and, even when most frequent, rarely affects children over two years old.

Moreover, some of the features which, although not constant, are usually considered to be characteristic of the epidemic disease, are lacking, namely, the herpes and the subsequent rashes. Several minor differences, such as the affection of the eyes and ears and the prominence of hyperæsthesia in the epidemic form, might be mentioned. That disease also seems to be usually much more rapid in its fatal issue than the posterior basic meningitis of infants ever is.

In their morbid anatomy there is, apparently, considerable resemblance between the two forms of meningitis. The base of the brain seems to be the seat of election for both; but while the basic meningitis of infancy is almost invariably limited to the base, ventricles, and cord, especially the region between the medulla and cerebellum, there seems, from the cases recorded, to be considerable variation in the situation and appearance of the lesion in the epidemic disease. That such differences are compatible with identity of the micro-organism seems at first sight unlikely, but is certainly not impossible.

It has been repeatedly shown that the properties of micro-organisms can be very considerably modified by simple artificial means. The resistant form of pneumococcus, described by Drs. Washbourn and Eyre,[1] in which prolongation of vitality with

[1] 'Journ. Path. and Bacteriol.,' Edin. and Lond., 1897, vol. iv, p. 394.

attenuation of virulence was artificially produced, is an instance of such modification; and it seems quite likely that the slight differences between the diplococcus of posterior basic meningitis here described and the *D. intra-cellularis* of Weichselbaum are to be explained by a natural variation of this kind. One might further suggest, that such variation having occurred in the micro-organism, the clinical and pathological differences between the sporadic and the epidemic forms of the disease have resulted. I am inclined, therefore, to regard the diplococcus which is found in the posterior basic meningitis of infants as identical with the *D. intra-cellularis* described by Weichselbaum; and the slight differences observed may, I think, be accounted for by a natural variation, analogous to the artificial variation mentioned above.

Any conclusions drawn from so small a number of observations necessarily require further confirmation, but, so far as the above facts go, they seem to point to the following conclusions:

1. The disease of infancy, recently described as simple or non-tuberculous posterior basic meningitis, is a specific disease due always and only to a particular micro-organism.

2. The micro-organism which is the cause of this disease is a diplococcus which is almost identical with the diplococcus described by Weichselbaum and Jaeger; it presents, however, some slight differences, which are probably to be accounted for by natural variation.

3. The simple posterior basic meningitis of infants must, on bacteriological evidence, be considered as a sporadic form of the disease known as epidemic cerebro-spinal meningitis, the *D. intra-cellularis* having been shown by recent observers to be the cause of some, at least, of the epidemics of that disease.

4. The peri-arthritis which occasionally complicates the simple posterior basic meningitis of infants is due to the same diplococcus that is found in the meningeal exudation.

In conclusion, I have to thank Dr. Klein and Dr. Washbourn for very kindly making the requisite inoculations, and also Dr. R. H. Crowley for much valuable assistance. My thanks are also due to Dr. Barlow, Dr. Lees, and Dr. Penrose for allowing me to make use of their cases.

October 19*th*, 1897.

2. *Experiments to determine whether sewer air will raise the toxicity of lowly virulent diphtheria bacilli.*[1]

By Samuel G. Shattock.

It has at different times been surmised by clinical observers of repute, that a causal relationship subsists between defective drainage and outbreaks of diphtheria; that is to say, that the inhalation of sewer air determines the occurrence of diphtheria.

By some it has been thought enough, in refutation of such an opinion, to point out that the infecting agent, the diphtheria bacillus, would not be conveyed in sewer air, seeing that bacilli in general are not disengaged by evaporation from the fluids in which they are growing.

There are other ways, however, in which the truth of the clinical opinion is conceivably possible, one of which is, that a non-virulent form of diphtheria bacillus, such as is present in the throat of certain persons, might in consequence of the inhalation of sewer air acquire virulence and thus become the cause of a diphtheritic lesion which, except for this other factor, would not have arisen.

Having had this possibility for some while in mind I determined to put it to the test, and although the results have proved negative they may not be without interest in eliminating one of the possible answers to this question, which they by no means exhaust.

The plan of the experiment was to grow lowly virulent varieties of diphtheria bacillus in sewer air and afterwards to test their toxicity by the usual method of subcutaneous injection on guinea-pigs.

The two bacilli used were kindly handed over to me by Professor Kanthack, and had been isolated by Dr. F. W. Andrewes from cases in St. Bartholomew's Hospital. The cases from which they

[1] The work was carried out at the conjoint laboratories of the Royal Colleges of Physicians and Surgeons, and I have to thank the director, Dr. Sims Woodhead, and Dr. Cartwright Wood for much valuable advice and help.

were obtained were ones of apparently simple sore throat, and, quoting from the paper by Dr. Andrewes in the Hospital 'Reports,' vol. xxxii, they were as follows:

CASE 1.—D. P—. Some chronic enlargement of the tonsils. March 16th, 1896.—Sore throat with slight malaise and headache.

March 17th.—No worse; temperature normal.

18th.—Temp. 99·2°; pulse 60. Tonsils enlarged, but not very red. Some scanty white specks of exudation on the left tonsil, not easily removed from the crypts. Does not feel really ill.

19th.—Temperature subnormal. Feels well. Under chlorinated soda gargle the throat has cleared. There is now no redness or exudation, and no pain on swallowing. No glandular enlargement at any time.

Cultures taken from the throat on March 18th yielded very numerous colonies of a small bacillus, which Dr. Andrewes at first hesitated to diagnose as diphtheria, though Dr. Kanthack did so. Sub-cultures on agar-agar, however, showed large clubbed bacilli, with much protoplasm segregation, in all respects typical of diphtheria; but they did not prove very virulent on animals, though local tumours were produced from which the bacilli were recovered.

Cultures taken again from the throat on March 23rd yielded no bacilli.

This patient was on two subsequent occasions under treatment for tonsillitis—in April and again in May. In April there was merely a little catarrhal inflammation of the enlarged tonsils. In May there was follicular tonsillitis, the crypts being stuffed with yellowish exudation, and the condition lasting four days, though with very little fever. No bacilli were found on this occasion.

CASE 2.—Z. P—, in March, 1896, suffered from an attack of sore throat, with transient specks of exudation on the tonsils. The temperature was never above 100°, but there was much aching of the back and limbs, a flushed face, and a little erythema about the upper arms. The possibility of scarlet fever was considered, but not entertained for long, and no peeling ensued. The sore throat lasted about a week, and cultures taken from the throat yielded no bacilli.

Six weeks later, on May 5th, the throat was sore on swallowing, but she felt perfectly well.

Seen on May 8th she had a normal temperature, and felt well, with no headache or other constitutional symptoms. The throat felt slightly sore on swallowing, and low down on the left tonsil there was a small white patch of exudation, unaccompanied by redness, swelling, or glandular enlargement. Cultures made from this patch yielded very numerous colonies of bacilli, in all respects resembling the diphtheria bacillus. Sub-cultures on agar-agar were typical. The throat was painted with peroxide of hydrogen, and by the 10th the patch had vanished.

On the 12th the throat was normal, and there was no longer soreness on swallowing. The bacilli, however, persisted in the throat.

Cultures taken on the 12th and 16th yielded bacilli in abundance. In cultures taken on the 18th and 25th they were still present, though the throat was treated after the 23rd by brushing with perchloride of mercury solution (1 in 500). In a culture taken on the 27th only one colony of bacilli grew.

A guinea-pig was inoculated with a sub-culture on May 31st. It developed a large local tumour, but recovered; the virulence was therefore slight.

These bacilli presented, it will be seen, then, the pathological and cultural characters of the *Bacillus diphtheriæ*. I further tested each by growing it in one per cent. glucose broth, to which, after forty-eight hours' incubation, it imparted a characteristic acid reaction, though before inoculation the withdrawal of a sample of the medium on the loop had shown the medium to be alkaline without being amphoteric.

The earliest cultures had given almost negative results in Prof. Kanthack's hands; but before submitting the bacilli to the action of the sewer air, a series of daily inoculations from broth tube to broth tube were carried on, in order to raise any toxicity they might possess to its acme.

The broth used throughout the experiment, both for tubes and flasks, was a single stock prepared from veal, which had been allowed to ferment, after the practice now generally adopted, in order to remove the glucose, and by so doing to reduce the amount of acid formed by the bacillus, the production of which is known to act deleteriously upon the micro-organism and to diminish the toxin elaborated by it. At the outset of the ex-

periment I supposed that sewer air might be obtained without difficulty by merely tapping a sewer. A leaden pipe was accordingly inserted through the upper way of the Kenon trap placed between the drain from the laboratories and that in the adjacent road. The connections were carefully made air-tight, and the pipe was carried into the small room devoted to the preparation of diphtheria toxin, the air in which is kept at a fairly constant temperature of between 96° and 98° F.

The air from the sewer was drawn through a pair of Duclaux flasks by means of a Geissler's water-pump.

Though it might at first appear surprising, the plan failed for want of sewer air; in other words, so well ventilated is the sewer in question, that the air drawn into the flasks was quite devoid of any foulness.

This having failed, it became necessary to improvise a badly-drained sewer by drawing air over sewage stored in two iron tanks provided with lids made to drop into a groove filled with glycerin. The sewage itself was obtained from a particularly populous locality in the neighbourhood, but so comparatively little odour was there even after several days in the covered tanks, that fæcal material was added to it, the truth being that London sewage consists for the most part of water (kitchen and bath), with no large proportion of solids. To make quite certain of the passage of foul, *i. e.* fæcal, air through the flasks, I passed the air from the tanks through a capacious Wolff's bottle in the incubating room itself; this was nearly filled with untreated sewage, to which from time to time fæces were added; from this the air was conducted by means of a Y-shaped connection to a pair of flasks, which were worked through a similar connection by a single pump.

The Duclaux flasks, their arms and mouths plugged with cotton wool, were charged after sterilisation with 100 c.c. of broth, and then steamed on two successive days for an hour.

A pair of flasks were inoculated from broth tubes of the two bacilli of twenty-four hours' growth, with a single loop of unusually large size; into the mouth of each a rubber cork, dipped in sublimate solution, was inserted above the cotton wool, and after distributing the organism in the broth the two flasks were set to the pump, and the "sewer" air drawn at a moderate rate through them in such a way as to pass over the medium without passing through it.

As a control a third flask was inoculated with one of the two bacilli and connected with the same pump, but the air entering it was taken through a leaden pipe from the outside of the incubating room, being first passed through a wash-bottle of distilled water in order to render it moist; the passage of the air through the sewage in the Wolff's bottle secured the same last-mentioned purpose for the two other flasks.

It was easy to regulate the amount of air passing through the several flasks by the use of a screw clip on the india-rubber tubing connected with the pump.

A fresh series of flasks was inoculated, as a rule, about twice a week, *i. e.* as soon as growth was well declared, the inoculation being made from one set to the succeeding by means of a single loop of large size.

One result of the fæcal air was to retard the growth of the bacilli, for whilst in the control flask turbidity would quickly arise, in the others there might be none for two or three days, the growth taking the form at first of delicate colonies, adhering to the bottom of the flask. The retardation was very obvious after the renewal of the sewage in the Wolff's bottle, or after the addition of fæces to it.

The bacillus from the second case was tested after two months' prolongation of the experiment. Two c.c. of a forty-eight hours' broth tube, carried on from the first flask, were injected beneath the abdominal skin of a guinea-pig weighing 500 grms. A small swelling arose at the site of injection; this had disappeared in a few days, and no general symptoms were noticeable. Microscopic examination of a hanging drop of the tube culture showed the growth to be quite pure, as also did cover-glass preparations of a serum culture carried on from the same broth tube.

The toxicity was tested upon another guinea-pig by a subcutaneous injection from the fourth tube of a daily series carried on from the final flask which had been subjected to the action of the sewer air, and with equally negative results. On the day following the injection there was no trace of local swelling; and in both cases the animals remained well for the several weeks during which they were kept.

The result in the other flask (Case 1) was tested after four weeks' treatment with the sewer air. During this time seven successive flasks were inoculated. From the last of the series a broth

tube was carried on, and of this after forty-eight hours' incubation 2 c.c. were given subcutaneously to a guinea-pig; the result was both locally and generally negative.

The result of these experiments shows that lowly virulent diphtheria bacilli, when cultivated in broth over which fæcal air is passed, do not acquire toxic properties, even though the treatment be prolonged for a period of two months.

December 7th, 1897.

---

3. *The presence of fat in Bacillus mallei; and the infectibility of white mice, commonly stated to be immune.*

By Samuel G. Shattock.

In carrying on cultures of the glanders bacillus, the luminosity of the flame whilst sterilising the öse after use has many times attracted my attention, and was so strongly suggestive of the presence of fat that I was led to inquire whether the bacilli contained any.

This luminosity is not confined to the glanders bacillus, and examination will probably reveal fat in other bacilli than those in which its presence has already been shown. Passing by yeast, in which fat has long been known to exist, Brieger has shown its presence in the proportion of 1·74 per cent. in the dried substance of a four weeks' culture of Friedländer's pneumo-bacillus on gelatine; Nencki's analysis of mykoprotein from a mixed culture of putrefactive bacteria gave 6·04 per cent. of fat in the dry substance; and the same class of body is known to be elaborated by the tubercle, lepra, and diphtheria bacilli.

The culture on which the present observations were made was one of twelve days' growth upon potato, incubated at 37° C., and was the ninth sub-culture of an original from the horse. An öse of the growth was mixed on a cover-glass with distilled water, and at once (that is without being dried) exposed to the action of osmic acid vapour in a capsule hermetically sealed with vaseline and shielded completely from the light. Five days later a small öse of

the emulsion on the cover-glass was transferred to a second glass and examined as a hanging drop.

A close microscopic study revealed the presence of minute points of deep black colour, in many though not all of the longer bacilli. These points were circular in form, variable in size, though all of course minute, and they were as a rule irregularly disposed, without equidistance, and oftentimes occupying only part of the breadth of the bacillus. Such points occur almost solely in the longer bacilli; the shorter and most numerous rods are uniformly coloured of a pale brownish yellow, like protoplasm in general is after treatment with this reagent.

It is usual in dried cover-glass preparations of the bacillus stained with carbol fuchsin to find minute perfectly spherical or oval unstained spaces, even in quite recent cultures. These spaces resemble such as are met with in recent cultures of the cholera spirillum and other bacteria, and must be regarded as vacuoles; they want the regularity of size and disposition commonly presented by spores, and are, moreover, uncommon or somewhat rare in any given preparation; and they equally want the irregularity of the

FIG. 12.

Glanders bacilli from a potato culture of twelve days, incubated at 37° C.; a ninth sub-culture from the horse, exposed to the prolonged action of osmic acid vapour and examined in a hanging drop. The bacilli shown are the longer forms selected from different fields. They exhibit minute irregularly disposed points stained quite black with the osmic acid. (Enlarged about 1000 times.)

interspaces due to segmentation of the protoplasm which the glanders bacillus often but by no means invariably presents. In pure cultures the shorter and chief series of the bacilli may be as free of segmentation as the tubercle bacillus in a pure culture raised from the human subject. I am not as yet sure, however, that such vacuoles correspond with the minute fat droplets shown

in osmic acid preparations, or whether the droplets correspond with points which in dried and unheated preparations coloured with aniline dyes take a more highly pronounced stain than the rest of the rod.

White mice enjoy a natural immunity from glanders. So the statement invariably runs. It is not easy to understand how this dogmatic assertion has arisen, unless it is that the field mouse is so susceptible (dying in from two to eight days after inoculation) that the survival of white mice beyond this period has been taken as a proof that they are altogether immune.

Nevertheless the truth is that white mice admit of being infected without any difficulty, and that death invariably ensues. Some of the results of these experiments are shown by a series of preparations which I have lately placed in the College of Surgeons' Museum, the disease being conveyed by the subcutaneous injection of small quantities of recent potato cultures suspended in sterilised water. Death ensues in from two to three weeks, an ulcer forming at the site of inoculation.

The internal organ affected is the spleen. This becomes remarkably enlarged and the seat of many glanderous nodules. Adhesions take place between the diseased spleen and the adjacent viscera as well as with the abdominal wall. The testicles are uninvolved in all cases.

That the disease is true glanders is shown by microscopic examination of the splenic lesions, in which the bacilli are to be found in an unmixed condition. The insusceptibility of white mice is, in short, not absolute, but relative, the disease running a course which, as compared with that in the field mouse, is chronic.

When the experiment is made (of course with a properly virulent culture), the house mouse will probably be found as little strictly immune as the white—its albino variety,—though it is coupled with the latter as being altogether insusceptible of infection.

May 17th, 1898.

4. *Observations upon the distribution in the tissues of the leprosy bacillus, and upon the histogenesis of giant-cells in leprous lesions of the larynx.*

Communicated for Dr. PAUL BERGENGRÜN, of Riga, by Prof. A. A. KANTHACK.

FOR some time, indeed until recently, it was generally believed that the leprosy bacilli almost exclusively inhabit the cells of the affected tissue, and that the globi are cells stuffed with thousands and millions of bacilli. Unna,[1] however, maintained that the bacilli are to be found outside the cells in the lymphatic channels and clefts. Leloir apparently accepted Unna's view.

Dr. Paul Bergengrün, of Riga, together with Dr. Ottocar Gerich, carefully re-investigated the matter in 1894 and 1895, and published his results in the 'St. Petersburger medicin. Wochenschrift,' No. 47, p. 403, 1895. He demonstrated that the majority of leprosy bacilli, nay almost all of them, are distributed outside the cells, in the lymph channels; further, that the so-called globi are not cells, but as Unna had asserted, bacillary thrombi in the lymphatics in oblique or transverse section. He proved once and for all the correctness of Unna's view in a manner so clear that it precluded all possible doubt so far as the tissues which he examined are concerned, and in fact his researches carried more conviction than the words of Unna himself, because he employed methods familiar to all and free from objections, just or unjust. I am anxious to claim for Dr. Bergengrün what is due to him, because at the recent "Lepra-Conferenz" in Berlin, in 1897, two papers were brought forward, one by Dr. C. Herman[2] and the other by Dr. K. Dohi,[3] of Tokio, who, while giving all credit to Unna and drawing attention to the imperfection of his method of preparation, had completely overlooked the fact that before them Dr. Bergengrün had already quietly settled the matter. Dr. Bergengrün chose for his investi-

[1] 'Deutsche med. Wochenschr.,' 1886, p. 123; 'Virchow's Archives,' vol. ciii, p. 553.

[2] 'Lepra-Conferenz, Berlin,' 1897, vol. i, p. 101.

[3] Ibid., 1898, vol. iii, p. 427.

gations the larynx, for there we find a well-developed lymphatic network in a loose tissue, and at the same time this organ when affected with leprosy shows nodules and infiltrations similar to those observed in the skin. I believe that but few members of this Society have had an opportunity of seeing Dr. Bergengrün's preparations on the two occasions on which I have already demonstrated them, and since they are more convincing than those of any other observer I have not hesitated to ask his permission to show some of them here to-night.

The question to which we require an answer is the following: Where are the leprosy bacilli situated? As Herman in 1897 for cutaneous leprosy, so Bergengrün showed in 1895 for laryngeal leprosy, that in cover-glass impressions, irregular or cylindrical and sausage-shaped masses may be seen, made up of bacilli bound together into zooglœa masses, straight or tortuous, and branched, having no relation to cells, and having no cellular structure. These masses consist entirely of bacilli, and at once suggest casts of tubular structures. The cells which are found in such film preparations are generally free from bacilli, although some contain bacilli. Herman gives beautiful photographs of such bacterial casts, obtained by firmly clamping a cutaneous nodule in order to render it bloodless, and then making a free incision, in order to allow the clear fluid to escape, to which a cover-glass is lightly applied. Since all the cells in such films are well preserved, it would be futile to assert that the extra-cellular bacterial clumps or masses had been set free after an artificial rupture of the cells.

FIG. 13.

Showing bacillary masses as delicate chains or bands, running in parallel lines.

In sections of the leprous laryngeal, tracheal, or nasal mucosa the true relation of the bacilli to the tissues can be more easily made out. Here bacillary masses may be seen arranged as delicate chains or bands, often running in parallel lines through the tissue, or in thicker and coarser intra-cellular strands (Fig. 13). Often these bands or chains form a dense anastomosing network, which is readily recognised as a lymph-vascular system completely filled by the bacilli, stained with carbol fuschin. In many situations (Fig. 14) we may observe thick, compact masses of bacilli, cut more or less obliquely, lying in distinct spaces between the fibres of an almost structureless connective tissue which is poor in cells. Not a single round cell is found anywhere near these masses, so that there can be no shadow of a doubt that these masses are not intra-cellular, for to begin with they are far too big, further no nuclei are visible, and the surrounding tissue is pure fibrous tissue showing but few nuclei and no free cells. Such masses as depicted on Fig. 14, if cut transversely, would give us the appearance of a

FIG. 14.

Showing two thick compact masses of bacilli lying in distinct spaces.

"globus" or a "lepra-cell," stuffed with bacilli. But cells they are not, mainly for two reasons:

(1) These masses or conglomerations possess no nuclei, and in oblique or longitudinal section they are always ovoid or cylindrical, and by means of the micrometer screw they may be followed to the surface or into the depth as clumsy cactus-like masses of enormous size which bear not the slightest resemblance to cells.

Frequently, as is well known, large vacuoles, which remain unstained, are found in these masses, and they have often been described as degenerate nuclei; but such they cannot be, for never do they stain with nuclear or other dyes, and further by means of serial sections these vacuoles may be reconstructed, and they then appear as distinct grooves or canaliculi, continuous with the space in which the bacterial mass lies.

(2) On using the micrometer screw the "globi" or "lepra-cells" can be seen to have no cell wall or outline, but their apparent contours resolve themselves into a fringe of bacilli which often can be traced with distinct prolongations into the surrounding tissue.

Therefore, as Unna asserted, these globi are lymphatic thrombi, consisting of bacilli and their remains, zooglœa matter, and coagulated lymph.

The truth of this statement is further proved by many of Dr. Bergengrün's specimens:

(*a*) The bacillary masses, stained bright red with carbol-fuchsin, as a rule lie in hollow spaces, possessing a distinct endothelial lining. This is well shown in the drawing already alluded to (*vide* Fig. 14), but is especially well depicted in Fig. 15, which is a by

FIG. 15.

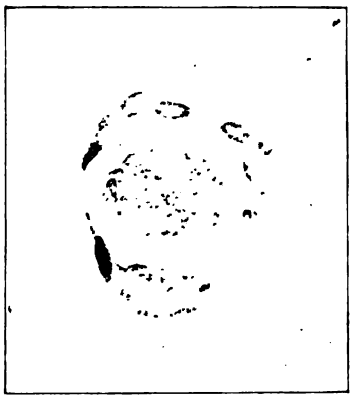

Showing a bacillary mass in a hollow space possessing a distinct endothelial lining.

no means exaggerated representation of the actual specimens, which I have most carefully examined on many occasions.

(*b*) Some specimens are of especial importance, for here we find side by side blood capillaries, easily recognised as such, filled with red corpuscles stained orange, and other circular spaces, filled with round bacterial masses stained brilliant red. The latter are lined by endothelium identical with that lining the blood capillaries, and are undoubtedly lymph capillaries.

(*c*) In some specimens (Fig. 16) we find widely dilated lymphatic vessels, lined by an endothelium which is in an active condition of proliferation.

FIG. 16.

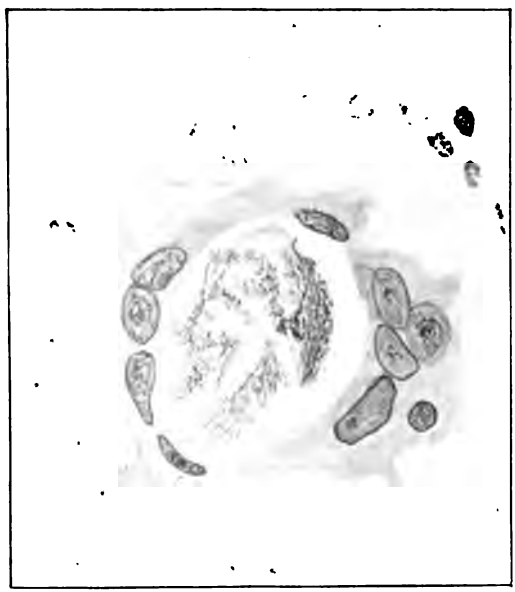

Showing a widely dilated lymphatic, containing a bacillary thrombus and lined by an actively proliferating endothelium.

(*d*) Frequently, especially on using the micrometer, we can trace smaller vessels stuffed with bacilli entering into the larger ones.

(*e*) In the vocal cords the sections show numerous, nay, as Bergengrün rightly says, innumerable longitudinal segments of what must be regarded as dilated lymphatics, all filled by bacillary thrombi and lined by endothelium, often strung together in such a manner that the greatest sceptic could have no difficulty in recognising their continuity. Such specimens are most con-

vincing, because they show us long cylindrical vessels, lined by endothelium and containing equally long cylindrical bacterial masses which in transverse section would appear as "globi" or "lepra-cells;" and in low power specimens we frequently observe a large number of cylindrical or oval bacillary masses, diverging in all directions, like vessels from a common centre.

(*f*) Where a lymphatic vessel is cut obliquely, especially in thicker sections, we can readily trace the bacillary thrombus lying under the endothelial wall where it has been obliquely cut away, which covers it like a hood; and by using the micrometer screw carefully this hood is lifted, exhibiting the bacillary mass in perfect clearness, which shows that the bacillary mass must lie in a hollow space.

Enough has been said and shown to prove that Dr. Bergengrün by his beautiful specimens has established the correctness of Unna's view, which was based upon preparations obtained by a more or less unsatisfactory method. Now it must be clearly understood that Dr. Bergengrün does not by any means assert that the leprosy bacilli are never found in cells; but he insists on this, that their intra-cellular distribution is altogether inconsiderable when compared with their distribution as thrombi within the lymphatics. With A. v. Bergmann[1] we must conclude that any one who has seen the remarkable specimens of Drs. Bergengrün and Gerich must come to the conclusion that the globi, at least an overwhelming majority of them, cannot possibly be cells, but that we are dealing with cylindrical casts lying in lymphoid spaces and vessels, *i. e.* with bacillary thrombi. It is extremely satisfactory to find that independently Drs. Herman and Dohi, studying leprous lesions in other parts of the body, have brought similar confirmation of Unna's view. Dr. Dohi, however, insists more strongly than Dr. Bergengrün upon this, that there can be no doubt that true and genuine "lepra-cells" do occur, but the "globi" he also interprets as lymphatic thrombi, and Dr. Herman maintains that though some bacilli do occur in cells, on the whole comparatively few leprosy bacilli are found in cells, and the far larger proportion occur in the lymph vessels and spaces. But it is certainly the merit of Drs. Bergengrün and Gerich to have been the first to establish the correctness of this view in a manner which must convince everybody.

[1] "Die Lepra," 'Deutsche Chirurgie,' 1897, pp. 53, 54.

Giant-cells in leprosy.—But Dr. Bergengrün's work requires still further recognition, for he has studied in an equally unequivocal manner the giant-cells of leprosy and their histogenesis, and undoubtedly his researches must form a basis for all future work. Being myself engaged in an investigation upon "giant-cells," I shall not attempt here to discuss the various views and observations regarding the origin of these interesting and curious structures, but I will content myself with giving an account of Dr. Bergengrün's specimens, which leave no doubt as to the mode of development of the leprous giant-cell. His observations gain in value because independently and simultaneously they have been confirmed by Dr. Dohi.[1]

Although many observers have denied the presence of giant-cells in leprosy, and have regarded their presence as a diagnostic sign between tuberculosis and leprosy, giant-cells are fairly frequently found in leprous nodules, as I have myself always insisted upon. Dr. Bergengrün's attention was drawn to the fact that they are almost always found only in situations where the above-described bacterial masses (globi) occur, and the latter at first sight seem to lie in the substance of the giant-cells, apparently engulfed by them; in fact, many observers under the influence of the fashion of the day, would no doubt at once speak of phagocytosis.

But Dr. Bergengrün has shown clearly that there is merely a superficial semblance of an ingestion, as will become evident if we examine such specimens as depicted in Figs. 16, 17, where an active

FIG. 17.



Showing active endothelial proliferation around a bacillary thrombus.

[1] Dohi, op. cit., p. 430.

endothelial proliferation of the lymphatic wall can be observed. It is manifest that the bacterial thrombus has acted as a foreign body, and has caused an irritation which led to a proliferation of the lymphatic endothelium. The endothelial cells multiply rapidly, and by fusion form a plasmodial mass, *i. e.* we have a true "foreign body giant-cell," if I may thus translate the cumbrous German "Fremdkörperriesenzelle." The young giant-cell, as it grows inwards, must adapt itself to the outline of the vessel and the cylindrical thrombus, and insinuating itself between the vessel wall and the thrombus, gradually tends to encircle the latter. The thrombus, however, does not lie in the substance of the giant-cell, but only in apposition to it in a cup-like depression, or in the hollow of the tubular plasmodium (Fig. 18).

FIG. 18.

Showing a giant-cell with a cup-shaped depression in apposition to the bacillary thrombus.

Some giant-cells undoubtedly contain stray bacilli in their substance, but this is easily explained. During the plasmodial fusion resulting from the excessive proliferation, a few bacilli are caught and incorporated. A study of the specimens and their drawings proves convincingly that the giant-cell has grown around the thrombus, which therefore is still in the lumen of the lymphatic vessel.

The preparations show clearly that most of the giant-cells are

sessile and directly connected with the endothelial vessel lining, so that we cannot hesitate to accept the endothelial origin of these giant-cells. In some cases the giant-cell, instead of extending inwards into the lumen, expands outwards into the connective tissue. The proliferation of the endothelial cells may be so rapid and so vigorous that the thrombi are cut in pieces, so that in serial sections the bacillary thrombi can only be traced for a short distance, being interrupted after a few consecutive sections by a giant-cell, the function of the giant-cell being to absorb or destroy resistent or bulky irritants.

Unna had already some years ago pointed out that the giant-cells in leprosy grow around the bacillary masses, in the same manner as giant-cells grow around or apply themselves to foreign bodies; but his description was incomplete, and did not demonstrate the endothelial origin of the giant-cells with the same clearness as Dr. Bergengrün's specimens. Dr. Dohi at the Berlin Lepra-Conferenz gave an account of the development of giant-cells which is practically identical with Dr. Bergengrün's. He concludes that in leprosy at least one form of giant-cells arises from the lining of thrombosed lymphatics.

I do not wish to give my own views about giant-cells generally on the present occasion, nor do I wish that Dr. Bergengrün's observations should be criticised except from his own standpoint. They were directed to the histological study of leprosy, and especially of leprosy of the larynx. For the present his remarks upon the origin of giant-cells must be restricted to leprosy, and no general conclusions must be drawn regarding the histogenesis of all giant-cells. The specimens on which this paper is based are, however, so simple that they leave no doubt concerning the deductions which Dr. Bergengrün has brought forward, and they are so interesting that I trust I shall be forgiven for demonstrating them once more.

May 3rd, 1898.

5. *The pleomorphism of the common colon bacillus.*

By H. C. Haslam.

The pleomorphism of the common colon bacillus has been noted by most observers. The forms to be seen on one cover-glass are often many and various, ranging from small coccus-like forms to long thin rods; and in the same culture, at different times, different shapes have been noted—sometimes short coccus-like forms are found to be in the majority, sometimes longer rod-like forms, and in some cases threads 6 inches in length, and even spirals, have been noted. Beyond this it has been observed that bacilli from different sources, grown on similar media, differ from one another. Vincent Harris[1] isolated colon bacilli from man, the cat, rat, rabbit, and guinea-pig, and found that bacilli giving in general similar clinical reactions often differed morphologically. One kind is described as "small stout bacilli almost of coccus form," another as "large stout bacilli with no tendency to the coccus form." Gordon, on the other hand, working with some twenty kinds from different sources, found that, although differences did exist, they were ill-defined and inconstant. Be this how it may, sufficient has been said to show that the colon bacillus may vary in shape and size somewhat considerably. The object of the present inquiry is to determine what changes in shape, if any, result from changes in the nutrient medium. To this end I took one bacillus and grew it in different media of known constitution, and then compared the results. The bacillus used was from the guinea-pig; it did not liquefy gelatine; in peptonised broth it grew rapidly, with a scum on the surface and deposit at the bottom, and gave the indol reaction in a few days; in gelatine shake cultures it produced gas; it curdled milk, rendering it acid. It was motile, and in broth was pleomorphic, its length varying from 2·5 μ to ·5 μ.

The method adopted was to remove a single colony from a gelatine plate culture and place it in peptonised broth. After two to six hours the test solutions were inoculated from this broth tube, so that in each solution were placed like bacilli with a like history, and comparative results thus insured. The substances on which

[1] 'Journ. Path. and Bacteriol.,' Edin. and Lond., 1896, p. 314.

the bacillus was grown in this way were peptone, albumen, glucose, leucin, and ammonium tartrate.

Numerous experiments were made, and, with the exception of the forms grown on leucin, the morphological characters for each solution were fairly constant.

At the end of the experiments plate cultures were made, and when impurities were detected, either by plate or direct examination, the results were discarded.

I will describe the bacillus as it occurs in the different media.

In a 5 per cent. solution of Witte's peptone the bacillus grows rapidly. In twenty-four hours it presents the following characters:—In shape it is rod-like, with ends more or less rounded, in a few cases rather tapering; the sides are parallel. It is pleomorphic, size varying from tiny coccus-like forms to long rods; but the majority of forms are from 2·4 μ to 1 μ in length, and from ·6 μ to ·3 μ in thickness. Less commonly forms from 1 μ to ·6 μ by ·5 μ to ·3 μ are seen; still fewer are coccus-like forms ·6 μ to ·5 μ in diameter; while rarest of all are forms 3 μ to 5 μ in length. Bacilli are frequently seen end to end in pairs and occasionally in chains of three or four. Many, especially the smaller, are stained uniformly and appear homogeneous; but large numbers, usually the majority, are seen to be more deeply stained at the ends than in the middle. The portions at the ends which stain deeper are of varying size, and are generally less than one third of the length; they are clearly marked off from the central portion, which stains to a variable degree, sometimes scarcely at all, sometimes almost as deeply as the ends.

In a solution examined from day to day signs of a progressive degeneration are observed; irregularities of shape and staining capacity appear, and there is an increasing quantity of débris. The bacilli that remain regular in outline decrease in size, or rather there is an increase of smaller forms, so that from the tenth to the thirtieth day the majority are from 1·4 μ to ·5 μ in length, and tiny forms ·6 μ by ·3 μ are much commoner. Nearly all stain deeply at the ends, while the body is stained lightly or not at all. There are always some forms, however, that stain well and uniformly, and are of the original size; in the later stages it is only these forms which are seen to be in pairs. These forms, which get fewer and fewer, are well shown in preparations stained with methyl blue, since the great majority after about eight days do

not stain at all, so that these few normal forms are readily distinguished. This has been noted in other microbes, and Washbourn[1] remarking the fact in the case of the pneumococcus, suggests that the well-stained forms, few in number, act as spores; and the fact that in this case these are the only forms to be seen in pairs supports that view. I may add that at no time has staining for spores yielded any result.

This staining of bacilli at the ends and not in the middle is of interest, since it occurs in the majority of forms, and since it appears in quite young cultures. I have seen it as early as five hours after inoculation. If such bacilli are examined while alive, the ends appear darker and more granular than the bodies, which are translucent and homogeneous. These darker portions are rounded in shape, and are distinctly outlined from the central clearer portion; the dots at the two ends are usually equal in size, but in older cultures one may be larger than the other. They are motile, and are seen in pairs. Those bacilli, on the other hand, which show no such differentiation of parts, are dark and faintly granular throughout. The appearance suggests that there is an aggregation of certain parts of the protoplasm, parts which possess a stronger staining capacity, at either end.

In specimens stained with Ziehl's carbo-fuchsin it is seen that the bodies of the bacilli stain to a varying degree, from being almost as deeply coloured as the ends to being quite unstained, and in lightly stained specimens the contrast between ends and body is greater than in those more deeply stained.

The phenomenon has been described by Buchner and Emmerich, who showed that it could always be produced by the addition of 3 per cent. soda to the broth in which the organism was grown. And there is further evidence to show that it is due to the alkalinity of the medium. A peptone tube seven days old, markedly alkaline, in which the majority of forms showed this differentiation, was rendered acid by the addition of decinormal hydrochloric acid; after twenty-four hours there were very few bacilli that did not stain uniformly. Again, if to a series of tubes sufficient acid is added from time to time to keep them about neutral, the staining at the ends is much less marked than in control tubes not so neutralised. When the bacillus is grown on a mixture of peptone and glucose so that the solution is always acid,

[1] 'Journ. Path. and Bacteriol.,' Edin. and Lond., 1896, p. 394.

very little staining at the ends appears, the forms nearly all stain uniformly. And if bacilli from a peptone tube showing this appearance are placed in a glucose solution, in three to six hours all trace of it has disappeared; while if from this glucose solution a fresh peptone tube is inoculated, the change of structure is again produced. It may be regarded as a change in the constitution of the protoplasm of the bacillus resulting from a change in the medium, viz. from neutral to alkaline.

Grown on a 1 per cent. peptone solution the bacillus presents much the same features. It is, however, rather shorter and thinner, the majority of forms being 2·2 μ to ·8 μ long and ·4 μ to ·3 μ broad. The aggregation of staining material at the ends is much less frequently met with. The first difference may be explained by the dilution of the nutriment, the second by the solution being less alkaline; and when by the production of ammonia the solution becomes more alkaline, the appearance is quite common.

Grown on peptone anaërobically in an atmosphere of CO_2 the appearances are much the same, nor does the addition of a reducing agent such as sodium formate affect the size, shape, or constitution.

In a solution consisting of one part of egg albumen and four parts of a 1 per cent. saline solution the bacillus does not grow at all well, only a few forms being seen. In shape these resemble the peptone forms; they are rather small, however, the majority varying from 1·8 μ to ·8 μ in length by ·5 μ to ·3 μ in thickness, though larger and smaller forms may be seen. This decrease in size may be due to the fact that albumen is not such a favorable medium for the growth of this bacillus as is peptone. If a broth is added to the albuminous solution a better growth is obtained and the size of the bacillus is equal to that produced in peptone. The aggregations at the ends are not seen, except in a few cases in old tubes to which broth has been added.

A sugar solution of the following composition was used:—Five or six grams of glucose was dissolved in 100 c.c. water; to this 2 grams of prepared chalk and 1 c.c. of ordinary peptonised broth were added; here, then, there was present a very small proportion of nitrogenous matter. The bacillus grows fairly well in this solution, and always after eighteen hours large numbers are to be found. The forms are pleomorphic, but not to such an extent as

in peptone. The majority are coccus-like forms; some are square with sharply-cut sides, others are irregularly rounded, and some are almost as round as true cocci. Besides these there are many short rods or ovals, and a few rod-like forms as in peptone.

The majority are under 1 μ in length, varying from 1 μ to ·4 μ, while the thickness varies from ·7 μ to ·4 μ. There are always present forms longer than 1 μ, varying from 1 μ to 1·8 μ, but it is rare to see longer forms than this. The coccus-like forms vary from ·7 μ to ·5 μ in diameter, the extremes being from 1 μ to ·4 μ.

Comparing these shapes and sizes with those of the peptone and albumen forms, in proteid the majority are over 1 μ in length, in sugar the majority are under. In proteid the forms are two to four times as long as they are broad, in glucose they vary from being twice as long as they are broad to having equal length and breadth. In glucose, therefore, the average form is shorter and broader than in proteid.

To make sure that this change of shape was due to the presence of glucose and not to the dilution of the nitrogenous material, control tubes of peptonised broth to the same dilution (1 in 100) were inoculated. Forms were obtained rather smaller than those in peptone but alike in shape.

The glucose forms stain well and uniformly, and from day to day show very little change; examined alive the bodies seem homogeneous throughout, and slightly more translucent than proteid forms; no aggregations of protoplasm towards the ends are ever seen. Examined after four or five months the forms show much the same appearance and stain well and uniformly, as also do they in dead cultures, when only in a few forms is any irregularity seen. If in this glucose solution the amount of nitrogenous material is increased, the number of longer forms increases, and forms from 2 μ to 1 μ in length are much commoner, while the thickness remains the same. Thus in one tube of this description the average length was from 1·4 μ to ·8 μ and the thickness ·8 μ to ·5 μ. The addition of nitrogenous matter therefore increases the average length while the thickness remains the same.

In a 5 per cent. solution of ammonium tartrate with a small percentage of sodium chloride and potassium sulphate added, the bacillus grows very slowly; its growth is increased and hastened by the addition of a small amount of peptonised broth (1 c.c. to 100). The large majority of forms in this case vary from 2·5 μ to

1 μ, it being rare to find forms under 1 μ in length; the thickness varies from ·6 μ to ·3 μ. Long forms up to 3·5 μ may be seen, and in old tubes there are filaments. They stain well and uniformly, and in old tubes the ends are sometimes deeper stained than the bodies.

It is in this case that the greatest contrast to the sugar forms is observed. In proteid solutions there are always a number of short stout forms; here are scarcely any such forms. And it may be noted that ammonium tartrate contains a larger proportion of nitrogen than proteid.

In a leucin solution consisting of 2 per cent. leucin, ·5 per cent. of sodium chloride and potassium sulphate, the bacillus grows well, producing a turbidity in twenty-four hours, and the forms are seen to be numerous. The results in this case were rather divergent, and only a wide limit of size can be given. The length may vary from 1·8 μ to ·5 μ, the thickness from ·6 μ to ·3 μ, and perhaps those under 1 μ in length are rather commoner than those over.

Besides the above-mentioned method of inoculating a series of these different solutions from the same source, one solution was frequently inoculated directly from another. Thus glucose solutions were inoculated from a peptone two to six days old; in four to six hours all "end staining" disappeared, and the bacilli had increased in thickness but had not diminished in length; in twenty-four hours they had diminished in length and typical glucose forms were seen; a peptone solution was then inoculated from this, and in twenty-four hours typical peptone forms were seen. In this way one solution was inoculated from another and generally the character of the bacillus was changed in twenty-four hours. In the case of some bacilli grown on sugar for four to five months the alteration on introduction into other media took a little longer.

Summary and Conclusion.

These results may be summed up by saying that in such nitrogenous media as proteid and ammonium tartrate the average length of the bacillus is greatest in proportion to its breadth; while in glucose, to which a minimum amount of nitrogenous material has been added, it is shortest; and that in leucin, which contains an amount of nitrogen intermediate between the first two groups, the bacillus is intermediate in size. While if in the glucose solutions

the nitrogenous material is increased, there is an increase of longer forms.

It may be concluded, generally, that changes in the composition of the nutrient medium produce changes in shape, size, and structure in the bacillus, and that increase of nitrogenous matter, so far as these experiments are concerned, causes increase in length, while increase of carbohydrate causes increase of breadth and decrease of length.

I beg to thank the Royal Colleges of Physicians and Surgeons for permission to work in their laboratories, and Dr. Woodhead for his kindness in giving me advice and assistance.

December 7th, 1897.

---

6. *Colon bacillus grown on glucose with very small amount of nitrogenous material.* (*Card specimen.*)

By H. C. Haslam.

Size, majority under 1 μ (1 μ to ·5 μ) in length by ·7 μ to ·4 μ in thickness.

Shown as a contrast to colon bacillus when grown on peptone or ammonium tartrate, when forms are mostly over 1 μ in length (2·5 μ) by ·6 to ·3 μ.

December 7th, 1897.

---

7. *Inguinal glands* (*enlarged*) *from a case of Indian plague; portion of spleen of same case showing infarction.* (*Card specimen.*)

By T. Strangeways Pigg.

The above specimens were received from Surgeon Captain Leumann, of the Indian Medical Service. They are from a native who died of the disease.

November 16th, 1897.

XI. MISCELLANEOUS COMMUNICATIONS.

1. *The action of cobra poison on the blood: a contribution to the study of passive immunity.*

By J. W. W. Stephens, M.B., and W. Myers, M.A., M.B.

(From the Pathological Laboratory of the University of Cambridge.)

The exact action taking place between a toxin and an antitoxin is still unknown, and more or less a matter of conjecture. Some observers, as, for instance, Roux and Metschnikoff, believe that an antitoxin can neutralise a toxin only in the presence of living cells, *i. e. in corpore*, and that *in vitro* it does not affect the toxin. Others, and notably Ehrlich, believe that when toxin and antitoxin come together, a chemical reaction takes place in the test-tube as well as in the body. Buchner (1) mixed tetanus toxin and tetanus antitoxin together in test-tubes in such a manner that the resulting mixture was harmless to mice, or contained even an excess of antitoxin for mice. Nevertheless he found that this mixture was still toxic for guinea-pigs. Hence he argues that in the test-tube the antitoxin does not destroy the poison. But, as Behring (2) pointed out, Buchner's experiments are not convincing, because guinea-pigs are more susceptible to tetanus toxin than mice; and Prof. Kanthack (3) expresses himself in the same sense when he says, "We must not forget that there is no absolute standard of virulence or toxic effect; that the toxic effect must naturally vary for each animal; thus, in estimating whether a poison has been rendered innocuous, we must use the most susceptible animals. We shall then find that a toxin, to which serum has been added so as to neutralise it for such animals, will be harmless for all others. A more or less refractory animal is, from its very nature, able to account for a greater or less fraction of the poison, so that the protective serum is only called upon to neutralise the surplus. This may explain Buchner's difficulty, that a mixture of tetanus

toxin and antitetanic serum, though harmless to the more refractory mouse, is still harmful to the more susceptible guinea-pig."

Roux and Calmette (4), on the other hand, have shown that if a mixture of snake venom and its antitoxin, in such proportions as to be harmless to animals, be heated to 68° C. for ten minutes, the toxic action of the snake venom reasserted itself; so that it is evident, according to them, that the poison actually existed as such in the mixture. Wassermann (5), working with pyocyaneus toxin, similarly comes to the conclusion that in a mixture of pyocyaneus toxin and pyocyaneus antitoxin, in such proportions as to be neutral for guinea-pigs, the poison remains intact, and is destroyed only after the mixture has been injected into the tissues; so that the antitoxin does not directly act upon the toxin, but only in the presence of living tissues, which liberate from the antitoxin those substances capable of neutralising the toxin.

It must be obvious that the experiments of Roux, Calmette, and Wassermann are as little convincing as these of Buchner. For toxin and antitoxin may react upon each other chemically *in vitro*, and form a physiologically neutral compound, and yet this new compound may be at once dissociated by heat, which would further destroy the antitoxin thus split off. It would not be difficult to adduce examples from chemistry to give support to our objections.

In 1896 Professor Kanthack demonstrated before the Physiological Society at St. Bartholomew's Hospital a few test-tube experiments, which proved that an antitoxin is capable of acting upon the corresponding toxin *in vitro* in the absence of living tissues. He started from D. D. Cunningham's (6) observation, that cobra poison, when mixed with shed blood in a test-tube prevents coagulation.

On adding, however, antivenomous serum to the cobra poison in proper proportions previous to mixing it with the blood, coagulation takes place as quickly as it does under normal conditions.

Again, the blood of an immunised animal mixed with a certain calculated quantity of cobra poison coagulates as rapidly as ordinary blood. There can be no doubt, therefore, from these preliminary and unpublished observations, that the cobra antitoxin is capable of acting upon the cobra poison outside the animal body. As Behring maintains, the poison is not necessarily destroyed, it is neutralised. Professor Kanthack further showed

that this action of cobra antitoxin is specific; for normal serum, diphtheritic antitoxin, and antityphoid serum had no influence over the cobra poison *in vitro*, and coagulation did not set in.

These observations cannot be explained on a mechanical basis, but we are almost forced to assume that a chemical change has taken place *in vitro* between toxin and antitoxin; and this change is a specific one. Vital influences play no part, because the experiments were performed outside the body, and coagulation is not a vital phenomenon. Here, then, we have evidence that the living organism is not a necessary intermediary for the liberation of the active molecules from the antitoxin.

In 1897 Ehrlich (7) published some important experiments, which proved, even more completely than Professor Kanthack's unpublished ones, that the toxin reacts chemically upon the antitoxin *in vitro*. His experiments were, as might be expected, most carefully thought out. Ricin produces a curious effect upon defibrinated blood, the corpuscles being firmly clumped together and precipitated. Ehrlich filled six test-tubes, each with 95 c.c. of physiological saline solution containing 0·5 per cent. citrate of sodium, and added thereto 5 c.c. of rabbit's blood. 1 c.c. of a 2 per cent. ricin solution quickly precipitates the red corpuscles. He now added to five of the above test-tubes severally, 1 c.c. of 2 per cent. ricin solution, mixed respectively with 0·3, 0·5, 0·75, 1·0, and 1·25 c.c. of diluted antitoxin, while to the sixth tube he added 1 c.c. of the ricin solution with the antitoxin. The result was that the addition of 1·25 and 1·0 c.c. of antiricin neutralised the action of the ricin in the test-tube, while 0·3 c.c. had no appreciable effect, and 0·5 merely delayed the clumping and precipitation, whereas with 0·75 c.c. the clumping was imperfect as well as delayed. He now proceeded to test these mixtures of ricin and antiricin upon mice, and found that the addition of 1·25 and 1·0 c.c. of antiricin had neutralised the ricin also for the animal; while 0·3 c.c. had no effect, 0·5 delayed death, and 0·75 c.c. weakened its action to such an extent that nothing more than a moderate infiltration resulted. It is evident, therefore, that the animal experiments confirm the test-tube experiments, and Ehrlich has thus shown that ricin and antiricin directly influence each other chemically without the assistance of cellular activity. Further (8), he asserts that by means of test-tube experiments it can be shown that toxin and antitoxin unite much quicker in

concentrated than in dilute solutions; that warming hastens this union, and cold delays it. He reminds us that analogous phenomena are readily found in chemistry, especially in the formation of double salts, and it is therefore possible that the neutralisation of toxins by antitoxins represents the formation of a double salt.

Ehrlich's views have recently received strong support through Wassermann's (9) observations upon a new method of immunisation, which consists in saturating the body with those tissue substances for which the toxin has a great affinity. Thus tetanus toxin has a strong and almost specific affinity for certain cell groups of the central nervous system, and Wassermann has shown that by mixing an emulsion of cord or brain with the tetanus toxin, either *in vitro* or *in corpore*, it is possible to bind and saturate the toxophoric atom groups of the toxin before they reach the nerve-cells of the animal. These experiments tend to show that the neutralisation of a toxin which possesses toxophoric atom groups having a strong affinity for certain tissue substances, may be effected by saturating or binding these atom groups with those substances, *i. e.* by chemical combination. This is effected inside the body as well as outside, and therefore we have some excuse for inclining towards Ehrlich's chemical reasoning rather than towards Roux's more vitalistic hypothesis.

It is evidently important, if we wish to understand the remarkable actions of antitoxins, to search, like Professor Kanthack and Ehrlich have done, for a simple reaction which can be demonstrated outside the body in test-tubes. Following, therefore, a suggestion of Professor Kanthack, to whom we are indebted for valuable advice, we determined to study by means of test-tube reactions—(1) The action of cobra poison upon blood. (2) The effect of Calmette's antitoxin upon this action, *i. e.* whether the antitoxin would, as maintained by Professor Kanthack, neutralise the poison *in vitro*. (3) It remained to be seen whether the neutralising point *in vitro* was also the absolutely neutral point *in corpore* for the animal whose blood was used in the experiment.

The Action of Cobra Poison upon the Blood *in Vitro*.

When cobra poison is added to shed blood in a test-tube, two effects are noticeable—(*a*) Hæmolysis, meaning thereby destruction

of the red corpuscles, and laking of the blood; and (*b*) delay or complete absence of coagulation. In these experiments we have chosen hæmolysis as our test reaction, leaving the observations upon coagulation for a future occasion.

PART I.—*Hæmolytic Action of Cobra Poison and the Influence of Antivenomous Serum upon this Phenomenon* in vitro.

It is well known that a solution of cobra poison has a definite action on the red corpuscle, one result of which is to liberate the hæmoglobin, so that the solution becomes laky. These observations have generally been made by mixing a little of the poison solution with a little saline solution under a cover-glass, and by subsequent examination under the microscope. The corpuscles swell, losing their biconcave form; then becoming more and more indistinguishable, till eventually they disappear. This method is not a convenient one, as it requires prolonged observation of a specimen under the microscope; besides, at best it is only a rough method, as it does not give us an accurate measure of the hæmolysis, since we do not know exactly what quantities of poison solution and blood are being employed. A more accurate method is to mix the blood and poison solutions in a hæmocytometer pipette, and then to count a given field, and from time to time to observe whether there is any change in the cells or any decrease in their number. Besides the inconvenience of keeping the same field under observation for many hours, the fact that the onset of any change at all is under certain conditions much delayed, may lead to the error of recording a really positive action of the poison as negative. The advantage of this method is that it gives us a numerical estimate of the activity of the poison. Thus, using a mixture of blood and cobra poison of varying strengths in the proportion of 1 of human blood to 200 of the poison solutions, we got the following results:

TABLE I.—*Cobra Poison in* ·5 *per cent. Saline* (1 c.c. = ·2 mgrm. of poison).

5.5 p.m.	. . .	58 red cells in 16 squares.	
5.10 „	. . .	17 „	„
5.12 „	. . .	12 „	„
5.15 „	. . .	1 „	„

TABLE II.—*Cobra Poison in ·5 per cent. Saline* (1 c.c. = ·1 mgrm. of poison).

11.40 a.m.	. . .	97 red cells in 16 squares.	
11.45 „	. . .	72 „	„
12.0 „	. . .	57 „	„
12.10 p.m.	. . .	31 „	„
12.20 „	. . .	26 „	„

TABLE III.—*Cobra Poison in ·5 per cent. Saline* (1 c.c. = ·05 mgrm. of poison).

10.45 a.m.	. . .	132 red cells in 16 squares.	
11.32 „	. . .	99 „	„

The last example shows that the action is slow with dilute poison solutions,—further on we shall show that the result may be even longer delayed.

The initial number of red cells in these examples—58, 97, and 132—also gives us some idea of the relative activity of the solutions of different strength; and further, the rate of diminution shows us the same: thus, in Example 1 all the red cells had disappeared in ten minutes, whereas in Example 3 a diminution of thirty-three only had occurred in forty-seven minutes.

The observation of the effects of small quantities of the poison we think can be most satisfactorily conducted by making the mixtures in small test-glasses. The mixtures are allowed to stand for some hours—generally twelve hours—and it is then observed whether the fluid above the corpuscles is tinged with hæmoglobin or not: in doubtful cases we employed the spectroscope.

Keeping in mind, however, the fact fully elaborated by Hamburger (10), that blood is laked by distilled water and saline solution, which are hypotonic with regard to the red corpuscles, it is necessary, moreover, that the poison should be dissolved in solution which is isotonic or hypertonic for the particular blood under observation, in order that the effect of the poison alone may be estimated.

The following table gives the equivalent isotonic solutions for the various samples of blood tested:

TABLE IV.

Animal.	Salt per cent.	Animal.	Salt per cent.
Rabbit	·5 —·6	Toad	—·3
Guinea-pig	·45—·5	Rabbit	·5—·6
Dog	·45—·5	Cat	·5—·6
Man	·45—·5	Snake	—·4
Fowl	·3 —·4	Rat	·4—·5
Frog	·1 —·2		

Hence, for instance, in comparing the action of poison solutions on frog's blood and human blood, the solutions must be made respectively in ·2 per cent. saline and in ·5 per cent. saline.

Nor must the solutions be strongly hypertonic, for, with poison solutions of a certain strength, no hæmolysis may be obtained if a 1 per cent. salt solution be employed, whereas in an isotonic solution hæmolysis is active. Thus, using 1 per cent. saline as the diluent, the following result on the different bloods was observed:

TABLE V.

Poison actually present.	Dog.	Guinea-pig.	Frog.	Man.
·5 c.c. = ·02 mgrm.	Complete H.	H. incomplete	Complete H.	No H.
" = ·01 "	Much H. deposit	Trace	No H.	"
" = ·005 "	"	No H.	"	"
" = ·0025 "	H. deposit	"	"	"
" = ·00125 "	H. slight	"	"	"
" = Saline 1 per cent.	No H.	"	"	"

Note.—To each tube a standard platinum loop full of blood is added and shaken up, and after standing twelve hours the observations are recorded.

H. = hæmolysis. "Complete" signifies that after standing twelve hours there was no sediment at the bottom of the tube. "Trace" generally implies that a spectroscope was necessary to detect the hæmoglobin in solution.

Thus we see that a 1 per cent. solution containing ·02 mgrm. does not hæmolyse man's blood, while if a ·5 per cent. solution be used, complete hæmolysis ensues (*vide* Table IX).

This result, however, must only be considered to hold good for the particular strengths of poison and saline of this experiment,

for with stronger poison solution hæmolysis will proceed in solutions of salt containing as much as 10 per cent., as the following Table shows:

TABLE VI.

	Cobra poison 1 c.c. = 2 mgrms.	Series I.	Series II.
Poison actually present	·5 c.c. = ·1 mgrm. + ·5 c.c. 20 per cent. saline	—	H. complete
	" = " + " 10 "	H. incomplete	"
	" = " + " 5 "	No H.	"
	" = " + " 2·5 "	H. incomplete	"
	" = " + " 1·25 "	H. complete	"
	" = " + " ·625 "	"	"

Taking these observations together with those recorded in Table V, they show the necessity for using isotonic solutions, or at least stating in any experiment the exact strength of the salt solution.

It is interesting in this connection to consider what the action of strong salt solutions alone is upon blood; thus:

TABLE VII.

	Series I.	Series II.
·5 c.c. 20 per cent. saline	—	H. slight
" 10 "	Slight H. in 24 hours	"
" 5 "	No H.	H. trace
" 2·5 "	"	No H.
" 1·25 "	"	"
" ·625 "	"	"

That these results cannot be attributed to bacterial action is shown by the fact of their occurring only in solutions of definite

strength, the remaining tubes showing no such change. If, however, the tubes be allowed to stand from twenty-four to forty-eight hours without taking strict aseptic precautions, they all show hæmolysis, which, however, is generally slight (11). Generally, we did not consider it necessary to take more than ordinary precautions, which were indeed sufficient, as shown by the fact that our control saline tubes, without any poison, in twelve hours never showed any hæmolysis.

Another peculiar fact we have established is, that poison solutions, containing from 2 mgrms. to 7·5 mgrms. in 1 c.c., hæmolyse blood occasionally not at all, at other times less completely, than weaker solutions do. Thus:

TABLE VIII.

Poison actually present.	Series I.	Series II.
·5 c.c. = 7·5 mgrms. . . .	No H. deposit	H. incomplete
„ = 3·75 „ . . .	„	„
„ = 1·87 „ . . .	„	„
„ = ·93 mgrm. . . .	H. complete	H. complete
„ = ·46 „ . . .	„	
„ = ·23 „ . . .	„	
„ = Saline, ·5 per cent. . .	No H.	

Solutions of a greater strength than 1 c.c. = 15 mgrms. we have not employed, and we do not propose here to discuss the reason of this phenomenon, but reserve the question for a future communication.

We found in our earlier experiments that the blood of different animals behaved differently with respect to this hæmolytic property of cobra poison, and the following results where for each blood its corresponding isotonic solution was used, were obtained for different kinds of blood:

TABLE IX.

Poison present.	Rabbit, ·6 per cent. saline.	White rat, ·5 per cent. saline.	Grass snake, ·5 per cent. saline.	Man, ·5 per cent saline.	Toad, ·3 per cent. saline.	Cat, ·6 per cent. saline.	Frog, ·3 per cent. saline.	Fowl, ·5 per cent. saline.	Guinea-pig, ·5 per cent. saline.	Dog, ·6 per cent. saline.
·5 c.c. = ·5 mgrm. . .	H.	Complete H.	C. H.	C. H.	C. H.	H.	H.	H.	C. H.	H.
„ = ·25 „ . .	Slight H.	H.	„	„	H.	„	„	„	H.	„
„ = ·125 „ . .	Trace H.	„	„	„	„	„	„	„	„	„
„ = ·0625 „ . .	No H.	Slight H.	„	„	„	„	„	„	„	„
„ = ·031 „ . .	„	No H.	Slight H.	„	„	„	„	„	„	„
„ = ·015 „ . .	„	„	Trace H.	C. H.	„	„	„	„	„	„
„ = ·007 „ . .	„	„	No H.	Trace H.	No H.	„	„	Slight H.	„	„
„ = ·0039 „ . .	„	„	„	No H.	„	H.	„	„	Slight H.	„
„ = ·0019 „ . .	„	„	„	„	„	Slight H.	H.	Slight H.	Slight H.	„
„ = ·0009 „ . .	„	„	„	„	„	No H.	Trace H.	No H.	Trace H.	„
Saline	„	„	„	„	„	„	No H.	„	No H.	No H.

Note.—The double line marks the point where the H. was well marked.
The single line marks the point where the H. was very slight.

While, therefore, the isotonic point for saline solutions is identical for rat, snake, fowl, man, and guinea-pig, the isotonic point, if we may use the expression, for cobra poison is very different, as is seen by the table. Dog's blood is exceedingly sensitive to the poison; hæmolysis in this animal occurring in very dilute solution, for instance, in the strength ·5 c.c. = ·0009 mgrm.

Further, with regard to dog's blood (and the same holds for the guinea-pig), it was observed that the hæmolysis was often complete in less than one hour in the solutions of various strengths, whilst in the corresponding tubes for guinea-pig and man, hæmolysis was not apparent for three to four hours, though eventually complete.

We should point out that these numbers must not be taken as absolute, as from time to time variations occur in the minimum amounts of poison required to produce hæmolysis. These, however, are not sufficiently large to negative the general relation shown above, and may be due to changes in the poison, or the blood, or in both.

The Action of Antivenomous Serum on the Hæmolytic Property of Cobra Poison.

Note.—The serum used in these experiments was that prepared at the Pasteur Institute, Lille, by Dr. A. Calmette.

This antivenomous serum itself is hypertonic for human and guinea-pig's blood; and the isotonic point is shown by the following table:

TABLE X.

·6	antivenomous serum	+ ·4	distilled water	No H.
·55	"	+ ·45	"	"
·50	"	+ ·5	"	H. incomplete.
·4	"	+ ·6	"	H. complete.

Consequently we have used in the experiments a mixture of serum and water in the proportion of 55 : 45.

If, however, blood be added to undiluted serum, the corpuscles quickly collect at the bottom of the tube and on the sides in little granular masses, which have a peculiar brick-red colour, differing from that of a deposit of corpuscles in hypertonic saline. These masses, if examined under the microscope, are seen to con-

sist of isolated clumps, the cells in which are much distorted and elongated, and are closely adherent to one another, the appearance suggesting a kind of agglutination of the corpuscles, a phenomenon due no doubt to the fact that we are using the serum of a horse. If water be added in increasing quantities, this appearance becomes less marked, until below the isotonic point the corpuscles swell, and are finally dissolved. And these clumps can be seen under the microscope to break up, and the individual corpuscles become detached.

We now proceeded to take solutions of poison which readily hæmolyse, and to try what the action of serum was on this phenomenon, and we found that the action could be completely arrested by using definite quantities of serum.

TABLE XI.—*Cobra Poison*, 1 c.c. = ·2 mgrm., *in Isotonic Salt Solution—Human Blood.*

·5 c.c. C. P.[1]		Complete H. in 1 hour.	
„ „	+ ·001 c.c. isotonic serum	Complete H.	
„ „	+ ·025 „ „	Incomplete H.	
„ „	+ ·05 „ „	„	
„ „	+ ·1 „ „	No H.	
„ „	+ ·2 „ „	No H.	Much clumping.
„ „	+ ·3 „ „	„	„
„ „	+ ·4 „ „	„	„
„ „	+ ·5 „ „	„	„

The same results were obtained by varying the poison and keeping the serum constant.

Repeated observations show that ·1 c.c. of isotonic serum is always sufficient to stop the hæmolytic action of ·5 c.c. of a solution of poison (1 c.c. = ·2 mgrm.) on human blood.

Further, if we take multiples of these numbers, the same relation holds good.

TABLE XII.—*Cobra Poison*, 1 c.c. = ·2 mgrm.

·5 c.c. C. P.	+ ·1 isotonic serum	No H.
1 „ „	+ ·2 „	„
2 „ „	+ ·4 „	„
3 „ „	+ ·6 „	„

[1] C. P. is used for cobra poison.

These observations show that the antivenomous serum possesses the power of neutralising the hæmolytic action of cobra poison *in vitro*, in the same manner as the antiricin neutralises ricin in the test-tube.

Our next experiments were directed to ascertaining whether this counteracting effect of antivenomous serum is possessed by other horse sera, such as the antidiphtheritic, antityphoid, antistreptococcic, and antitetanic sera. That this is not so is shown by the following table:

TABLE XIII.—*Cobra Poison*, 1 c.c. = ·2 mgrm.

·5 c.c. C. P.				Complete H.
·5 „	„	+ ·1 antistreptococcic serum		„
·5 „	„	+ ·5 „	„	„
·5 „	„	+ ·5 antidiphtheritic	„	„
·5 „	„	+ ·5 antityphoid	„	„
·5 „	„	+ ·5 antitetanic	„	„
·5 „	„	+ ·1 antivenomous	„	No H.

Hence in the test-tube sera the action of a cobra antitoxin upon cobra toxin is as specific as it is in the animal body.

Correspondence between the antihæmolytic action in vitro *and the protective action of the serum* in corpore.

For a guinea-pig, weighing 250—350 grms., ·1 mgrm. of fresh poison is the minimum certain lethal dose, death ensuing in from five to eight hours.[1] Now we have shown that the hæmolytic action of this quantity of poison is completely counteracted by ·1 c.c. of isotonic antivenomous serum. And we find that when the ·1 mgrm. of poison is mixed with ·1 c.c. of isotonic antitoxin, so that the mixture has no hæmolytic power, it is never fatal to the animal. When incompletely neutralised the animal may or may not die. We may summarise our results in the following table:

[1] Professor Fraser asserts that ·2 mgrm. per 1 kilo is the minimum lethal dose, but we have found that this is by no means a certain lethal dose.

TABLE XIV.

	Animals taken (subcutaneous injection).		Deaths.
1. Mixtures of serum and poison which give no hæmolysis, *i. e.* ·1 mgrm. toxin + ·1 c.c. isotonic cobra antitoxin	12	...	0
2. Mixtures of serum and poisons which give hæmolysis, *i. e.* ·1 mgrm. toxin + less than ·1 c.c. isotonic serum	13	...	9
3. Poison controls ·1 mgrm. cobra toxin . .	13	...	13

The first group includes three cases where the amount of poison neutralised was ·15 mgrm. But when we took larger quantities of poison we found that, although neutralised as regards hæmolysis, the animals died (five out of six).

Thus 3 c.c. cobra poison (= ·6 mgrm.) + ·6 c.c. isotonic serum is a non-hæmolytic mixture; yet it is rapidly fatal to the animal. We see, then, that the correspondence only holds for the dose already mentioned; and does not obtain for multiples. We may explain this in the following way. The poison may contain, in addition to the toxic substance, which is neutralised by the anti-venomous serum, a toxic substance which is not so neutralised. C. J. Martin (13) has recently drawn attention to the fact that many snake poisons, including cobra poison, contain at least two proteid substances, of which one is coagulable and indiffusible, the other is incoagulable and diffusible.

Note.—Weir Mitchell and Reichert some years ago found that in cobra poison the proportion of coagulable to total proteid was 1·75 per cent. C. J. Martin (15) believes that so far as Pseudechis venom is concerned, the coagulable proteid is a hæmolytic poison, whilst the incoagulable one is principally a nerve-cell poison. We are not prepared as yet to discuss this matter, but must reserve it for another time.

And he has shown that whilst the latter is neutralised by the serum, the other is not. Now if this be so, it is obvious that a single lethal dose mixed with the quantity of serum necessary to neutralise the hæmolytic poison would contain only a small quantity of the other poisonous substance, whilst six times this lethal dose would contain six times as much of this other poisonous substance, which would remain active. Thus, if a single lethal dose of poison contain two substances (A and B), of which A is

present in a single lethal dose and B in sublethal quantity, then six lethal doses would contain 6 A + 6 B. Now 6 A are neutralised by the serum, while 6 B remain free and act fatally.

In a future communication we propose to deal with this side of the question; for the present we merely offer this explanation. Similar observations have been made by Wassermann (16) with regard to pyocyaneus toxin and its antitoxic serum. He found that with four times the quantity of serum necessary to neutralise 1 c.c. of strong pyocyaneus toxin, he could not neutralise twice that quantity of toxin. This he explains by assuming that twice the poison is not neutralised *in vitro*, the large quantity of toxin present paralyses the cells, so that the tissues cannot utilise the antitoxin and change it from the inactive to active form. However, he has made no attempts to analyse the pyocyaneus toxin, and presupposes that it contains a single toxic substance. It will be necessary in future to carefully analyse the toxins; for it is possible that many of these may contain several substances, some of which are not neutralised by the antitoxin. For ricin, abrin, diphtheria toxin, and tetanus toxin, the law of multiples holds good; and this may be because these substances are purer than cobra poison and pyocyaneus toxin. We purpose to come back to this point on a future occasion.

Our experiments agree so closely with those of Ehrlich on ricin and antiricin that we are forced to come to the same conclusions as he did. They show that the antitoxic serum chemically acts directly upon the toxin, and that the neutralisation point in the test-tube agrees with that in the animal body (within the limits specified above). Cellular action being excluded in our test-tube reactions, it must be supposed that the antitoxins act chemically upon the toxin, even without the assistance of the living tissues.

We may briefly summarise our results as follows:

1. Cobra poison is strongly hæmolytic *in vitro*.

2. This action is neutralised by antivenomous serum, and the action of the latter is specific.

3. For certain doses (·1 mgrm.) the measure of this neutralisation *in vitro* is a measure of the neutralisation *in corpore* for guinea-pigs.

4. The neutralisation is chemical, and not cellular or vital.

Note.—Since the above was written, a communication by H. Kossel (17) appeared, in which he shows that (1) the hæmolytic action of eel's serum can be

neutralised *in vitro* by the addition of serum of a rabbit immunised against this eel poison, *i.e.* this neutralisation strictly obeys the law of multiples *in vitro*. It further appears that recently Gley and Camus (18) have independently demonstrated the same phenomena. Their complete paper as yet has not been published.

References.

1. *Buchner.*—'München. med. Wchnschr.,' 1893, Nos. 24 and 25, S. 449—452 and 480—483.
2. *Behring.*—'Bekämpfung der Infections-Krankheiten,' Leipzig, 1894, s. 243.
3. *Kanthack.*—'System of Medicine' (edited by T. Clifford Allbutt), 1896, vol. i, p. 570.
4. *Calmette.*—'Ann. de l'Inst. Pasteur' (Paris), 1895, tome ix, p. 251.
5. *Wassermann,* 'Ztschr. f. Hyg.,' Leipzig, 1896, Bd. xxii, s. 312.
6. *Cunningham.*—'Scientific Memoirs by Medical Officers of the Army of India,' part 9, p. 1.
7. *Ehrlich.*—'Fortschr. d. Med.,' Berlin, 1897, Bd. xv, No. 2.
8. *Ehrlich.*—"Die Werthbemessung des Diphtherie heilserums," 'Abdruck aus dem klin. Jahrb.,' Jena, 1897, Bd. vi, s. 13.
9. *Wassermann.*—'Berl. klin. Wchnschr.,' 1898, No. 1, ss. 4 and 5.
10. *Hamburger.*—For reference, see Von Limbeck, 'Grundriss einer Klin. Pathologie des Blutes,' Jena, 1896, Aufl. 2, ss. 158—166 and ss. 26 und 57.
11. *Vaquez.*—'Compt. rend. Soc. de Biol.,' Paris, 1897.
12. *Fraser.*—"An Address at the Royal Institution," March 20th, 1896, 'Nature,' 1896, vol. liii, p. 571.
13. *C. J. Martin.*—Roy. Soc. New South Wales, August 5th, 1896; 'Intercolonial Med. Journ. Australasia,' August 20th, 1897.
14. *Weir Mitchell and Reichert.*—'Smithsonian Contributions to Knowledge,' 1886, vol. xxvi.
15. *C. J. Martin.*—Roy. Soc. New South Wales, August 5th, 1896.
16. *Wassermann.*—'Ztschr. f. Hyg.,' Leipzig, 1896, Bd. xxii, ss. 312 und 313.
17. *H. Kossel.*—'Berlin. klin. Wchnschr.,' 1898, Bd. xxxv, No. 7, s. 152.
18. *Gley and Camus.*—'Semaine méd.,' Paris, February 2nd, 1898.

2. *A preliminary note on the antidotal properties of normal tissue emulsions with respect to cobra poison.*

By W. Myers, M.B.

It may be said, speaking generally, that every antitoxin is specific, so much so, that in order to explain their formation, some authors have supposed that they are merely some modifications of the toxins, caused by the inoculated organism. This view presents several difficulties; and Ehrlich (1) to account for the specificity of toxin and antitoxin respectively, put forward the hypothesis that each toxin combines chemically with some cell substance in the body of the susceptible animal, and that the combination is the cause of the symptoms of the intoxication, and of the appearance of antitoxin in the blood. This theory has recently received striking confirmation in the observations of Wassermann and Takaki (2), Metchnikoff (3), Blumenthal (4), and Knorr (5). These authors agree that tetanus poison—which acts specifically on certain portions of the central nervous system—when mixed with an emulsion of the spinal cord, or of the cerebral cortex of a susceptible animal, no longer produces tetanus. Wassermann believes, for several reasons, that a chemical combination occurs *in vitro* between the tetanus toxin and the nervous emulsion.

Cobra poison being a specific toxin which by repeated graduated injection leads to a formation of antitoxin, a search for antitoxic properties in the tissues of a susceptible animal was undertaken. For this purpose guinea-pigs were used, on which animals also the inoculations were performed. The animals were quickly decapitated, and as much blood as possible expressed from the abdomen and thorax. Though the organs were not completely free from blood, they contained less than normally. The organs to be examined were rapidly removed, weighed, and ground up by hand with sterilised saline solution (0·5 per cent.). In each case a 10 per cent. emulsion was made. A dose of venom was then added, and the mixture at once injected subcutaneously. The animals tested weighed between 250 and 350 grms., the dose of poison being 0·15 mgrm., the minimal certain lethal dose having

previously been determined as 0·1 mgrm. for animals of this weight. The control animals died in from two to four hours. With the exception of one experiment in which the cerebral cortex was used, and in which the animal survived the inoculation two days, the only organ which was found to prevent or delay death from the cobra venom was the supra-renal capsule. As this result with the cerebral cortex was not obtained again, the animals dying as quickly as the controls, I am inclined to discard it for the present as being due to an experimental error; though it must be remembered, as Phisalix (6) has recently shown, that cholesterin when inoculated in sufficient quantity may prevent death from a dose of cobra poison which is not much above the certainly lethal.

The following table is a summary of my experiments with the supra-renal capsules of the guinea-pig:

Mixture injected.	Result.
1. 0·5 c.c. C. P.[1] + 0·17 gr. supra-renal guinea-pig	No symptoms; lived.
2. " " + 0·13 " " "	Slight symptoms in 6 hours; lived.
3. " " + 0·025 " " "	Found + in 13 hours.
" " + 0·05 " " "	Found + in 13 hours.
" " + 0·1 " " "	Lived 36 hours.
" " + 0·2 " " "	+ after 3 days from sepsis.
4. " " + 0·7 " " "	Slight symptoms in 7 hours; + in 13 hours.
5. " " + 0·58 " " "	No symptoms in 6 hours; found + after 20 hours.
6. " " + 0·34 " " "	No symptoms; lived.
7. " " + 0·56 " " "	Found + after 14 hours.

[1] C. P. = cobra poison; 1 c.c. = ·3 mgrm.

From this table it is seen that out of seven experiments four were positive and three negative. Of the latter, in one case the symptoms after seven hours were trivial, though the control died in two and a half hours; in the other two cases there were no symptoms in six and three hours respectively, by which times the controls were dead, so that these results cannot be regarded as altogether negative. With emulsions from other organs and tissues, however, uniformly negative results were obtained; the animals died in about the same times as the controls. The parts which I

examined were bone marrow, cerebral cortex (positive result in one case), kidney, liver, medulla oblongata, muscle substance, ovary, serum, spleen, spinal cord, testicle, and thyroid gland.

The only other animal I have as yet tried besides the guinea-pig is the sheep, and in this case, too, the supra-renal gland, when emulsified and injected with the venom, prevented death. Further, the cortex alone was found to be active in this respect; with the medulla death occurred in the same time as in the control animal.

It is possible that the explanation of the negative results which I have obtained with the capsules of the guinea-pig lies in this fact. For in this animal not only are these glands very small, but they consist almost entirely of medulla.

April 5th, 1898.

REFERENCES.

1. *P. Ehrlich.*—" Die Werthbemessung des Diphtherie Heilsermus," 'Klinisches Jahrbuch,' 1897.
2. *Wassermann and Takaki.*—' Berl. klin. Woch.,' January, 1898.
3. *Metchnikoff.*—' Ann. de l'Inst. Pasteur,' February, 1898.
4. *Blumenthal.*—' Deut. med. Woch.,' March 24th, 1898.
5. *Knorr.*—' Münch. med. Woch.,' March 15th, 1898.
6. *Phisalix.*—' Comptes Rend. des Sci. Nat.,' December, 1897.

---

3. *Eosinophile leucocytes in the blood from a case of pemphigus.*

By J. H. DRYSDALE, M.B.

Two specimens were demonstrated: (*a*) a stained blood film, (*b*) a cover-glass film from the exposed base of one of the bullæ. Both specimens were stained with alcoholic eosin and watery methylene blue.

Clinical note.—The patient was a woman aged 61, who was admitted to St. Bartholomew's Hospital under the care of Sir

Dyce Duckworth. Three weeks before entering the hospital in September, 1897, she began to suffer from a bullous eruption which started on the arms and hands and spread to the face and trunk.

On admission there was no doubt that the patient was suffering from an attack of pemphigus. She had been in the hospital in March, 1896, for six weeks with a similar attack, and had been discharged as well.

On September 23rd a fresh crop of bullæ appeared on the feet and ankles.

Examination of the blood.—A blood count was made on September 24th with the following result:

Red blood-corpuscles per cm.	3,704,000.
Leucocytes	27,000.

A differential count of the leucocytes showed the extraordinary percentage of 69·7 of eosinophile corpuscles. Thus—

Neutrophile leucocytes . . .	19	per cent.
Large uninuclear leucocytes . .	1·2	„
Lymphocytes	10·1	„
Eosinophile leucocytes . . .	69·7	„

A second count the specimen of which was shown gave—

Neutrophile leucocytes . . .	23	per cent.
Large uninuclear leucocytes . .	2·5	„
Lymphocytes	11·5	„
Eosinophile leucocytes . . .	63	„

Ten days later, no fresh bullæ having appeared in the meantime, the count was—

Leucocytes per cm. of blood . . .	9000.

The differential count—

Neutrophile leucocytes . . .	73	per cent.
Large uninuclear leucocytes . .	4	„
Lymphocytes	15	„
Eosinophile leucocytes . . .	8	„

It has been shown by Rieder and Müller,[1] Zappert,[2] and Neusser[3] and his pupils, and others, that the eosinophile leucocytes are increased in many conditions. In childhood, in many diseases of

[1] 'Arch. für klin. Med.,' vol. xlviii, p. 96.

[2] 'Zeitschr. für klin. Med.,' vol. xxiii, p. 227.

[3] 'Wein. klin. Wochenschr.,' 1892, Nos. 3 and 4.

the skin, in disorders of the genital organs, in some bone affections, in certain cases of leukæmia, eosinophilia is commonly observed.

The increase, though relatively great, does not often reach 10 per cent. and hardly ever exceeds 20 per cent. of the total leucocyte count. Zappert,[1] in nearly four hundred observations, most of them in cases where an increase of eosinophile leucocytes might be expected, only three times found percentages exceeding 20 per cent., twice in cases of pemphigus (33 and 29 per cent.), and once in a case of ankylostomiasis (27 per cent.).

Professor Kanthack tells me that he found in several counts in a case of urticaria pigmentosa percentages ranging between 25 and 35 per cent., and in a case of pemphigus between 30 and 60 per cent.

The highest published counts of eosinophile leucocytes which I have been able to find are in two cases occurring at the Johns Hopkins Hospital, Baltimore. Thayer gives an account of these cases in the 'Lancet,' September, 1897, which is the more interesting inasmuch as the high eosinophile count in the first case led to a correct diagnosis in the second, where trichinosis had not been suspected before the blood examination.

Thayer puts forward the suggestion that the very large eosinophile count may be of value as a diagnostic point in trichinosis. This hope is, I fear, not likely to be realised in full.

It was noticed in the first of these two cases, in making a daily count, that while the percentages of lymphocytes and large uninuclear corpuscles remained fairly constant, the number of eosinophile and neutrophile leucocytes varied inversely with regard to each other. Thayer hazards the opinion that this circumstance is in favour of the direct derivation of the eosinophile leucocytes from the neutrophile.

There is another explanation, however, and that is that these cells are not eosinophile in the sense of bearing α-granules of Ehrlich, but are merely neutrophile leucocytes with their granules in an altered condition.

Professor Kanthack and Mr. Hardy, who have seen my specimens as well as those of Thayer, are very strongly of this opinion.

The nuclei of the cells in my specimen approach in character more nearly to those of neutrophile leucocytes than to the normal hæmal eosinophile, and the granules are not so regular in size, so

[1] 'Zeitschr. für klin. Med.,' vol. xxiii, p. 227.

that the cells are clearly not typical, The question must be left undecided, for at present we are not in a position to make any positive statements as to changes of nuclear form, of size, of granulation, or of staining reaction either in health or disease. Whatever their nature or significance, these eosinophile leucocytes are present in very unusual proportion in the specimen shown.

The film from the exposed base of one of the bullæ shows these leucocytes present to the almost complete exclusion of any other form.

January 18*th*, 1898.

---

4. *The serum-therapy of typhoid fever.*

By T. J. Bokenham.

In introducing this question I cannot help feeling that some of my hearers may consider me premature in talking about the sero-therapy of typhoid fever as if it were an accomplished fact, and will expect to hear from me details of the effects of serum treatment in a number of cases of the disease in man. I do not, however, on this occasion propose to deal at all with the treatment of the disease itself, as it is understood by the practitioner, because the cases at my disposal are too few to justify me in drawing sound conclusions from them. It is my object to show to the members of the Society, first, what I have been able to do in the way of artificial immunisation of large animals against the effects of inoculation with Eberth's bacillus; secondly, to briefly describe the properties of the serum from such animals, and the experiments I have made in order to ascertain those properties; and thirdly, to ask myself and others how far one is justified in applying the material at our disposal to the treatment of typhoid as it occurs in the sick-room.

Difference in principle between diphtheria and typhoid sero-therapy.—All recent researches on typhoid fever—and these are very numerous—indicate in a striking manner the necessity for drawing a clear distinction between the principles governing the serum-therapy of this disease and that of diphtheria or tetanus. In these last we have diseases the phenomena of which are

undoubtedly for the most part caused by absorption into the system of definite toxic substances. It has been shown in the most striking manner by the brilliant researches of Sidney Martin that these toxic substances can actually be recovered from the organs of patients who have succumbed to the infection,—the proof that these substances are no mere products of laboratory manipulation being afforded by the fact that when injected into animals they give rise to symptoms and pathological changes identical with those observable in the original disease. It is further possible, in both diphtheria and tetanus, to obtain the same toxic substances by artificial cultivation of the respective bacilli in various culture media and under various conditions.

In the case of both diphtheria and tetanus we are able to immunise animals against the effects both of living cultures and of their toxic products. The serum of such immunised animals is capable not only of conferring temporary immunity upon other animals against the effects both of toxin and living cultures, but has also curative powers when administered to animals already inoculated either with toxin or cultures.

What are the facts as regards the possibilities of a sero-therapy against typhoid? In the first place it must be admitted that the researches of Dr. Soltau Fenwick and myself, although they disclosed the possibility of separating from the organs of patients dead of typhoid fever substances possessing definite toxic properties, did not by any means conclusively prove that it was to these substances that the phenomena of the disease were due. In like manner, research has hitherto failed to identify in culture media which have served for the growth of typhoid bacilli any definite poison such as can without hesitation be considered the true typhoid toxin. The actual nature and properties of the toxic substances which have been actually produced by various means from old typhoid cultures need not here be considered,—the literature on this point being already sufficiently copious. Until we can not only prove the existence of definite typhoid toxins but also prepare them artificially by methods of culture, testing against these substances the action of any therapeutic serum obtained by the various immunisation investigations now in progress, we are in no sense justified in speaking of a typhoid antitoxin comparable to the antitoxins of diphtheria or tetanus. I am, however, quite unable to agree with those who say that

because we have as yet failed to produce any such serum we are therefore not justified in trying such a serum as we actually possess against typhoid fever. I think that we may fairly do so provided, first, the experimental evidence of the activity of such a serum in animals is forthcoming; secondly, if we can be sure that no harm is done by its administration; and thirdly, if we do not allow ourselves to expect more from its action on the human subject than the experimental evidence as to its action on animals leads us to hope. In fact, every patient treated with an "anti-typhoid" serum should be regarded as the subject of an experiment, and should be observed with as much care and scientific accuracy as is exercised in the case of an animal artificially infected in the laboratory.

Immunisation against the typhoid bacillus.—Glancing briefly at the history of this question, we find that in their early work Brieger, Kitasato, and Wassermann suggested an analogy between the immunity producible against tetanus and diphtheria on the one hand, and that against cholera and typhoid on the other. In all these diseases they considered the chief symptoms to be due to intoxication, and that protective sera owed their properties to antitoxic constituents. In 1892, however, Chantemesse and Widal conclusively proved that it was not possible with the means at command to protect animals against typhoid intoxication. They demonstrated, nevertheless, that the serum of patients convalescent from typhoid fever had real preventive and therapeutic properties. In the same year Bruschettini and Stern maintained that antitoxic substances existed in the sera both of immunised animals and of convalescents; their conclusions were, however, called in question by Sanarelli in 1894, who held, with Pfeiffer and Kolle, Funck, and others, that there was not as yet sufficient evidence in support of such a view. The results of my own observations compel me to endorse the opinions of Pfeiffer and of those who think with him. I regard any properties possessed by the sera on which I have myself worked as being at any rate chiefly bactericidal. That the sera obtained by me possess a real activity is apparently proved by the following experiment, carried out on the lines of a similar one made by Funck.

This experiment also shows that the serum from a "typhoid-immunised" animal has specific properties against the typhoid bacillus, which it does not display towards cultures of the *Bacillus coli.*

Methods of immunisation.—Two methods have been described. In the first of these virulent cultures are employed; the results show not only that there is great risk to both animal and investigator in using such cultures, but also that any results are obtained very slowly. The second method consists in administering to animals cultures of bacilli which have been killed by heat, chloroform, or some antiseptic. I thought it not improbable that a combination of these two methods might give results unobtainable by either alone, but while working in this direction I hit upon a plan which differs in some respects from either of them.

While engaged on the immunisation of horses against diphtheria, I was much struck by the results obtainable by the method of Dr. Cartwright Wood. This observer found, it will be remembered, that by using heated and filtered cultures of the diphtheria bacillus grown in albumen broth, not only could a high degree of resistance to diphtheria toxin be rapidly set up, but that the injections gave rise to the formation of antitoxin in the blood, without the use of any ordinary diphtheria toxin.

Such results will be very clearly shown by two charts which I now show of the temperature curves and serum activity of two animals treated by myself for a short time with nothing but killed albumen-broth cultures of a not very virulent diphtheria bacillus.

In both these animals I further found that a subsequent administration of ordinary diphtheria toxin, so far from giving an increase of antitoxic power, actually caused a fall of activity. Thus it was certain that a strong diphtheria antitoxin could be produced without the aid of either strong toxin or even very virulent cultures. Could the same thing be done in the case of typhoid? In order to investigate this point, I prepared a bouillon to which was added 10 per cent. of blood serum which had been converted into alkali-albuminate. The medium was then inoculated with virulent typhoid bacilli and incubated for three weeks, after which it was filtered through a Berkefeld filter in order to remove the bacilli.

Tested on guinea-pigs this filtrate was altogether devoid of harmful action, and gave rise to no symptoms save some rise of temperature. Chemical examination revealed the presence of some substance similar to one found by Fenwick and myself some years ago in the spleens of patients who had died of typhoid.

I then tried the effect of the filtrate on two horses. The first

horse was treated with the non-toxic filtrate, then with killed culture, and finally with alternating doses of non-toxic filtrate and of dead culture. The second horse was treated with killed culture only. While the first animal remained in excellent health and was but little affected by the injections, the second horse reacted violently to each dose. There were also corresponding differences in the sera obtained from the two animals; the first produced agglutination of a fresh typhoid culture with extreme readiness, while the second was far less active. The susceptibility to living cultures was also much less marked in horse No. 1 than in horse No. 2.

So far, then, there was some evidence that the filtrate from living cultures, although not toxic in the ordinary sense, had other properties of no less importance; an animal treated with it had become far more tolerant than a normal one to both killed and living cultures, and yielded a serum possessing strong agglutinative properties.

Had the serum of this animal any neutralising power for typhoid bacilli? To ascertain this, the dose of culture lethal to a guinea-pig was first ascertained. The test-culture was actually of such a strength that one loop of a twenty-four hour old culture would kill a 500-gramme guinea-pig with certainty in twenty-four hours or thereabouts. The inoculations were intra-peritoneal, and after death bacilli were found swarming in the peritoneal cavity.

(I would here draw attention to the great care which must be taken in making such intra-peritoneal inoculations,—a wound of the intestines would altogether vitiate the results of an experiment, so that only special blunt-pointed needles should be used, and not the ordinary hypodermic needles with sharpened ends.)

To resume; ten times the ascertained minimum lethal dose was then mixed with various proportions of serum, and the mixture injected into a carefully weighed guinea-pig. The results of the experiment showed that this, the first query, can be answered in the affirmative.

Had the serum any preventive action? This was settled by a slight modification of the experiments just described. A dose of serum which was found to be sufficient to protect when given by the "method of mixtures," was injected twenty-four, forty-eight, and seventy-two hours before inoculation of a series of guinea-pigs with ten lethal doses of culture. The result showed quite a distinct protective action in several instances. It was found, however,

that larger doses of the serum were needed in most cases to protect than when serum and infective agent were given mixed.

Had the serum any curative action? To this question also an answer in the affirmative can be given. In a number of instances I found that injections of serum, if given within two to three hours of infection with a living culture, saved the life of the animals. The dose needed was, however, large, and the results were by no means so satisfactory as when the serum was given with or before the virus.

Had the serum any action in protecting against toxic filtrates of dead cultures? My observations on this point lead me to answer in the negative, but I am not without hope that further research will yet show us the possibility of attaining such an end, although as it is, to say the least, doubtful that these toxic filtrates at all correspond with the poisons which produce the mischief in the human subject, this is perhaps of less importance than some would have us think. In experimentation with an "antityphoid" serum we are bound by the limitations to our knowledge alluded to at the commencement of this paper, and until we succeed in producing in animals a disease which more closely resembles human typhoid than does the acute disease following inoculation with typhoid cultures, I do feel that careful and accurate observation of the effect of the serum on infected patients is in competent hands most desirable and wholly justifiable. My own experiments on this question have unfortunately been for a time interrupted, but I hope soon to be in a position to continue them with renewed vigour.

January 4th, 1898.

---

5. *The serum-therapy of affections caused by infection with streptococci.*

By T. J. Bokenham.

So much has lately been written on the subject of the serum treatment of streptococcus affections, and the time of the Society is so valuable, that I shall on the present occasion do

nothing more than direct your attention to the most important of the points which I have set myself to solve by practical investigation. The history of the origin of the idea of sero-therapeutics is one which cannot even be glanced at on an occasion like the present, and I shall feel that I have done enough if I succeed in making clear to the members of the Society the general character of my own researches, and the main deductions I have felt myself justified in drawing from the experimental evidence at my own command.

The specificity of the streptococcus.—We seem as far as ever from a solution of this much vexed question. While there is little room for doubting that a given culture of the streptococcus is able under certain conditions of environment to give rise to erysipelas, and under other circumstances to pus-formation, and under yet other conditions to general septicæmia, we are still by no means justified in assuming that all streptococci are able by education or by other alterations of environment to alter their pathological characters; indeed, it seems certain that streptococci obtained from particular sources are incapable of any great or marked modification. As a striking instance of this stability of some streptococci I would mention the streptococcus associated with "strangles" in horses; this micro-organism seems to be absolutely specific for horses, and pathogenic for no other species of animals. At the same time the influence of environment on other micro-organisms is so strongly marked that it would be dangerous to assert the impossibility of at some future time modifying the pathogenic properties of even this apparently stable streptococcus.

It will thus be readily seen that a sero-therapy of streptococcal affections is by no means a simple matter, and that even if our efforts enable us to so immunise a given animal that its serum shall be protective against or curative of infection of another animal with a given streptococcus, we are still unable to assume with any degree of certainty that such a serum will be protective against infection with streptococci from another source. Herein lies, I believe, the chief source of disagreement between different observers as to the value of results obtained with the various "antistreptococcus serums" on the market.

My personal observations and experiments have led me to the clear conclusion—a conclusion, moreover, which is in accord with that of numerous other careful observers,—that the serum of a given

animal immunised against a given streptococcus may be highly efficacious in combating infection with the particular streptococcus used for the original immunisation, but that it may or may not be of any value against a streptococcus derived from a different source. I think that the only way in which we are likely to make true and substantial progress, and to place the sero-therapy of streptococcus infection on a sure and popular basis, is by endeavouring to provide a "polyvalent" serum. It is to this that I have chiefly directed my attention, and while I recognise that there is still much to be done, I feel that I have already made substantial progress towards a satisfactory solution of the question.

Immunisation against streptococci.—Various methods have been employed by different observers. While Charrin and Roger succeeded in immunising animals by the injection of cultures which had been concentrated and heated to a temperature of 115°, and had obtained from such animals a serum which was curative, their evidence on this point was not given in detail sufficient to satisfy all observers, and the publication of a communication by Marmorek, who had practically failed to obtain favorable results from treating animals with filtrates from virulent cultures, but had on the other hand succeeded in getting most striking results by treating animals with highly virulent living cultures, led to a long and heated controversy between various observers, a controversy which is raging even up to the present time. Put briefly, Roger asserts that filtrates, even after being heated, are capable of not only conferring immunity upon the animals treated with them, but also of imparting therapeutic properties to the serum of such animals; Marmorek and his followers have failed to obtain anything like such striking results from either heated or unheated filtrates, but assert that treatment by graduated doses of highly virulent streptococci has given them a serum of high therapeutic value. The good faith of both classes of observers is of course beyond question, and an explanation of the observed discrepancies will, it is hoped, be forthcoming. Both are probably near the truth, while it may well be that neither has really succeeded in identifying the actual immunising substance. Personally I am by no means sure that extreme virulence is necessary, and I think that the conditions of culture and the culture medium employed are of far greater importance than the initial extreme virulence of the streptococcus. I base this conclusion upon observations of Dr. Cartwright Wood on

the production of strong diphtheria antitoxins, which have been fully confirmed by myself, and by my own experiments on the production of an "antistreptococcus" serum. I will now give briefly the results I have obtained.

1. *Culture medium.*—This was a veal broth to which had been added varying proportions of either ascitic fluid, alkali-albumen, or asses' serum. In all cases the cultures were allowed to grow for at least three weeks, as I was thus able to secure greater uniformity of results.

2. *The cultures.*—These were obtained from a variety of sources—indeed, I considered it important to have at my disposal as many different strains of streptococci as possible. I endeavoured to immunise my animals against several species rather than against merely one kind. Their virulence was in most cases increased by the method of "passages," so that on an average it required $\frac{1}{4000}$ c.c. of a twenty-four hour old culture to kill a guinea-pig when inoculated into its peritoneal cavity, or $\frac{1}{20000}$ c.c. to kill a rabbit when inoculated by intra-venous injection.

Inoculation of these cultures produced effects as follows:

Effects of a lethal dose in the peritoneum.—1. Soon after inoculation the peritoneum contained a fluid poor in cells.

2. One or two hours later the peritoneal fluid was found to be rich in phagocytes.

3. Still later there was evidence of marked but incomplete phagocytosis—there being also numerous free streptococci.

4. The fluid became richer and richer in free streptococci, the cells staining badly, and showing a tendency to break down.

5. Still later it was difficult to find any phagocytes at all, but the number of free streptococci was large.

6. At a still later stage evidences of general infection were manifest, and at death the blood was found teeming with streptococci.

Effects of a less than lethal dose.—1. Phagocytosis rapidly complete, but inoculations with exudations gathered during the first two or three hours were still successful. In most cases protection was complete and permanent, but in some instances a re-infection took place after a longer or shorter time, with fatal result. A similar experience is recorded by Bordet in his paper in the 'Annales de l'Institut Pasteur' for 1897.

Effects of inoculation on protected animals.—In animals previously

treated with a sufficiency of serum, phagocytosis was early marked and complete, even when multiples of the lethal dose of culture were employed.

Method of immunisation; preparation of a protective serum.—The animals used were horses and asses, and they received frequent and graduated doses of liquids obtained from the cultures already described. These cultures after being incubated for three weeks were killed by an exposure for some hours to a temperature of about 55°—60° C. in a water-bath. The course of immunisation and the effects of the injection will be best followed by reference to the accompanying charts.

It will be observed that the rise of temperature following an injection was in most cases sharp, and I can only attribute the failure of Marmorek to obtain similarly striking results either to differences in the cultures used or to an insufficient dosage. It will be observed that I not infrequently gave doses as large as 600 c.c. of the immunising fluid. After a course of injections given in this manner the serum of the animals was found to possess very definite protective properties,—the activity of the serum being in all cases tested against ten lethal doses of fresh culture.

Effects following inoculation of small animals with the immunising substances.—(*a*) Fatal doses in rabbits produced acute nephritis, gastritis, with hæmorrhages into the mucosa of the pyloric end of the stomach and of the first part of the duodenum. During life the chief symptoms observed were febrile temperature, diarrhœa, loss of appetite, and paresis or paralysis of the extremities.

(*b*) With repeated small doses of the immunising substance there is produced a passing rise of temperature, and at length a complete immunity to both filtrates and living cultures. The injections must be given with great care, for if paresis be once produced by too large a dose, a fatal issue is almost invariable.

Effects of inoculation with ten lethal doses of culture in guinea-pigs previously treated with serum.—(*a*) The dose of serum is far too small. The phenomena observed in this case are first phagocytosis, then failure of that protective process, and finally general infection.

(*b*) The dose is nearly sufficient. In this case phagocytosis is energetic and complete, but after a while it becomes evident that not all the streptococci have been killed in the phagocytes, and the animal dies after a more or less chronic illness. In many of these cases it is impossible to detect any streptococci in the blood by

culture, nor does inoculation of another animal with blood from the first generally produce infection.

(*c*) The dose is sufficient. In this case phagocytosis early becomes complete, and the animal remains in perfect health.

Effects of inoculating normal and prepared rabbits by intra-venous injection.—If a normal rabbit be inoculated with a fatal dose of culture, and the dose required is in this case extremely minute, the invariable result is a general septicæmia, the blood, even after a few hours, being found teeming with streptococci. In a case of a rabbit prepared by a sufficient dose of serum, and then inoculated, streptococci may be sometimes recovered from the blood by culture if the experiment be made within half an hour of inoculation, but this result is by no means constant. At a later period the failure to obtain cultures from its blood is absolute, and the animal keeps well, there being neither rise of temperature, paresis, nor other untoward symptom, even when the standard multiple of the lethal dose has been given.

Bactericidal action of the serum.—In common with other observers who have endeavoured to demonstrate a bactericidal action of serum obtained from animals immunised in various ways against streptococci, I have been unable to satisfy myself as to the possession by my sera of any such action. Indeed, the sera act as media in which fair vegetative growths of the streptococci can be obtained, although the virulence is in great measure lost.

Agglutinative action.—I have been unable to discover the least evidence of an action of this kind. I have in like manner failed to observe any antitoxic action in these sera, the sequence of phenomena already described as following injection of immunising substances into small animals being the same, whether a fresh or a serum-treated animal be used, or even when the serum is mixed with the toxin at the time of injection.

Against living streptococci the serum has shown protective properties. It also possessed curative powers, provided that it was exhibited within four hours of inoculation, or at least the proportion of recoveries was a high one, unless cultures of extreme virulence were employed. Repeated small doses of serum were more efficacious than single large ones.

Local action of serum in man.—This question of serum in man can only be touched upon before this Society. One point, however, is so important that it must be briefly alluded to. If an

animal be bled within a day or so of its receiving a protective injection of "toxine," the serum which separates is very liable to give rise to local irritation and erythema at and around the point of injection. The curious feature of this effect is that no unpleasant symptoms may appear until some days after the injection has been made, so that it is difficult to ascribe them to the direct action of any constituent of the original serum. I am inclined rather to attribute such sequelæ to an interaction between the serum and the organism, resulting finally in the production of an irritant substance, but I must confess that the idea is at present pure theory.

If an interval of seven or eight days be allowed to elapse between the bleeding of the animal and the last immunising injection, I have found that the serum has no unpleasant effects, either local or general; I have, therefore, made it a practice to allow such an interval to elapse whenever a serum has been required for therapeutic purposes. I may mention in passing that Marmorek allows an interval of about a month to elapse between injection and bleeding his animals, in order to make sure that living streptococci are entirely absent from the blood. In my animals living streptococci are, of course, absent.

Effects of the serum on man.—In conclusion I would wish to direct the attention of the Society to the chief effects following the exhibition of the serum to patients suffering from infection with streptococci. I do not for a moment claim that the treatment is likely to be efficacious in all cases treated, but I do claim that its action is favorable in a very large proportion of cases, provided proper rules are followed in its administration. A uniformly favorable action is too much to be expected until we know a great deal more about streptococci. The rules which I myself follow when treating a case are the following:

1. Directly suspicions as to the cause of the trouble are aroused commence serum treatment.

2. As soon as possible secure a drop of blood or suspected discharge, or other matter, and submit it for bacteriological examination. No argument can be derived from the treatment of a case, however suspicious in its clinical appearances, unless streptococci are actually found to be present. Cases which have not been examined bacteriologically should in no case be quoted in statistics of treatment.

3. Give the serum in large doses and frequently. The best results have been secured from doses of 10 c.c. repeated every few hours. A larger dose than this is scarcely advisable, as it may give rise to mechanical trouble at the site of injection.

4. A positive result of bacteriological examination indicates a continuance of treatment until at least improvement is manifest. A negative result, provided the examination has been thorough, is presumptive evidence that the serum will do no good.

5. If staphylococci or other organisms, as well as streptococci, are found, the chance of success is of course far smaller.

6. As indications of favorable action I am accustomed to look for the following: loss of headache and pain, somnolence, sweating, fall of temperature after perhaps an initial rise, improved pulse, disappearance of erythema or erysipelas in the case of a superficial infection.

I have not observed any dangerous sequelæ from large doses.

Finally, I would add most emphatically that I have seen no good results whatever when minute doses or half-hearted treatment has been followed.

February 1st, 1898.

XII. DISEASES, ETC., OF THE LOWER ANIMALS.

1. *Observations on the hatching of the ova of* Bilharzia hæmatobia.

By C. G. Seligmann.

[Communicated by Samuel G. Shattock.]

The history, though not absolutely conclusive, points to the patient having acquired the disease in Mashonaland, where he habitually bathed in the streams round Fort Salisbury. He was admitted into St. Thomas's Hospital under the care of Dr. H. P. Hawkins.

Ova are passed from both the bladder and rectum; the former have in all case sa terminal spine, though the size varies somewhat, as does that of the ova. Ova with terminal and lateral spines are passed *per rectum*, the former predominating. In the ova passed *per urethram* the terminal spines are always accurately polar and perfectly straight, while in those passed *per rectum* the spine is often bent laterally, and its base slightly shifted to one side. There is also more variation in the size and maturity of the rectal ova. In a note read before the Society in 1891 (vol. xlii, p. 196) Mr. Shattock drew attention to a bladder infected with Bilharzia ova. The spines were all terminal. Sections of the polypoid rectal growths from another case also showed that the spines were terminal; while in Dr. Zancarol's case of diseased colon the spines were all lateral, in the bladder terminal. From these cases Mr. Shattock argued that "so far as the intestine is concerned, no particular position of the spine is associated with this location of the ova," a conclusion fully borne out by the present case.

The urine is alkaline and somewhat cloudy. Microscopically a fair number of ova of *Bilharzia hæmatobia* with blood-cells, oxa-

lates, and phosphates are present, forming with much granular *débris* a thick tenacious deposit not easily broken up. Tough, stringy, cast-like strands, roughly of the diameter of an ovum, are plentiful, and in these may sometimes be seen embedded at one end of their substance an ovum, which thus resembles the head of some snake-like animal, the cylindrical cast forming the body and tail. Dr. John Harley thinks "that the mucus in which the ova are embedded is derived from the crypts in which the animal takes up its abode, the growth of mucus corpuscles being due to the irritation of the parasite and its eggs. As the mucus fills the crypt it is forced out by the continual production of the ova, and is thus roughly moulded . . . . in the form of strings." The appearance above described would rather seem to suggest that in some cases at least the ova are extruded from the bladder wall by pressure of mucus *a tergo*, which being tenacious forms ropy strands of the calibre of the minute interpapillary depressions containing the irritant ova, the ulcerative process being commonly associated with papillary formation.

The ova hatched most readily in water at about 80° F. Contrary to Guillemard's experience, they were found to hatch in urine also; this took place most rapidly on the warm stage, but it was no uncommon thing to find only empty shells and a few free-swimming embryos in the urine that had stood for a few hours in the ward at a temperature of 60° to 65°.

Under these circumstances the embryoes quickly died and became disintegrated, while they could be kept alive and moving for at least twenty-four hours in water.

Before describing the process of hatching it should be stated that internal to the outer clear, probably chitinous shell from which the spine springs, there is a very delicate lining membrane. The embryo lies closely pressed against this, so that there is no peri-embryonic space in the mature but quiescent state. When the process of hatching begins the cilia at the base of the oral papilla move rapidly, and the papilla itself is protruded and withdrawn, and pushed violently from side to side. Writhing movements of the embryo, most marked in its anterior third, then take place, suggesting, according to Sandison Broch, the tearing of ligamentous attachments holding it to the shell. Meanwhile the embryo has retracted from the lining membrane of the shell, the space between becoming filled with fluid in which there are a large number of

granules, small for the most part, but some of them nearly as large as a red blood-corpuscle. Among these granules the cilia with which the embryo is covered can be seen working rapidly, causing a continuous to-and-fro highly irregular movement of the particles. By this time the peri-embryonic space has become wide enough to permit very free movement of the embryo, and the latter can be seen to contract and expand irregularly, at times becoming almost globular. In this condition it may turn completely round in the ovum, its oral papilla coming to lie in reference to the long axis of the egg, where a moment before the aboral end was situated; suddenly the shell bursts laterally and the embryo is ejected, sometimes, however, being caught in the slit when about halfway out, an hour-glass form then resulting. In this case a few more struggles generally suffice to liberate the embryo.

Sometimes, but not often, the process of hatching as just described does not take place. In these cases the embryo is instantaneously ejected through a lateral split in an apparently mature quiescent ovum, in which no peri-embryonic space filled with granules can be seen.

The free-swimming embryos progress rapidly by means of the cilia with which they are covered, and in some cases show remarkable changes in shape. Thus at times they may become almost spherical, the proboscis being completely retracted; at other times they become elongated and much narrower. These changes are probably produced by the action of the transverse and circular muscular fibres described by Guillemard.

November 2nd, 1897.

---

2. *Supernumerary dorsal fin in a trout.*

By C. G. Seligmann.

The specimen is a trout (*Salmo fario*) about 42 cm. long, caught at Martyr Worthy on the Itchen, in which there is a supernumerary fin composed of apparently ten soft fin rays, situated in the mid-dorsal line immediately behind the head, and 5 cm. in

front of the dorsal fin. All the other fins are present and normal.

As far as can be ascertained, no other example of this malformation has been met with.

FIG. 19.

The trout referred to in the text, showing supernumerary fin immediately behind the head in the median line (reduced to one half natural size).

The position of the supernumerary fin would seem to show that it is not a developmental excess comparable with supernumerary digits, but rather of atavistic significance.

It has been suggested by Ray Lankester that the archetypal fish had a median fin, stretching both dorsally and ventrally the whole length of its body. An approach to this is seen in certain extinct fringe-finned Ganoids with diphycercal tails. In these there is a continuous series of rays, stretching from end to end of the dorsal aspect of the spinal column.

In existing species of *Regalecus* the dorsal fin extends the entire length of the body, the spines of a detached portion on the head being developed into long filaments, while the most striking peculiarity of *Lophotes cepedianus* is, according to Lydekker, "the elongation of the crown of the head into a high crest, surmounted by an exceedingly long and recurved spine, forming the commencement of the dorsal fin." In the sticklebacks there are between the soft dorsal fin and the head a number of isolated fin rays which have developed into spines. Agassiz has shown that these, as well as the tentacles of *Lophius*, arise as diverticula of epiblast, in continuity with or forming the anterior portion of the median dorsal fin fold. Subsequently their proximal (basal) end becomes

invaded by mesoblast, and the whole spine or tentacle is carried forwards, reaching in the sea-stickleback (*G. spinachia*) the level of the gill covers, and occupying in *Lophius piscatorius* a position on the head anterior to the eyes, and far in advance of the position in which they were developed in the embryo. The *Balistidæ* present varying degrees of development of an anterior spiny fin in front of the soft dorsal; in *Triacanthus* there are from four to six spines united by a soft membrane, reduced in *Monocanthus* to two or one, and in *Anacanthus* to one.

FIG. 20.

Two-spined stickleback, showing separation and development of rays of dorsal fin into spines (natural size).

Finally, although there is no trace of a continuous median dorsal fin in the trout *Alevin*, the embryo gold-fish has a median dorsal fold, reaching forward to the region of the eyes, while in some eels the larva, like *Amphioxus*, has a continuous dorsal fringe, reduced in the adult to a fin beginning some distance behind the head. It would therefore seem probable that in the specimen under consideration the supernumerary fin represents an anterior part of an originally longer dorsal fin, and that this extra fin is homologous with the spiny rays of the *Gastrosteidæ*, the tentacles of *Lophius*, and the anterior spiny fin of many other fishes.

November 16*th*, 1897.

---

3. *Two examples of malformation in fish.*

By C. G. SELIGMANN (communicated by SAMUEL G. SHATTOCK).

EXAMPLES of arrest of development among fishes, with the exception of monstrous trout hatched in captivity, are rather uncommon. Very rarely the defect manifests itself in the appen-

dicular portion of the skeleton, when it is mostly bilateral. In the museum of the College of Surgeons (Terat. Ser., No. 449) there is a bream with no pelvic fins. More commonly the axial portion of the skeleton suffers, and then it is almost invariably the anterior part of the head that is malformed. This fish's head shows what at first sight seems to be an overgrowth of lower jaw, and it was for this reason that the specimen was sent me by the kindly angling editor of the 'Field,' to whom my best thanks are due. Upon dissection it is, however, evident that the fault lies with the upper jaw, which, instead of being nearly as long as the lower and slightly concave upwards, is short and markedly convex from the crown of the head to the tip of the nose. The deformity is well shown in the accompanying figure. The ethmo-vomerine plate, although somewhat shortened and bent downwards, is well formed for the greater part of its length, and bears the usual array of

FIG. 21.

teeth. The maxillæ (*mx*) and sub-maxillæ (*s*) are normal, while the pre-maxillæ (*pmx*), which in the pike bear the whole series of lateral teeth of the upper jaw, are small, and bear only a very few diminutive teeth. The pre-frontals (*prf*) are much reduced in size.

These specimens are now in the Royal College of Surgeons' Museum, London.

In the Teratological Series at the College of Surgeons there are examples of the same malformation, *i. e.* arrest in development of the ethmo-vomerine plate, in other fishes. These are for the most part more extensive, and are often associated with arrest of the lateral maxillary plates.

No. 176 is "the anterior portion of an eel with complete deficiency of the face in front of the eyes. The mandible extends beyond the anterior extremity of the truncated skull." Further, the advanced facial defect is associated with malformation of the brain. "The four anterior ganglia are much compressed from before backwards. The anterior pair of ganglia (olfactory) have displaced the second pair, and lie partially between instead of entirely in front of them." Agassiz has figured the same deformity in the trout (*Salmo fario*), but does not mention the condition of its brain, dismissing it with the description, "La tête d'un individu monstrueux dont la mâchoire supérieure et la crâne sont tronqués." Nos. 177 and 179 of the College series are examples of similar deformity, less extensive in degree, in a grilse and trout respectively. In these the maxillæ are well developed. No. 178 is a carp in which the mandible is also defective for the greater part of its length. Perhaps this apparent malformation is really traumatic in origin.

All these specimens, with the possible exception of the last, are examples of defective development of the face, and their common feature is undergrowth or hypoplasia of the elements corresponding to the ethmo-vomerine plate. In some the lateral maxillary processes are also deficient.

In the specimen under notice all the elements of the normal skull are present, and only the most anterior of these, namely, the pre-maxillæ and pre-frontals, are dwarfed; it would thus seem to be an example of late arrest, and probably corresponds to those cases in the higher mammalia where there is defective development of the pre-maxillæ with perhaps some defect in the maxillæ, giving rise to harelip. More pronounced cases of facial arrest in which the pre-maxillæ, with perhaps the pre-frontals, are absent also occur, and these seem to be equivalent to a rare form of harelip in the human subject, in which there is absence of the pre-maxillæ and overlying integuments, giving rise to a median gap in the face.

No. 206 of the College series is "a portion of the head of a

human fœtus with shortening of the whole cranio-facial axis. . . . The palate and upper lip are entirely wanting. The maxillary and naso-frontal processes remain distinct;" while in No. 207 "the premaxillary bones and the ethmo-vomerine plates are absent." These two specimens approach the condition figured by Agassiz, in which there is not only absence of that part of the face formed by the ethmo-vomerine plate growing forwards between the optic vesicles, but also of the lateral maxillary processes.

November 16*th*, 1897.

---

4. *Molluscum contagiosum of the legs and feet and head of a white Wyandotte chicken.* (*Card specimen.*)

By T. Colcott Fox, M.D.

Whilst comparatively a common affection of the head of fowls and pigeons in this country, the affection of the legs is believed to be rare. The microscopical sections were typical of molluscum contagiosum.

Fig. 22.

FIG. 23.

The brown wart-like growths are quite unlike the growths met with in the human subject.

May 17th, 1898.

---

5. *Molluscum contagiosum in two (mated) Bunting sparrows.*

By SAMUEL G. SHATTOCK.

[With Plate X, fig. 2.]

ON November 23rd, 1897, there was sent to the Royal College of Surgeons a North American Bunting sparrow which had died with a spherical swelling beneath the mandible.

An examination (Plate X, fig. 2) disclosed that this swelling is due to a median growth one centimetre in diameter. It lies immediately beneath the skin, is distinctly circumscribed, and in no way involves the jaw or floor of the mouth. In its centre there is an irregular cavity (present also in the recent state), the interior of which has a somewhat coarse, pseudo-papillary character. Considerable extravasation of blood has occurred into the peripheral part of the growth, the histological characters of which in all details resemble those of molluscum contagiosum as met with in the human subject.

Microscopically the neoplasm presents the lobulated outline so apparent in molluscous tumours, and consists of epithelium supported upon a peripheral wall and scanty septa of connective tissue. The epithelium appears in section as a cell mosaic, the most peripheral and smaller of the elements of which correspond

in size with those of the rete Malpighii, and here and there present a palisade arrangement, as in the deepest stratum of the epidermis on the overlying skin.

More centrally, *i. e.* farthest from the underlying connective tissue, the cells become considerably enlarged from the characteristic molluscous change. In their conversion into the so-called molluscous bodies the cells retain their polyhedral figure, since in spite of their enlargement they remain subject to mutual compression. The nucleus is pressed aside, and rendered concavo-convex by the formation of a vacuolated hyaline substance readily staining with eosin. The change affects chiefly the more superficial or central elements of the cell masses, *i. e.* those farthest from the complex processes of supporting connective tissue; in most cases the adventitious material does not completely fill the cell, and it varies considerably in amount. Hæmorrhage has occurred into some of the septa as well as into the connective tissue forming the general boundary of the growth.

The molluscous material itself is not stained by Gram's method, a proof that it is not eleidin, which, as I have noticed in a previous communication, is intensely dyed by the method named ("Mucosal Cysts and the Significance of the Stratum Granulosum," vol. xlviii, p. 254).

On December 29th, 1897, a second Bunting sparrow arrived at the College with a swelling somewhat in the same position, and with the interesting information that the bird was the mate of that first sent, and that the growth had been observed to develop after the death of the other, which had occurred four weeks previously. Growing from the integument in front of the left eye there is a pedunculated tumour one centimetre in chief diameter, which microscopic examination shows to be (like the preceding) a molluscum contagiosum, but without central cavity. The section displays groups of the typical molluscous bodies parted by vascular strands of connective tissue, though the superficial part is dry and necrosed from cauterisation having been practised by the owner.

In all its histological features the first growth, unchanged as it was by any treatment, resembles the human disease, where the characteristic change in the same manner affects chiefly the more central cells of the groups, and where the same increase in the intra-cellular material is to be observed with accompanying displacement of the nucleus and vacuolation of the substance

itself. The presence of a central cavity equally obtains in the human disease, whether in the larger or lesser lesions, its formation being due to discharge of the more central of the altered cells, with the resulting production of a pseudo-villous interior arising from the projection of the cell-clad processes.

In the human lesion the stratum granulosum, an extension of which is conterminous with the growth, is notably involved; the molluscous change, however, is not confined to the cells of this layer, but extends to those cells on the inner or central aspect, as well as to those on the outer or peripheral, even up to the vertical palisade series. When treated by Gram's method the molluscous material is quite decolourised, showing that it is not eleidin, as has been by some alleged. When sections are so treated the cells of the stratum granulosum, distended with the substance in question, are sharply differentiated, and appear as hollow spheres of a deep violet, the dilated cell body being crowded with minute deeply dyed granules.

The fallacy of the older opinion which regarded molluscum contagiosum as arising in the sebaceous glands, is amply shown by a consideration of its histology; not only does the presence of a deep series of vertical palisade cells, but that of eleidin-holding cells in all ways like and derived from those of the stratum granulosum, suffice for this, since none such occur in sebaceous glands. Eleidin-holding cells, however, line the hair-follicles to their deepest limits; and the theoretical conclusion that molluscum might arise either from the general rete or the hair-follicle is borne out by direct observation.

The size of the first growth (1 cm. in diameter), especially when considered with the bulk of its bearer, is somewhat unusual, but I have sections of the human lesion as much as 1·4 cm. in diameter, and under the name of molluscum giganteum considerably larger have been recorded.

The contagiousness of molluscum is now generally allowed; the direct examples of it, both clinical and experimental, being too marked for refutation. And in the two instances recorded in this communication there is little room for doubt that the second bird was inoculated from its mate; the situation of one tumour beneath the mandible, and of the other in front of the eye, is aptly explained by the less protected character of the integuments of the head, and their greater exposure to injury arising from the well-

known habits of birds, whether amatory or vindictive. Infectivity, using the term in its pathological and wider sense, as distinguished from its clinical; infectivity, it must be remembered, is in most cases a relative, not an absolute phenomenon, and a certain number of escapes after direct exposure or inoculation indicate only that the infective process is modified or abrogated by other factors. It can only be from a forgetfulness of this elementary truth that the infectivity of molluscum has been disputed; the absence of infection in certain cases where it might have been expected is allowed to outweigh all the evidence to the contrary, howsoever striking it may be; and not merely that afforded by clinical observation, but by direct experiment, both in the human subject (Vidal, 1887) and elsewhere (fowls; Bollinger, 1873).

I have identified the same disease microscopically in the common sparrow from growths about the beak, as well as in the pheasant. It is in domesticated birds, however, that the disease has been most frequently observed, and it is a fairly common one amongst fowls, turkeys, and pigeons. Its identity was established by Bollinger ('Virchow's Archiv.,' Bd. lviii, 1873), who not only determined this by histological examination, but proved its contagiousness in fowls by experimental inoculation. In poultry the disease is located chiefly on the head, the comb, wattle, margin of the nose, eyelids, and auditory meatus, though it may be met with elsewhere, as the abdomen; and in the turkey I have seen it on the legs.

In the College museum I have recently placed examples of the disease in the turkey and fowl.

The head of the first (a young bird, Fig 24) shows a series of molluscous tumours growing from the upper eyelid of the right side, the margins of the left nostril and left auditory meatus, and beneath the mandible; the growth in the last-named situation (the largest) measures 1·3 cm. in chief horizontal diameter, and ·6 cm. in height. They are all covered with a pale or darker brown crust of superficially necrosed tissue, in which tracts of molluscous cells similar to those in the main mass of the new growths are recognisable.

There is an important point in regard to the diagnosis of molluscum in birds, and it is that in certain stages the true nature of the disease may be entirely overlooked. The second specimen (Fig. 25) will illustrate the difficulty. It is the head of a fowl, on the comb and about the beak of which are a certain number of

FIG. 24.

The head of a young turkey, showing molluscous tumours growing from the upper eyelid and beneath the mandible. Of the latter a vertical section has been made. (Nat. size.)

FIG. 25.

The head of a fowl, showing a series of eminences covered with thick, dry, horn-like crusts, which represent mollusca in process of detachment after spontaneous necrosis. One of the crusts has been raised from the subjacent elevation, which consists only of granulation tissue. (Nat. size.)

eminences surmounted with thick, dry, horn-like crusts, and presenting, when the latter are raised, a series of small pits (feather follicles), into which there fit corresponding processes of the investing crust, throughout which microscopic section shows areas of dried molluscous cells; the flat elevation beneath consists solely of granulation tissue, and is evenly invested with a normal epidermis. Now the noteworthy point is that the crust in question comprises the whole of the molluscous lesion, which is being shed from the surface after having undergone spontaneous necrosis. Hence, were the crust ignored (and it readily separates in unembedded sections), the subjacent plaque of granulation tissue, covered as it is with a continuous and normal epidermis, might be attributed to an entirely different cause, and the disease itself grouped amongst the more obscure infective granulomata.

In the final stages of spontaneous cure the dead material is completely shed. This I have observed in the head of the pheasant already incidentally referred to. Upon the eyelids, around the external auditory meatus, and about the beak of this bird there are clusters of wart-like elevations which, as histological examination proves, consist solely of granulation tissue. On only a few are any crusts present, but these are diagnostic, although, without a comparison with indubitable molluscous lesions it might not be easy to establish their identity, since the texture is not only dry and necrosed, but extensively infiltrated with blood. In this crust appear areas of homogeneous coagulum; of the same, holding large numbers of red blood-corpuscles (nucleated) with faintly stained nuclei; areas of more recent hæmorrhage, the blood having found its way along fissures of the necrotic substance; others of connective tissue in a condition of coagulative necrosis; and lastly tracts of round and oval spaces (molluscous cells), or the same disparted by coagulum and reduced in size.

When this complex structure is compared with the more voluminous lesions on the head of the turkey it is easy to trace their identity, and in the latter the necrotic tissue is directly continuous with the deeper and perfectly typical molluscous structure.

No similar mode of spontaneous detachment has as yet been traced out in the human subject, and this for the reason that the lesion invariably affects the form of a definite tumour, whereas in birds it may be quite superficial, and on undergoing total necrosis will scale off from the subjacent corium.

The necrosis may be total, or it may involve only part of the thickness of such a lesion.

Such partial necrosis I have seen in the leg of a young turkey on the head of which there were more prominent molluscous tumours. As studied in vertical microscopic sections the lesion (a pale brown lenticular eminence about 4 mm. in horizontal diameter) was quite superficial, and involved the whole of the general epidermis for this extent; the thickened epidermis presented a series of discrete, unbranched, insignificant ingrowths, and although centrally one or two penetrated more deeply and dilated in the substance of the corium, there was nothing that could be called a "tumour." The whole of the thickened surface-epithelium over this area displayed the most typical molluscous changes, and these extended also to the more central of the cells of the ingrowths. The corium for some depth beneath was thickly infiltrated with leucocytes, which formed a zone moreover, across the lesion itself, dividing a superficial dry and necrosed flake from the deeper living part of the epithelial growth.

The necrosis of the surface or of the whole lesion is the explanation of the fawn or brown colour which avine mollusca frequently present. Should the entire thickness of the new growth die it is cleanly shed, a line of epidermis extending beneath it before the actual detachment takes place, as happens in the healing of an aseptic wound beneath a scab, or in the detachment of a deciduous leaf or of necrosed parenchyma in plants, though in these latter two cases there is no extension of epidermis from that around the necrosed part, the reparative tissue (cork) being produced by subdivision of the living cells simultaneously beneath the whole of the dead area.

Hence at a certain stage one finds only granulation tissue beneath the necrotic molluscous plaque.

I have described these various lesions in detail partly because avine molluscum has a certain interest of its own, but also because it will probably prove to be at times the source of the human disease, and its recognition in birds, therefore, becomes of some importance.

With regard to the two Bunting sparrows I was unable to discover if mollusca had been observed amongst those to whom the birds belonged, but the possible intercommunicability of the disease between the human subject and poultry is a subject well worthy

of the future attention of clinicians. Mr. Pernet ('Brit. Journ. of Dermatology,' vol. ix, April, 1897, p. 173) cites a case of molluscum contagiosum of the eyelids recorded by Dr. Salzer ('Münch. Med. Wochenschrift,' September 8th, 1896) in a patient who was in the habit of feeding pigeons from her hand; the birds were affected with growths about the beak (these were not histologically examined), and Dr. Salzer suggests that infection may have been conveyed by the patient's hands from the birds' beaks to her eyelids. (A reference to this case is also given by Schneidemühl, 'Die Protozoen als Krankheitserreger des Menschen und der Hausthiere,' p. 186, 1898.)

Mr. Jonathan Hutchinson ('Clinical Journal,' March 13th, 1895) has recounted a case in which molluscum was conveyed to the human subject from a dog. It concerned a young woman in whom mollusca had been present about two months over the chest and shoulders. The patient herself suggested the source of infection by inquiring if it possibly arose from a dog on which similar tumours had been present for a considerably longer period. The tumours on the dog were scattered in small numbers over the back and sides, some of them being as large as small peas; those excised exhibited microscopically the typical molluscous bodies. This case is unique as being the first in which this disease has been demonstrated in any of the lower mammals, and has escaped the notice of Schneidemühl ('Lehrbuch de Vergleichenden Path. und Therapie des Menschen und der Hausthiere,' 1896), who cites the affection as having been observed only in man and birds.

Whatever the nature of the contagium, the best histological classification of Molluscum contagiosum is undoubtedly that of Virchow; it is an epithelial neoplasm, and none the less a tumour because it is transmissible by contagion. Certain papillomata of the skin exhibit the same phenomenon, to say nothing of such sarcomata as those referred to and recorded in the last volume of the Society's 'Transactions,' p. 310, by Mr. Bellingham Smith and Dr. J. W. Washbourn.

And lastly, with respect to the statement that the molluscous element is an intra-cellular protozoon, the same demand must be made here as in all other similar cases of doubt; Koch's second postulate must be fulfilled before such statements can have a scientific value; the protozoon must be grown as a pure culture outside the body. Among the few attempts in this direction are the com-

paratively simple ones made by Mr. Ballance and myself, and these which are recorded in the 'Proceedings of the Royal Society,' vol. lviii, terminated negatively. As damp sand and pond water are the natural habitats of the common amœba, and as psorospermia flourish so widely in the fresh water of ponds, lakes, and rivers, wet sand was the medium selected for the experiments.

Silver sand, from which the finest part had been removed by sifting, was baked in a shallow thin iron dish over a large ring Bunsen for an hour. It was then transferred to capsules 3½ inches diameter, 1¾ deep, previously baked for an hour at 150° C. in the hot-air steriliser. The capsules so charged were then baked for another hour at 150° C.; on removal from the steriliser the sand was heaped up on one side by shaking the capsule, so that when water was afterwards added part of the sand was submerged, whilst part, though wet, remained above the water level. The object of this proceeding was to obtain a littoral, in order that better aëration might be ensured for any protozoa which might perchance develop. The water used was distilled into a sterilised flask, and was subsequently boiled for from four to five hours to render it absolutely sterile. The mollusca, freshly excised from the living subject, were subdivided with sterile knives, and transferred to the capsules, the pieces being pressed into the sand just below the level of the fluid. The capsules thus prepared and inoculated were placed within a sterilised double dish; the cover of the dish was raised for a short distance by means of blocks of wood which had been soaked in solution of corrosive sublimate, the height being such as to allow free entrance of air without exposing the mouth of the lower dish. The double dish was finally placed upon a sheet of glass beneath a capacious shade, both of which had been cleansed with sublimate solution. The covers of the capsules were removed as they were placed within the double dish. All the experiments were conducted in a private laboratory continuously heated. For the microscopical examination a glass rod and slide were sterilised in the flame, and allowed to cool. The shade was removed, and the upper dish raised sufficiently to allow of the passage of the rod to the capsule. A little sand was then taken from three or four places along the littoral, or from the neighbourhood of the tissue, and transferred to the slide. The sand so removed was gently stroked with the rod on the slide until displaced from one end of the latter to the other; the slide was

finally inclined so that enough fluid left the sand to make a microscopic preparation with the aid of a cover-glass.

The examination was made with $\frac{1}{12}$ apochromatic oil immersion, Zeiss, oculars 4 and 8. Occasionally a few drops of beef peptone broth were added to the capsule, and as the water became low from evaporation more was supplied. In all the capsules bacteria developed, a result desired, inasmuch as a pabulum for any protozoa that might develop was thus furnished. Many examinations of the sand were made at intervals for considerable periods, but no evidences of protozoic life were ever encountered.

April 5th, 1898.

INDEX.

PAGE

ABBOTT (F. C.), congenital abnormality of sternum and diaphragm; protrusion of heart in epigastric region 57
ABSCESS, hepatic (H. D. Rolleston) 106
ACROMEGALY (P. Furnivall) 204
„ (J. B. Neal) 224
„ acute (H. D. Rolleston) 237
„ and hypertrophy of the pituitary body and thyroid; changes in bone marrow (W. Hunter) 246
„ further notes on a case of (N. Dalton) 242
„ report upon a case of (S. G. Shattock) 228
ADENO-CHONDROMA of submaxillary gland (H. J. Curtis) . . 85
ADENOMA of kidney (S. Boyd) 175
„ — cystic (H. Littlewood) 175
„ — papillary (F. P. Weber) 176
ADRENAL, tumour of (C. F. Beadles) 260
ADRENALS, hæmorrhage into (F. W. Andrewes) . . . 259
„ — (F. E. Batten) 258
„ — (A. E. Garrod and J. H. Drysdale) 257
„ — in infants (G. F. Still) 252
„ sarcoma of, in an infant (G. N. Pitt) 143
„ tumour of (C. F. Beadles) 260
ANÆMIC INFARCT in lung (L. Freyberger) 27
„ histology of (L. Freyberger) 29
ANDREWES (F. W.), bacteriology of a glanders nodule . . . 22
„ hæmorrhage into supra-renal capsule 259
ANEURYSM, aortic, external rupture of (W. L. Dickinson) . . 48
„ circumscribed traumatic, of innominate artery (G. Heaton) . . 54
„ of ascending aorta, external rupture (L. Freyberger) . . 51
ANOMALOUS THORACIC VEINS (L. Freyberger) 35
„ truncus brachiocephalicus (L. Freyberger) 44
„ fins in fish (C. G. Seligmann) 388, 390
ANTIDOTAL PROPERTIES of normal tissue emulsions (W. Myers) . 368
ANTRUM, empyema of, in a child (D'Arcy Power) 200
AORTA, external rupture of aneurysm of ascending portion of (L. Freyberger) 51
„ perforated by carcinoma of œsophagus (A. E. Garrod) . . 92

PAGE

AORTIC ANEURYSM which ruptured externally (W. L. Dickinson) . 48
„ incompetence (L. Freyberger) 44
„ — due to dilatation of the orifice (G. N. Pitt) . . . 46
„ orifice, calcification of (F. P. Weber) 41

APPENDAGES, uterine, tumours of (H. M. Fletcher) . . . 190

APPENDIX VERMIFORMIS, cystic dilatation of (A. G. R. Foulerton) . 110
„ intussusception of (H. F. Waterhouse) 108
„ perforation of, by pin (H. D. Rolleston) 106

ATROPHY of kidney, experimental (J. R. Bradford) . . . 169

BACILLI of leprosy, distribution of, in the tissues (P. Bergengrün, communicated by A. A. Kanthack) 336

BACILLUS MALLEI, fat globules in (S. G. Shattock) . . . 333
„ pleomorphism of the colon (H. C. Haslam) . . . 345

BACTERIOLOGY . . . . . 313—351
„ of a glanders nodule (F. W. Andrewes) 22

BATTEN (F. E.), hæmorrhage into supra-renal capsule . . . 258

BEADLES (C. F.), carcinomatous stricture of sigmoid flexure . . 119
„ hæmatoma of dura mater 1
„ laminated fibrous nodules on pleura 13
„ myxœdema, a report on three fatal cases, one associated with trichinosis 262
„ perforating ulcerative colitis in a lunatic . . . 112
„ primary carcinoma of kidney 179
„ primary carcinoma of the liver associated with a gall-stone . . 144
„ tumour of supra-renal capsule 260

BERGENGRÜN (P.) (communicated by Prof. Kanthack), the distribution of leprosy bacilli and the histogenesis of giant-cells in the leprous larynx 336

BERRY (J.), nose and lung from a case of glanders . . . 20

BILHARZIA HÆMATOBIA, on the hatching of (C. G. Seligmann) . 386

BIRDS, molluscum contagiosum in 393, 394

BLADDER, malformation of (A. Voelcker) 168

BLOOD, action of cobra poison on (J. W. W. Stephens and W. Myers) . 352

BOKENHAM (T. J.), serum-therapy of streptococcic infection . . 378
„ — of typhoid fever 373

BOND (C. H.), *post-mortem* emphysema of the liver . . . 121

BONE MARROW, changes in a case of acromegaly (W. Hunter) . 249

BOWES (T. A.) and WHITE (C. P.), intestinal obstruction due to induration of the great omentum 118

BOYD (S.), adenoma of kidney 175

BRADFORD (J. R.), experimental atrophy of the kidney . . 169
„ hæmatocele of a hydronephrotic kidney 171

BRAIN, three consecutive hæmorrhages into (L. Freyberger) . . 8

BREAST, colloid carcinoma of (C. E. M. Kelly and W. d'E. Emery) . 303
„ duct carcinoma of (C. E. M. Kelly and W. d'E. Emery) . . 303

BRONCHIAL GLAND, fatal ulceration of, into bronchus (A. Voelcker) . 22

BUNTING SPARROWS, molluscum contagiosum in two mated (S. G. Shattock) 394

PAGE

CÆCUM, cyst of (C. A. Morton) 111

CALCIFICATION of aortic and mitral orifices in the heart (F. P. Weber) 41
„ of pericardium following suppurative pericarditis (J. Calvert and T. S. Pigg) 31

CALCULI, biliary, associated with primary carcinoma (C. F. Beadles) . 144
„ — spontaneous fracture of (J. Calvert) 139
„ — — — (H. D. Rolleston) 135
„ intra-hepatic, in diabetes (H. D. Rolleston) . . . 133
„ renal impacted (L. Freyberger) 173
„ salivary (W. G. Spencer) 85

CALCULOUS DISEASE of the submaxillary salivary gland (W. G. Spencer) 85

CALVERT (J.), spontaneous fracture of gall-stones . . . 139
„ and PIGG (T. S.), a case of melanotic sarcoma . . . 297
„ — calcification of pericardium following suppurative pericarditis . 31

CANCER, primary, of kidney (C. F. Beadles) . . . 179

CARCINOMA of breast, colloid (C. E. Kelly and W. d'E. Emery) . 303
„ of heart, metastatic deposits (A. Voelcker) . . . 33
„ of liver associated with gall-stone (C. F. Beadles) . . . 144
„ of œsophagus (A. E. Garrod) 92
„ of pylorus (A. Voelcker) 100
„ of sigmoid flexure (C. F. Beadles) 119
„ of upper jaw (W. G. Spencer) 312
„ primary, of kidney (C. F. Beadles) 179

CARWARDINE (T.), pendulous hydatid cyst of liver . . . 130

CEREBRAL HÆMORRHAGES, three consecutive (L. Freyberger) . 3

CHICKEN, molluscum contagiosum in Wyandotte (T. C. Fox) . . 393

CHILD, cirrhosis of liver in (F. P. Weber) 126
„ empyema of antrum in (D'Arcy Power) 200
„ hæmorrhage into supra-renal capsules of . . 252—261
„ œsophagitis in (T. D. Lister) 88
„ ovarian cyst removed from (D'Arcy Power) . . . 186
„ sarcoma of liver and supra-renal capsule (G. N. Pitt) . . 143

CIRCULATION, diseases of the organs of . . . 31—59

CIRRHOSIS, early interlobular and suppurative pylephlebitis (F. P. Weber) 128
„ of liver in a child (F. P. Weber) 126

CLAVICLE, sarcoma of (H. Littlewood) 202

COBRA POISON, action of, on the blood (J. W. W. Stephens and W. Myers) 352
„ effect of normal tissue emulsions upon (W. Myers) . . 368

COLITIS, perforating ulcerative, in a lunatic (C. F. Beadles) . . 112
„ ulcerative (A. E. Voelcker) 114

COLLOID CARCINOMA of breast (C. E. M. Kelly and W. d'E. Emery) . 303

COLON, tumour of (R. Crawfurd) 115
„ perforation of (C. D. Green) 95

COLON BACILLUS, pleomorphism of (H. C. Haslam) . . . 345
„ — grown on glucose (H. C. Haslam) 351

CONGENITAL ABNORMALITY of sternum and diaphragm (F. C. Abbott) 57
„ cystic liver with cystic kidney (G. F. Still) . . . 155
„ fistula of tongue (P. Furnivall) 64
„ round-celled sarcoma of the liver (G. Heaton) . . . 140
„ ventral hernia at the umbilicus (W. G. Spencer) . . . 120

PAGE

CONTRACTED STOMACH (G. B. Hunt) 95

CRAWFURD (R.), heart with tumour of the pulmonary valves . . 37
„ tumour of ascending colon (intussusception) . . . 115

CURTIS (H. J.), adeno-chondroma of the right submaxillary gland . 85
„ lipoma of ischio-rectal fossa 309

CYST of cæcum (C. A. Morton) 111
„ of kidney (A. F. Voelcker) 168
„ of ovary (G. B. James) 189
„ — (D'Arcy Power) 186
„ papilliferous, of sudoriparous gland (H. B. Robinson) . . 290
„ perigastric (R. G. Hebb) 94
„ pericœsophageal (R. G. Hebb) 88
„ retro-peritoneal (C. B. Lockwood) 182

CYSTIC ADENOMA of kidney (H. Littlewood) . . . 175
„ disease of the kidneys and liver (R. Johnson) . . . 165
„ liver with cystic kidney (G. F. Still) 155

DALTON (N.), further notes on a case of acromegaly . . . 242

DERMOID CYST (H. D. Rolleston) 292

DIABETES, chronic pancreatitis in (H. D. Rolleston) . . . 150
„ intra-hepatic calculi in (H. D. Rolleston) . . . 133

DIAPHRAGM, congenital abnormality of (F. C. Abbott) . . 57

DICKINSON (L.), an aortic aneurysm which ruptured externally . 48

DIGESTION, diseases of the organs of . . . . 60—151

DIPHTHERIA BACILLI, effect of sewer air on (S. G. Shattock) . 328

DOUBLE PYONEPHROSIS (L. Freyberger) 173

DRYSDALE (J. H.) and GARROD (A. E.), hæmorrhage into supra-renal capsules 257

DUCT PAPILLOMA of breast (C. E. M. Kelly and W. d'E. Emery) . 303

DUCTLESS GLANDS, diseases of . . . . . 204—289

DURA MATER, hæmatoma of (C. F. Beadles) 1

EMERY (W. d'E.) and KELLY (C. E. M.), colloid carcinoma of the breast . 303

EMPHYSEMA, *post-mortem*, of liver (C. H. Bond) . . . 121

EMPYEMA of antrum in a child (D'Arcy Power) . . . 200
„ simulated by primary sarcoma of lung (S. H. Habershon) . . 17

ENTERIC FEVER, serum-therapy of (T. J. Bokenham) . . 373

ENTERITIS, ulcerative (C. P. White) 100

EPITHELIOMA of scapula (H. Littlewood) 202

ETHER, death after, specimen of heart from (R. G. Hebb) . . 33

EXPERIMENTAL ATROPHY of the kidney (J. R. Bradford) . . 169

FAT NECROSIS (H. D. Rolleston) 145

FATTY DEGENERATION of kidneys (F. P. Weber) . . . 152
„ infiltration of heart (R. G. Hebb) 33

FIBROMA of nipple (C. D. Green) 308

PAGE

FIBROMATA of tunica vaginalis (H. Littlewood) . . . 182
FIBRO-SARCOMA of hand (H. Littlewood) 310
FIBROUS NODULES on pleura (C. F. Beadles) . . . 13
FISH, malformations in (C. G. Seligmann) 390
„ supernumerary fin in (C. G. Seligmann) 388
FISTULA of tongue (P. Furnivall) 64
Fletcher (H. M.), tumour of the spinal cord . . . 6
„ tumours of the uterus and appendages 190
„ uterus unicorporeus et vagina duplex 190
Foulerton (A. G. R.), cystic dilatation of the vermiform appendix . 110
FOWL, molluscum contagiosum in (T. C. Fox) . . . 393
Fox (J. T.), Meckel's diverticulum and obstruction of the bowels . 103
Fox (T. C.), molluscum contagiosum in a chicken . . . 393
FRACTURE of scapula, ununited (C. P. White) . . . 199
FRACTURES, multiple spontaneous (C. Spurrell) . . . 192
„ spontaneous (E. Willett) 195
FRAGILITAS OSSIUM (L. G. Guthrie) 199
Freyberger (L.), a case of patent cardiac septum with congenital stenosis of the pulmonary artery and anomalous distribution of the thoracic veins 35
„ anæmic infarct in the lung 27
„ aneurysm of ascending aorta; external rupture . . . 51
„ anomalous truncus brachiocephalicus associated with aortic incompetence and symptoms simulating aneurysm . . . 44
„ brain with three consecutive hæmorrhages . . . 3
„ double pyonephrosis caused by impaction of renal calculi . . 173
„ heart with musculus chordæ tendineæ 5
„ — with musculus papillaris 5
Furnivall (P.), acromegaly, with an analysis of forty-nine cases . 204
„ fistula in the middle line of the anterior part of the tongue, probably congenital 64
„ symmetrical rodent ulcers of the face 299

GALL-STONES associated with primary carcinoma of liver (C. F. Beadles) 144
„ spontaneous fracture of, in gall-bladder (H. D. Rolleston) . . 135
„ — — of (J. Calvert) 139
Garrod (A. E.), carcinoma of the œsophagus proving fatal by perforation of aorta 92
„ hæmorrhage into supra-renal capsule in children . . . 257
GENITO-URINARY ORGANS, diseases of . . . 152—191
GIANT-CELLS, the histogenesis of, in the leprous larynx (Prof. Bergengrün) 336
GLAND, ulceration of bronchial, into bronchus (A. Voelcker) . . 22
„ — tubercular into trachea (C. Ogle) 26
GLANDERS bacilli, fat globules in (S. G. Shattock) . . . 333
„ infectivity of white mice to (S. G. Shattock) . . . 333
„ nodule, bacteriology of (F. W. Andrewes) . . . 22
„ nose and lung from a case of (J. Berry) 20
„ white mice not immune to (S. G. Shattock) . . . 333

PAGE

GLIO-SARCOMA of spinal cord (H. M. Fletcher) . . . 6

GREEN (C. D.), lobulated fibroma of nipple 308
„ stomach showing double perforating ulcer and a perforation of the colon 95

GROIN, symmetrical rodent ulcers in (T. S. Pigg) . . . 300

GUMMA of the pituitary body (W. Hunter) 249

GUTHRIE (L. G.), fragilitas ossium 199

HABERSHON (S. H.), primary myxo-sarcoma of the pleura . . 15
„ primary sarcoma of left lung simulating an empyema . . 17

HÆMATOCELE of hydronephrotic kidney (J. R. Bradford) . . 171

HÆMATOMA of dura mater (C. F. Beadles) . . . 1

HÆMORRHAGE into supra-renal capsules . . . 252—259
„ — (F. W. Andrewes) 259
„ — (F. E. Batten) 258
„ — (A. E. Garrod and J. H. Drysdale) 257
„ — in infants (G. F. Still) 252

HÆMORRHAGES, three consecutive, in same brain (L. Freyberger) . 3

HÆMORRHAGIC ŒSOPHAGITIS (T. D. Lister) . . . 88

HAND, fibro-sarcoma of (H. Littlewood) 310
„ sarcoma of (H. Littlewood) 311

HASLAM (H. C.), colon bacillus grown on glucose . . . 351
„ pleomorphism of colon bacillus 345

HEART, aortic incompetence (L. Freyberger) . . . 44
„ — (G. N. Pitt) 46
„ fatty infiltration of (R. G. Hebb) 33
„ — from a case of death after ether administration (R. G. Hebb) . 33
„ musculus papillaris in (L. Freyberger) 5
„ protrusion of, in epigastric region (F. C. Abbott) . . . 57
„ secondary carcinoma of (A. F. Voelcker) . . . 33
„ with extreme calcification of aortic and mitral orifices (F. P. Weber) . 41
„ with patent septa (L. Freyberger) 35
„ with tumour of pulmonary valves (R. Crawfurd) . . . 37

HEATON (G.), circumscribed traumatic aneurysm of innominate artery . 54
„ congenital round-celled sarcoma of the liver . . . 140

HEBB (R. G.), cancerous pericarditis secondary to malignant stricture of œsophagus 32
„ fatty infiltration of heart, death after ether anæsthesia . . 33
„ perigastric cyst 94
„ peri-œsophageal cyst 88

HEPATIC ABSCESS (H. D. Rolleston) 106

HERNIA, ventral, at umbilicus (W. G. Spencer) . . . 120

HUNT (G. B.), extreme contraction of the stomach, with some remarks on the pathology of this condition 95

HUNTER (W.), acromegaly with hypertrophy of the pituitary body and thyroid; changes in bone marrow 246
„ gumma of the pituitary body 249

HYDATID, pendulous, of liver (T. Carwardine) . . . 130

HYDRONEPHROTIC KIDNEY, hæmatocele of (J. R. Bradford) . 171

PAGE

IMMUNITY, contribution to the study of passive (J. W. W. Stephens and W. Myers) 352
„ of white mice to glanders (S. G. Shattock) . . . 333

INDIAN PLAGUE, lymphatic gland and spleen from a case of (T. S. Pigg) 351

INFANTS, bacteriology of simple basic meningitis in (G. F. Still) . 313

INFARCT, anæmic, in lung (L. Freyberger) . . . 27
„ in lung, histology of (L. Freyberger) 29

INNOMINATE ARTERY, circumscribed traumatic aneurysm of (G. Heaton) 54

INTESTINAL OBSTRUCTION and Meckel's diverticulum (J. T. Fox) . 103
„ due to induration of the great omentum (T. A. Bowes and C. P. White) 118
„ following cicatricial contraction of tuberculous ulcers (C. P. White) . 102

INTESTINE, carcinoma of (C. F. Beadles) 119

INTRA-HEPATIC CALCULI in diabetes (H. D. Rolleston) . . 133

INTUSSUSCEPTION of the colon (R. Crawfurd) . . . 117
„ of vermiform appendix (H. F. Waterhouse) . . . 108

ISCHIO-RECTAL FOSSA, lipoma of (H. J. Curtis) . . . 309

JAMES (G. B.), pyosalpinx and cyst of ovary . . . 189
„ sarcoma of the œsophagus with secondary deposit in tongue . 91

JAW, carcinoma of upper (W. G. Spencer) 312

JOHNSON (R.), cystic disease of kidneys and liver . . . 165

JONES (Robert), macrodactyly due to diffuse lipoma . . . 203

KANTHACK (Prof.), for P. BERGENGRÜN, on leprosy . . . 336

KELLY (C. E. M.) and EMERY (W. d'E.), colloid carcinoma of the breast . 303

KIDD (P.) and HABERSHON (S. H.), primary myxo-sarcoma of the pleura . 15

KIDNEY, adenoma of (S. Boyd) 175
„ — (H. Littlewood) 175
„ — (F. P. Weber) 176
„ cystic adenoma of (H. Littlewood) 175
„ — disease of, with cystic liver (R. Johnson) . . . 165
„ — with cystic liver (G. F. Still) 155
„ cysts in pelvis (A. F. Voelcker) 168
„ double pyonephrosis of (L. Freyberger) 173
„ experimental atrophy of (J. R. Bradford) . . . 169
„ fatty degeneration of (F. P. Weber) 152
„ hæmatocele of a hydronephrotic (J. R. Bradford) . . . 171
„ lympho-sarcoma of pelvis of (C. P. White) . . . 178
„ papillary adenoma of (F. P. Weber) 176
„ primary carcinoma of (C. F. Beadles) 179
„ speckled (F. P. Weber) 152

LARYNX, the histogenesis of giant-cells in leprous lesions of (Prof. Bergengrün) 336

LATENT TUBERCULOSIS of tonsil (H. Walsham) . . . 67

LEPROSY, observations on the distribution in the tissues of the bacilli and on the histogenesis of giant-cells in leprous lesions of the larynx (Prof. Bergengrün) 336

LINITIS, case of (G. B. Hunt) 97

PAGE

LIPOMA leading to macrodactyly (R. Jones) . . . 203
„ nasi (Edgar Willett) 290
„ of ischio-rectal fossa (H. J. Curtis) 309

LIPOMATA (H. Littlewood) 310

LISTER (T. D.), two specimens of œsophagitis in infants . . 88

LITTLEWOOD (H.), a case of sarcoma of the tongue . . . 60
„ cystic adenoma of kidney 175
„ epithelioma of scapula 202
„ fibro-sarcoma of hand 310
„ lipomata 310
„ multiple fibromata of tunica vaginalis 182
„ sarcoma of clavicle 202
„ — of hand 311
„ undescended testicle with twisting of cord . . . 181

LIVER, cirrhosis of, in a child (F. P. Weber) . . . 126
„ congenital cystic, with cystic kidney (G. F. Still) . . . 155
„ — sarcoma of (G. Heaton) 140
„ cystic disease of, with cystic liver (R. Johnson) . . . 165
„ intra-hepatic calculi in diabetes (H. D. Rolleston) . . . 133
„ pendulous hydatid cyst of liver (T. Carwardine) . . . 130
„ post-mortem emphysema of (C. H. Bond) . . . 121
„ primary carcinoma of (C. F. Beadles) 144
„ sarcoma of (G. N. Pitt) 143
„ showing early interlobular cirrhosis and suppurative pylephlebitis (F. P. Weber) 128
„ spontaneous fracture of a gall-stone in the gall-bladder (H. D. Rolleston) 135
„ — — of gall-stones (James Calvert) 139

LOCKWOOD (C. B.), retro-peritoneal cyst 182

LOCOMOTION, diseases of the organs of . . . 192—203

LOWER ANIMALS, diseases of . . . . 386—401

LUNATIC, myxœdema in (C. F. Beadles) 262
„ perforating ulcerative colitis in (C. F. Beadles) . . . 112
„ post-mortem emphysema of the liver in the body of (C. H. Bond) . 121

LUNG, anæmic infarct in (L. Freyberger) 27
„ and nose from a case of glanders (J. Berry) . . . 20
„ histology of anæmic infarct in (L. Freyberger) . . . 29
„ primary sarcoma of, simulating an empyema (S. H. Habershon) . 17
„ ulceration of bronchial gland into (A. Voelcker) . . . 22

LYMPHO-SARCOMA of pelvis of kidney (C. P. White) . . 178

MACRODACTYLY due to diffuse lipoma (R. Jones) . . . 203

MALFORMATIONS in fish (C. G. Seligmann) . . 388—393

MALLEI BACILLI, fat globules in (S. G. Shattock) . . . 333

MAXILLA, carcinoma of superior (W. G. Spencer) . . . 312

MECKEL'S DIVERTICULUM (J. T. Fox) 103
„ with obstruction of the bowels (J. T. Fox) . . . 103

MELANOTIC SARCOMA (J. Calvert and T. S. Pigg) . . . 297

MENINGITIS, bacteriology of, in infants (G. F. Still) . . 313

METASTATIC CARCINOMA of heart (A. F. Voelcker) . . 33

PAGE

MICE, white, not immune to glanders (S. G. Shattock) . . 333
MISCELLANEOUS COMMUNICATIONS . . . 352—385
MITRAL ORIFICE, calcification of (F. P. Weber) . . . 41
MOLLUSCUM CONTAGIOSUM in a Wyandotte chicken (T. C. Fox) . 393
„ in mated bunting sparrows (S. G. Shattock) . . . 394
MORBID GROWTHS . . . . . 297—312
MORBID GROWTHS COMMITTEE, report on Dr. Crawfurd's tumour of colon 117
„ — on Dr. R. Crawfurd's tumour of the pulmonary valve . . 41
„ — on Mr. Kelly and Dr. Emery's case of carcinoma of breast . 307
„ — on Mr. Littlewood's sarcoma of the tongue . . . 63
„ — on Mr. Wellington's specimen of spina bifida . . . 10
MORTON (C. A.), cyst removed from the inside of the cæcum . . 111
MUSCULUS chordæ tendineæ (L. Freyberger) . . . 5
„ papillaris in heart (L. Freyberger) 5
MYCETOMA PAPILLOMATOSUM (S. G. Shattock) . . . 293
MYERS (W.), antidotal properties of normal tissue emulsions . . 368
„ and STEPHENS (J. W. W.), the action of cobra poison on the blood . 352
MYXŒDEMA, a report on three fatal cases (C. F. Beadles) . . 262
MYXO-SARCOMA, primary, of pleura (P. Kidd and S. H. Habershon) . 15

NEAL (J. B.) and SMYTH (E. J.), the pituitary body from a case of acromegaly 224
NEPHRITIS, chronic interstitial, with cysts (A. F. Voelcker) . . 168
NERVES from a case of chronic traumatic neuritis (W. G. Spencer) . 10
NERVOUS SYSTEM, diseases of . . . . . 1—12
NEURITIS, specimen of chronic traumatic (W. G. Spencer) . . 10
NIPPLE, lobulated fibroma of (C. D. Green) 308
NOSE, lipoma of (E. Willett) 290
NOSE AND LUNG from a case of glanders (J. Berry) . . . 20

OBSTRUCTION, intestinal, due to induration of the great omentum (T. A. Bowes and C. P. White) 118
„ — due to a Meckel's diverticulum (J. T. Fox) . . . 103
„ — following cicatricial contraction of tuberculous ulcers (C. P. White) 102
ŒSOPHAGITIS, acute hæmorrhagic (T. D. Lister) . . . 88
ŒSOPHAGUS, cancer of, causing aortic perforation (A. E. Garrod) . 92
„ — followed by cancerous pericarditis (R. G. Hebb) . . 32
„ columnar-celled carcinoma of (C. P. White) . . . 93
„ inflammation of (T. D. Lister) 88
„ sarcoma of (G. B. James) 91
„ thrush of (T. D. Lister) 90
OGLE (C.), ulceration of tubercular gland into trachea with rapidly fatal result 26
OMENTUM, induration of, leading to intestinal obstruction (T. A. Bowes and C. P. White) 118

PAGE

OVARIAN CYST from a child aged four months (D'Arcy Power) . . 186
OVARY, cyst of, with a pyosalpinx (G. B. James) . . . 189

PANCREATITIS causing localised peritoneal effusion (H. D. Rolleston) . 145
„ chronic, in diabetes (H. D. Rolleston) 150
PAPILLARY ADENOMA of kidney (F. P. Weber) . . . 176
PAPILLIFEROUS CYST of sudoriparous gland (H. B. Robinson) . . 290
PERI-APPENDICULAR INFLAMMATION (H. D. Rolleston) . . 106
PERICARDITIS, cancerous, secondary to malignant stricture of the œsophagus (R. G. Hebb) 32
„ suppurative, followed by calcification of pericardium (J. Calvert and T. S. Pigg) 31
PERICARDIUM, calcification of, following suppurative pericarditis (J. Calvert and T. S. Pigg) 31
PERIGASTRIC CYST (R. G. Hebb) 94
PERIŒSOPHAGEAL CYST (R. G. Hebb) 88
PERITONEUM, effusion into the lesser sac of (H. D. Rolleston) . . 145
PIGG (T. S.), inguinal glands and spleen from a case of Indian plague . 351
„ symmetrical rodent ulcers in groin 300
„ and CALVERT (J.), a case of melanotic sarcoma . . . 297
„ — calcification of the pericardium following suppurative pericarditis . 31
PIN perforating vermiform appendix (H. D. Rolleston) . . 106
PITT (G. N.), aortic incompetence due to dilatation of the orifice and not to disease of the valves 46
„ sarcoma of liver and supra-renal in a baby . . . 143
PITUITARY BODY, gumma of (W. Hunter) . . . 249
„ hypertrophy of, in acromegaly (W. Hunter) . . . 246
„ in acromegaly (P. Furnivall) 204
„ sarcoma of, leading to acromegaly (H. D. Rolleston) . . 237
PLAGUE, Indian, lymphatic glands and spleen from a case of (T. S. Pigg) 351
PLEOMORPHISM of colon bacillus (H. C. Haslam) . . . 345
PLEURA, laminated fibrous nodules on (C. F. Beadles) . . 13
„ primary myxo-sarcoma of (P. Kidd and S. H. Habershon) . . 15
POWER (D'ARCY), empyema of antrum in a child . . . 200
„ (for R. JONES), macrodactyly due to diffuse lipoma . . . 203
„ ovarian cyst from a child aged four months . . . 186
PRIMARY MYXO-SARCOMA of pleura (P. Kidd and S. H. Habershon) . 15
PRIMARY SARCOMA of lung simulating empyema (S. H. Habershon) . 17
PULMONARY ARTERY, congenital stenosis of (L. Freyberger) . . 35
PULMONARY VALVES, tumour of (R. Crawfurd) . . . 37
PYLEPHLEBITIS and early cirrhosis of liver (F. P. Weber) . . 128
PYLORUS, carcinoma of (A. Voelcker) 100
PYONEPHROSIS, double (L. Freyberger) 173
PYOSALPINX and cyst of ovary (G. B. James) . . . 189

PAGE

RENAL CALCULI causing pyonephrosis (L. Freyberger) . . . 173

REPORT OF MORBID GROWTHS COMMITTEE on Dr. Crawfurd's tumour of colon 117
„ on Dr. Crawfurd's tumour of pulmonary valve . . . 41
„ on Mr. Kelly and Dr. Emery's colloid cancer of breast . . 307
„ on H. Littlewood's sarcoma of the tongue . . . 63
„ on Mr. Wellington's case of spina bifida 10

RESPIRATION, diseases of the organs of . . . 13—30

ROBINSON (H. B.), papilliferous cyst of a sudoriparous gland from the axilla 290

RODENT ULCERS, near umbilicus (H. D. Rolleston) . . . 301
„ symmetrical, of face (P. Furnivall) 299
„ — of groin (T. S. Pigg) 300

ROLLESTON (H. D.), acute acromegaly due to sarcoma of pituitary body . 237
„ chronic pancreatitis in diabetes 150
„ large intra-hepatic calculi in diabetes 133
„ localised effusion in the lesser sac of the peritoneum due to pancreatitis 145
„ pin perforating the vermiform appendix; peri-appendicular inflammation; hepatic abscess 106
„ rodent ulcer near umbilicus 301
„ sebaceous material from a dermoid cyst 292
„ spontaneous fracture of a gall-stone in the gall-bladder . . 135

SALIVARY GLAND, adeno-chondroma of (H. J. Curtis) . . 85
„ calculous disease of submaxillary (W. G. Spencer) . . . 85

SARCOMA, melanotic (J. Calvert and T. S. Pigg) . . . 297
„ of clavicle (H. Littlewood) 202
„ of liver (G. Heaton) 140
„ — and supra-renal in a baby (G. N. Pitt) . . . 143
„ of pituitary body leading to acromegaly (H. D. Rolleston) . . 237
„ of the œsophagus with secondary deposit in tongue (G. B. James) . 91
„ of the pulmonary valve (R. Crawfurd) 37
„ of the tongue (H. Littlewood) 60
„ primary, of lung simulating an empyema (S. H. Habershon) . . 17

SCAPULA, epithelioma of (H. Littlewood) 202
„ ununited fracture of (C. P. White) 199

SELIGMANN (C. G.), malformations in fish 390
„ supernumerary dorsal fin in a trout 388
„ the hatching of *Bilharzia hæmatobia* 386

SERUM-THERAPY of streptococcic infections (T. J. Bokenham) . 378
„ of typhoid fever (T. J. Bokenham) 373

SEWER AIR, effect of, on diphtheria bacilli (S. G. Shattock) . . 328

SHATTOCK (S. G.), fat globules in *Bacillus mallei* and the infectibility of white mice, commonly stated to be immune . . . 333
„ histological report on a case of acromegaly . . . 227
„ molluscum contagiosum in mated bunting sparrows . . 394
„ mycetoma papillomatosum 293
„ pathological report upon a case of acromegaly . . . 228
„ sewer air and the toxicity of diphtheria bacilli . . . 328

SKIN, diseases of . . . . . 290—296

SNAKE POISON, action of, on the blood (J. W. W. Stephens and W. Myers) 352
„ effect of normal tissue emulsions upon (W. Myers) . . 368

PAGE

SPARROWS, molluscum contagiosum in two mated bunting (S. G. Shattock) 394
SPECKLED KIDNEYS (F. P. Weber) 152
SPENCER (W. G.), a case of chronic traumatic neuritis . . 10
„ calculous disease of the submaxillary salivary gland . . 85
„ carcinoma of upper jaw 312
„ congenital ventral hernia at the umbilicus . . . 120
SPERMATIC CORD, twisting of, with undescended testicle (H. Littlewood) 181
SPINA BIFIDA, an unusual form of (R. H. Wellington) . . 8
SPINAL CORD, glio-sarcoma of (H. M. Fletcher) . . . 6
„ tumour of (H. M. Fletcher) 6
SPLEEN from a case of Indian plague (T. S. Pigg) . . . 351
SPONTANEOUS FRACTURES (C. Spurrell) 191
„ (Edgar Willett) 195
„ of gall-stones (J. Calvert) 139
„ — (H. D. Rolleston) 135
SPURRELL (C.), multiple spontaneous fractures . . . 191
STEPHENS (J. W. W.) and MYERS (W.), the action of cobra poison on the blood 352
STERNUM, congenital abnormality of (F. C. Abbott) . . . 57
STILL (G. F.), congenital cystic liver with cystic kidney . . 155
„ hæmorrhage into the supra-renal capsules in infants . . 252
„ the bacteriology of simple posterior basic meningitis in infants . 313
STOMACH, extreme contraction of (G. B. Hunt) . . . 95
„ with double perforating ulcer (C. D. Green) . . . 95
STREPTOCOCCIC INFECTION, serum-therapy of (T. J. Bokenham) . 378
SUBMAXILLARY GLAND, adeno-chondroma of (H. J. Curtis) . . 85
„ calculous disease of (W. G. Spencer) 85
SUDORIPAROUS GLAND, papilliferous cyst of (H. B. Robinson) . 290
SUPERNUMERARY FIN in a trout (C. G. Seligmann) . . 388
SUPRA-RENAL CAPSULES, hæmorrhage into . . 252—259
„ — in infants (G. F. Still) 252
„ sarcoma of, in a baby (G. N. Pitt) 143
„ tumour of (C. F. Beadles) 260
SYMMETRICAL RODENT ULCERS in face (P. Furnivall) . . 299
„ in groin (T. S. Pigg) 300

TESTICLE, undescended, with twisting of cord (H. Littlewood) . . 181
THRUSH of œsophagus (T. D. Lister) 88
THYROID, hypertrophy of, in acromegaly (W. Hunter) . . 249
„ in myxœdema (C. F. Beadles) 262
TONGUE, congenital fistula of (P. Furnivall) . . . 64
„ sarcoma of (H. Littlewood) 60
„ secondary sarcoma of, primary growth in œsophagus (G. B. James) . 91
TONSIL, latent tuberculosis of (H. Walsham) . . . 67
TOXICITY of diphtheria bacilli, effect of sewer air on (S. G. Shattock) . 328
TRACHEA, fatal ulceration of tubercular gland into (C. Ogle) . . 26
TRAUMATIC ANEURYSM of innominate artery (G. Heaton) . . 54

PAGE

TRICHINOSIS associated with myxœdema (C. F. Beadles) . . 262
TRUNCUS BRACHIOCEPHALICUS, anomalous (L. Freyberger) . . 44
TUBERCULOSIS of tonsil (H. Walsham) 67
TUBERCULOUS ULCERS causing intestinal obstruction (C. P. White) . 102
TUMOUR of spinal cord (H. M. Fletcher) 6
TUNICA VAGINALIS, fibromata of (H. Littlewood) . . . 182
TYPHOID FEVER, serum-therapy of (T. J. Bokenham) . . 373

ULCERATION of bronchial gland into bronchus (A. Voelcker) . . 22
„ of tubercular gland into trachea (C. Ogle) . . . 26
ULCERATIVE ENTERITIS (C. P. White) 100
UMBILICUS, congenital ventral hernia at (W. G. Spencer) . . 120
„ rodent ulcer near (H. D. Rolleston) 301
URETER, double (A. F. Voelcker) 168
UTERUS bicornis (A. F. Voelcker) 189
„ tumours of (H. M. Fletcher) 190
„ unicorporeus et vagina duplex (H. M. Fletcher) . . . 190

VAGINA duplex et uterus unicorporeus (H. M. Fletcher) . . 190
VEINS, anomalous, distribution of thoracic (L. Freyberger) . . 35
VENTRAL HERNIA at umbilicus (W. G. Spencer) . . . 120
VERMIFORM APPENDIX, cystic dilatation of (A. G. R. Foulerton) . 110
„ intussusception of (H. F. Waterhouse) 108
„ perforated by pin (H. D. Rolleston) 106
VOELCKER (A. F.), carcinoma of the pylorus . . . 100
„ chronic interstitial nephritis with cysts 168
„ metastatic deposits of carcinoma in the heart . . . 33
„ ulceration of caseous bronchial gland into bronchus . . 22
„ ulcerative colitis 114
„ uterus bicornis 189

WALSHAM (H.), latent tuberculosis of tonsil 67
WATERHOUSE (H. F.), intussusception of vermiform appendix . . 108
WEBER (F. P.), cirrhosis of the liver in a child . . . 126
„ heart with extreme calcification of the aortic and mitral orifices from a case with exceptional physical signs 41
„ liver showing early interlobular type of cirrhosis from a case of suppurative pylephlebitis 128
„ papillary adenoma of kidney 176
WELLINGTON (R. H.), an unusual form of spina bifida . . 8
WHITE (C. P.), a case of columnar-celled carcinoma of the œsophagus . 93
„ a case of ulcerative enteritis with perforation . . . 100
„ intestinal obstruction following cicatricial contraction of tuberculous ulcers 102
„ lympho-sarcoma of pelvis of kidney 178

PAGE

WHITE (C. P.), *continued*—
„ ununited fracture of scapula 199
„ and BOWES (T. A.), intestinal obstruction due to induration of the great omentum 118

WHITE MICE, infectibility of, with glanders (S. G. Shattock) . . 333

WILLETT (E.), lipoma nasi 290
„ multiple spontaneous fractures 195

WOLFFIAN BODY, supposed cyst of (C. B. Lockwood) . . 182

PRINTED BY ADLARD AND SON, BARTHOLOMEW CLOSE, E.C.